

Case Report

Metastatic neck node: a straying journey to diagnosis

J. R. Galagali¹, Roohie Singh^{2*}

¹Base Hospital, Tejpur, Assam, India

²Department of ENT, Military Hospital, Hisar, Harayana, India

Received: 11 April 2018

Accepted: 24 May 2018

***Correspondence:**

Dr. Roohie Singh,

E-mail: roohiesingh@yahoo.in

Copyright: © the author(s), publisher and licensee Medip Academy. This is an open-access article distributed under the terms of the Creative Commons Attribution Non-Commercial License, which permits unrestricted non-commercial use, distribution, and reproduction in any medium, provided the original work is properly cited.

ABSTRACT

Squamous cell carcinoma of lung is most commonly associated with smoking. Its metastasis to contralateral neck node as the first presenting symptom is very rare. Tuberculosis (TB) and cancer of lung have causal relationship. There may also be coexistence of another neoplasm around the time of diagnosis of primary neoplasm. We present a case report of an 80 years old man who presented with a contralateral metastatic neck node. He was diagnosed to have coexistent lung cancer and pulmonary TB. In this journey towards diagnosis, the findings suggestive of tubercular larynx might have been a sequel of pulmonary TB.

Keywords: Bronchogenic, Coexistent, Metastatic, Tuberculosis

INTRODUCTION

Visceral tumours metastasis to extracranial region of head and neck are uncommon and usual primary sources are breast, colon and kidneys.¹ Lung Cancer and TB are two major public health problems. The co-existence of TB and cancer in the same organ has been also reported which causes a diagnostic dilemma.^{2,3} It is important to highlight the fact of co-existence of a second neoplasm at the same time or within six months period of primary lesion which is known as synchronous neoplasms. After this period they are considered as metachronous neoplasms.

CASE REPORT

An 80 years old man, a chronic smoker presented with right level 3 and 4 cervical lymphadenopathy since one and half months (Figure 1A). FNAC was suggestive of metastatic deposits of squamous cell carcinoma. This lead to clinical diagnosis of- metastatic neck disease (inv).

Fibre-optic nasopharyngolaryngoscopy was done which revealed a thickened nodular epiglottis with pale mucosa very much mimicking classical “Turban epiglottis” of Tuberculosis of larynx. Incidental small vallecular cyst was also found in Right vallecular region (Figure 1B). However, there was no undermined ulcers, mucosal hyperemia or interarytenoid mamillations. These findings led to D/Ds of (a) Metastatic neck disease - ? Supraglottic malignancy (b) Tuberculosis larynx.

There was history of low grades fever and weight loss. Cough was non-productive. Chest X-ray revealed a cavitary lesion in upper zone of left lung (Figure 2A). MRI Neck confirmed the findings of neck node examination and fiberoptic examination of larynx. It also showed a thick walled cavitary lesion in upper lobe of left lung. The patient underwent CT Chest that showed large cavitary lesion with thick wall in left upper lobe with no hilar or mediastinal lymphadenopathy which suggested possibility of left Bronchogenic carcinoma (Figure 2B and C).

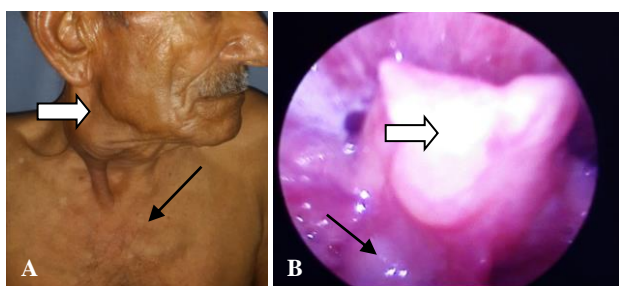


Figure 1: (A) Right cervical lymphadenopathy (white arrow) and left rib deformity (black arrow), (B) Endoscopic view of larynx with nodular thickened epiglottis (black arrow) and Incidental Right vallecular cyst (black arrow).

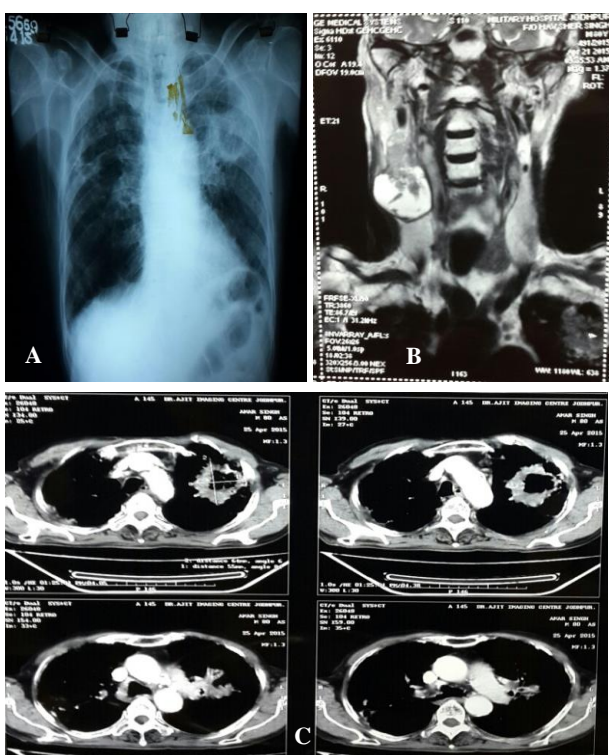


Figure 2: (A) CXR showing cavitary lesion in upper lobe of left lung; (B) MRI NECK showing right cervical metastatic neck node and cavitary lesion in upper lobe of left lung; (C) CT chest showing cavitary lesion with thick irregular wall in upper lobe of left lung suspected of bronchogenic carcinoma.

The patient was then re-examined to find the chronic signs of bronchogenic carcinoma like clubbing (in both upper and lower limbs) (Figure 3), a small anterior second and third rib deformity of on left side (Figure 1A) and left upper zone wheeze in chest, which were very much present.

However, the possible co-existence of lung cancer and malignancy larynx and/or pulmonary tuberculosis with laryngeal sequelae could not be overlooked. PET (Positron emission tomography) was done. It showed intense tracer concentration in the mass lesion in upper lobe of left lung

and supraglottic larynx as well. The patient was taken for laryngotracheobronchoscopy and biopsy. Bronchoalveolar lavage was taken for smear and cytology. Smear was positive for acid fast bacilli. Cytology was suggestive of well differentiated squamous cell carcinoma. Biopsy from epiglottis revealed Langerhan's cells with carcinoma, necrosis and no atypia. Hence, the final diagnosis was "coexistent left bronchogenic carcinoma and pulmonary tuberculosis with laryngeal tuberculosis with contralateral neck node metastasis". Unfortunately, during the treatment planning, the patient became hemiplegic and MRI brain suggested metastasis in brain parenchyma. Eventually, the patient had a cardio-respiratory arrest and died.

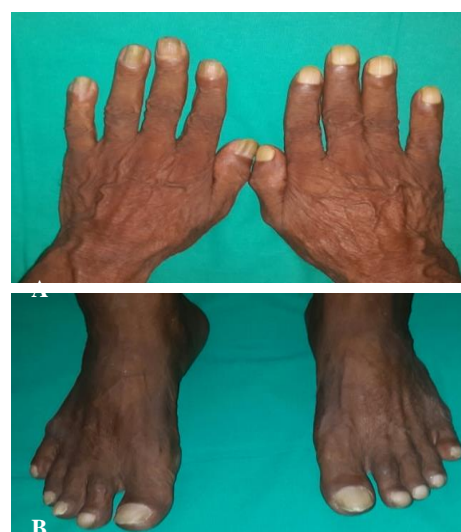

Figure 3 (A and B): Clubbing in upper and lower limbs.

DISCUSSION

It is very unusual to have contralateral metastatic neck node (other than supraclavicular lymph node) as the first presenting symptom of lung cancer. Lung cancer usually metastasizes to mediastinal lymph nodes.⁴

Slaughter developed the theory of field cancerization in tumours of head and neck in 1946 where multiple tumours can originate independently in an area of epithelium pre-conditioned to cancer development by long-term exposure to carcinogens.⁵ Patients with head and neck cancers have high (2-3%) incidence of second primary lesions. In our case there was possibility of coexistence of supraglottic and lung malignancy.

Apart from these, there was coexistent pulmonary TB. Reactivation of a latent TB can occur because of immunosuppression due to cancer. Or else, scarring due to chronic TB can result in metaplasia.

In such cases when the clinicians land up in diagnostic dilemma, to his rescue comes advanced radiological and invasive surgical investigations.

In our case, since there was no cough or expectoration, sputum AFB was of no use. ELISA for TB cannot be recommended for distinguishing it from Lung cancer.⁶ PET is useful in search for an unknown primary in patients who present with malignant neck disease with extremely variable reports ranging from 14-50%.^{7,8}

Bronchoscopy appeared to be most useful test at that time. It allowed collection and examination of lavage fluid for smear and cytology. It also allowed visualisation, location and histopathological confirmation of the lung tumour. Laryngeal biopsy was also taken at the same time.

CONCLUSION

Due to high prevalence of tuberculosis in India and radiological similarities of lung cancer and tuberculosis, attempts are needed to minimise the unacceptable delay in diagnosis by maintaining a high index of suspicion, low threshold for referral and aggressive use of appropriate investigative modalities. In the journey to diagnosis of a metastatic neck node, possibility of unusual sites and synchronous and metachronous malignancies as well should be kept in mind. Early diagnosis and prompt initiation of treatment can increase the chance of curability of the disease and may provide better quality of life with more survival rates.

Funding: No funding sources

Conflict of interest: None declared

Ethical approval: Not required

REFERENCES

1. Izumi M, Mamoru T, Shigeru F, Shuji S. Tumours metastasizing to the head and neck: A report of seven cases. J Laryngol Otol. 1993;107:1171-3.
2. Kim Y, Goo JM, Kim HY, Song JW, Im JG. Coexisting bronchogenic carcinoma and pulmonary tuberculosis in the same lobe: radiologic findings and clinical significance. Korean J Radiol. 2001;21(3):138-44.
3. Wofford JL, Webb WR, Stauss HK. Tuberculous scarring and primary lung cancer. Clinical and aetiological considerations. Arch Surg. 1962;85:928-35.
4. Kiricuta IC, Mueller G, Stiess J, Bohndorf W. The lymphatic pathways of non-small cell lung cancer and their implication in curative irradiation treatment. Lung Cancer. 1994;11:71-82.
5. Kumar K, Shetty DC, Wadhawan V, Gupta P. Synchronous oral squamous cell carcinomas with unusual histopathological feature. J Oral Maxillofaci Pathol. 2012;16(3):420-4.
6. Bhatt MLB, Kant S, Bhaskar R. Pulmonary tuberculosis as differential diagnosis of lung cancer. South Asian J Cancer. 2012;1(1):36-42.
7. Safa AA, Tran LM, Rege S, Brown CV, Mandelkern MA, Wang M, et al. The role of positron imaging tomography in occult primary head and neck cancers. Cancer J Scientific Am. 1999;5:214-8.
8. Assar OS, Fischbein NJ, Caputo GR, Kaplan MJ, Price DC, Singer MI, et al. Metastatic head and neck cancer: role and usefulness of FDG-PET in locating occult primary tumours. Radiology. 1999;210:177-81.

Cite this article as: Galagali JR, Singh R. Metastatic neck node: a straying journey to diagnosis. Int J Otorhinolaryngol Head Neck Surg 2018;4:1101-3.