

## Case Report

# Nicorandil ulcer: a frequent diagnosis, a rare etiology

Francisco C. Monteiro\*, Pedro J. Oliveira, Bruno F. Domingues, Artur Condé

Department of Otorhinolaryngology, Head and Neck Surgery, Hospital Centre of Vila Nova de Gaia/Espinho, Vila Nova de Gaia, Portugal

**Received:** 04 April 2018

**Accepted:** 23 May 2018

### \*Correspondence:

Dr. Francisco C. Monteiro,

E-mail: francisco.c.monteiro@gmail.com

**Copyright:** © the author(s), publisher and licensee Medip Academy. This is an open-access article distributed under the terms of the Creative Commons Attribution Non-Commercial License, which permits unrestricted non-commercial use, distribution, and reproduction in any medium, provided the original work is properly cited.

### ABSTRACT

Oral ulcers are a relatively frequent diagnosis in otolaryngology practice. They may have a vast etiology, the iatrogenic medication one of them nicorandil is an anti-ischemic drug used in coronary artery disease and is frequently used in combination with other anti-anginal drugs. There are reports of the association between nicorandil and the appearance of painful oral ulcers, with repercussion on patients' quality of life. The authors describe a case of a 76-year-old man with ischemic heart disease past that presented to the emergency department complaining of ulcers on the tongue with 1 week of evolution. He had been medicated with long-standing nicorandil, however he had increased the dose one month before the urge of lesions. He was treated with topical corticosteroid and anti-fungal, with no response. The objective examination showed three ulcerated lesions in the tongue. Given the characteristics of the lesions and absence of response to therapy previously instituted, biopsies were performed. The histopathological results showed nonspecific ulceration aspects. Discussed the case with his Cardiologist and, given the temporal association between increased nicorandil dose and the appearance of the lesions, we decided for the drug suspension. In the reevaluation after two weeks, there was favorable evolution, and 45 days after, the lesions had completely disappeared. For the diagnosis of oral ulcers, being of extremely importance to exclude neoplastic causes, it is relevant not to forget also the rarest etiologies, which although difficult to identify, may lead to a better quality of life and less use of medical care.

**Keywords:** Nicorandil, Oral ulcer, Coronary artery disease

### INTRODUCTION

Oral ulcers are a relatively frequent diagnosis in otolaryngology practice. They may have a vast etiology, the iatrogenic medication one of them. Nicorandil is an anti-ischemic drug used in prevention and long term treating of coronary artery disease, often being used in combination with other anti-anginal agents on refractory stable and unstable angina. The drug has been used in Japan for over a decade and has more recently been introduced in Europe.<sup>1</sup>

Nicorandil is generally well tolerated with common side effects, including flushing, headache and nausea.<sup>2</sup> However, it has become increasingly recognized the

association between nicorandil use and appearance of painful oral ulcers, with repercussions on the quality of life of patient, despite the exact mechanism remains quite unclear. Since the first French report of nicorandil-induced oral ulcers in 1997, there have been report of other nicorandil induced ulcers.<sup>3</sup> A total of 49 cases have been reported worldwide since 1997.<sup>1</sup>

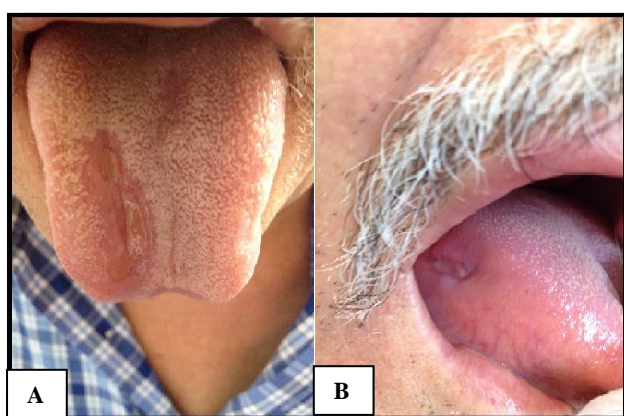
The oral ulcerations associated with nicorandil, objectively, are deep, large, persistent, but tend to lack the yellow base and erythematous halo associated with aphthous ulcers. Most cases of nicorandil induced ulceration that have been biopsed demonstrated nonspecific ulceration.<sup>1</sup> The tongue is often affected, but the ulceration can also involve the hard palate, buccal and

labial mucosa.<sup>3,4</sup> The ulcers cause considerable discomfort and interfere greatly with eating and speaking and thus have a negative impact on quality of life and may result in weight loss.<sup>5</sup>

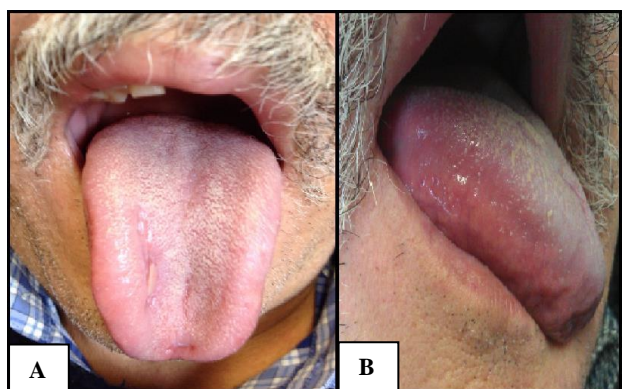Usually they have poor therapeutic response to topical steroids and almost all require change in dosage and even discontinuation. As a matter of fact, they heal rapidly, usually without scarring, following discontinuation of the drug.<sup>1</sup>

## CASE REPORT

The authors describe the case of a 76-year-old man with ischemic heart disease past that presented to the emergency department complaining of ulcers on the tongue with 1 week of evolution (Figure 1).



**Figure 1: (A and B) Ulcers at the emergency department.**



**Figure 2: (A and B) Ulcers after nicorandil discontinuation.**

He had been medicated with long-standing nicorandil; however he had increased the dose to 40 mg twice/day one month before the urge of lesions. He was treated with topical corticotherapy and anti-fungal drugs that were unsuccessful. The objective examination revealed three lesions: a major on the dorsal right face of the tongue, thready, 2 cm of major axis, well-defined edges, smooth, with soft consistency on palpation and painful; other two

lesions with <2 mm confluent in the right edge of the tongue, with characteristics similar to the bigger lesion injury. Given the characteristics of the lesions and absence of response to previously established therapy, biopsies of the ulcers were performed. The histopathological results showed nonspecific ulceration aspects. Discussed the case with his Cardiologist and, given the temporal association between increased nicorandil dose and the appearance of the lesions, we decided for the drug suspension. In the reevaluation after two weeks, there was favorable evolution, and 45 days after, the lesions had completely disappeared (Figure 2).

The principal causes of oral ulceration are trauma, recurrent aphthous stomatitis, microbial infections, mucocutaneous disease, systemic disorders, squamous cell carcinoma and drug therapy.<sup>6</sup> Although many oral ulcers have similar clinical appearances, their etiologic factors differ. Therefore, in many cases, it is not possible to obtain a definitive diagnosis without histopathological examination of a biopsy specimen, and thus a biopsy should be taken from any lesion persisting >2 weeks.<sup>7</sup> However, oral ulcers occasionally have nonspecific histopathological findings, such as cases of nicorandil induced ulcers.

The mechanism by which nicorandil produces oral ulceration remains unclear. There may be a local toxic effect on the oral mucosa. However, faecal excretion of nicorandil is known to be low, and yet it has been implicated in anal ulceration; alternatively the oral ulcers could be a hypersensitivity reaction to nicorandil.<sup>1</sup>

The average dose of nicorandil is 20 mg/day, although it can be higher if clinically indicated. It has been reported that nicorandil-induced adverse effects are dose related and mostly occur following a daily dose >30 mg/day.<sup>8</sup> In many instances, ulceration only develop after an increase in dose, which can be supported by our case. Characteristically, upon discontinuing nicorandil (which may eventually exacerbate the angina), the pain associated with ulcer rapidly disappears and complete healing ensues; depending on the original size of the wound, this usually takes between 2-6 months.<sup>9</sup> In fact, the definitive treatment is withdrawal of nicorandil, which must be done with caution, instituting a gradually tapering regimen and starting another anti-anginal if necessary.

It remains unclear what differentiates those patients who do and do not develop ulceration. Both sexes appear to be equally affected and ulceration can develop as early as weeks or as late as 23 months after therapy is initiated.<sup>9</sup>

It is also important to point out that not all oral ulcerations in patients taking nicorandil can be attributed to the drug, oral cancer often present as deep, persistent oral ulcer and therefore it is essential to exclude this. While it is clear that the lesions heal rapidly following

cessation of nicorandil, the severity of ischemic heart disease may mitigate against this.

Despite uncertain knowledge of the mechanism involved, evidence for the association between nicorandil and oral ulceration is strong, with rapidly resolution after its withdrawal. It is now evident that devastating oral adverse effects might be seen in patients with cardiovascular disease, including in otolaryngology departments. For the diagnosis of oral ulcers, being of extremely importance to exclude neoplastic causes, it is relevant not to forget also the rarest etiologies, which although difficult to identify, may lead to a better quality of life and less use of medical care.

*Funding: No funding sources*

*Conflict of interest: None declared*

*Ethical approval: Not required*

## REFERENCES

1. Healy CM, Smyth Y, Flint SR. Persistent nicorandil induced oral ulceration. *Heart*. 2004;90(7):38.
2. Fox K, Garcia MA, Ardissino D, Buszman P, Camici PG, Crea F, et al. Guidelines on the management of stable angina pectoris: executive summary: The Task Force on the Management of Stable Angina Pectoris of the European Society of Cardiology. *Eur Heart J*. 2006;27(11):1341-81.
3. Agbo-Godeau S, Joly P, Lauret P, Szpirglas R, Szpirglas H. Association of major aphthous ulcers and nicorandil. *Lancet*. 1998;352(9140):1598-9.
4. Webster K, Godbold P. Nicorandil induced oral ulceration. *Br Dent J*. 2005;198(10):619-21.
5. Cribier B, Marquart-Elbaz C, Lipsker D, Alt M, Grosshans E. Chronic buccal ulceration induced by nicorandil. *Br J Dermatol*. 1998;138(2):372-3.
6. Field EA, Allan RB. Review article: oral ulceration-aetiopathogenesis, clinical diagnosis and management in the gastrointestinal clinic. *Aliment Pharmacol Ther*. 2003;18(10):949-62.
7. Munoz-Corcuera M, Esparza-Gomez G, Gonzalez-Moles MA, Bascones-Martinez A. Oral ulcers: clinical aspects. A tool for dermatologists. Part II. Chronic ulcers. *Clin Exp Dermatol*. 2009;34(4):456-61.
8. Desruelles F, Bahadoran P, Lacour JP, Perrin C, Santini J, Ortonne JP. Giant oral aphthous ulcers induced by nicorandil. *Br J Dermatol*. 1998;138(4):712-3.
9. Patel GK, Harding KG. Nicorandil ulcer: moves beyond the mucosa. *Ann R Coll Surg Engl*. 2010;92(6):451-2.

**Cite this article as:** Monteiro FC, Oliveira PJ, Domingues BF, Condé A. Nicorandil ulcer: a frequent diagnosis, a rare etiology. *Int J Otorhinolaryngol Head Neck Surg* 2018;4:1086-8.