

Original Research Article

Otomycosis: a clinical and mycological study

T. Dinesh Singh¹, C. P. Sudheer^{2*}

Department of ENT, ¹Mallareddy Institute of Medical Sciences, Suraram, Hyderabad, ²MNR Medical College and Hospital, Sangareddy, Telangana, India

Received: 24 March 2018

Accepted: 04 May 2018

***Correspondence:**

Dr. C. P. Sudheer,

E-mail: drscpent@gmail.com

Copyright: © the author(s), publisher and licensee Medip Academy. This is an open-access article distributed under the terms of the Creative Commons Attribution Non-Commercial License, which permits unrestricted non-commercial use, distribution, and reproduction in any medium, provided the original work is properly cited.

ABSTRACT

Background: The term otomycosis is used to describe fungal infection of ear i.e. external auditory canal, eardrum. This condition appears as a primary infection or develops along with external bacterial infections as a results of antibiotic therapy. This study was designed to determine the clinical symptoms and fungal flora of otomycosis cases.

Methods: A total 100 (53% males, 47% females) clinically diagnosed otomycosis cases between 06-70 years were included. The external auditory meatus debris was collected by sterile swabs and sent to the microbial laboratory investigations.

Results: Highest prevalence was seen in the age group 21-30 years. Itching in the ear was commonest symptom in 89%, followed by ear ache. Positive fungal growth was seen in 94% cases. *Aspergillus* was the common isolate in 63% cases, followed by *Aspergillus niger* with *Candida albicans* (10%), *penicillium* in 4% cases and *Candida* in 3% cases. Coagulase negative *Staphylococcus* was seen in 32% cases, followed by *Pseudomonas aeruginosa* (12%), *Staphylococcus aureus* (16%), *E. coli* (11%).

Conclusions: The genus most commonly involved in otomycosis is *Aspergillus* followed by *Candida*. Clinical improvement was seen in 91% of cases and most of the cases responded satisfactorily with topical clotrimazole.

Keywords: Otomycosis, Ear, *Aspergillus niger*, *Candida albicans*, *Staphylococcus aureus*, Clotrimazole

INTRODUCTION

Otomycosis is an external fungal infections of pinna, external auditory canal, tympanic membrane and tympanic cavity.¹ Infection is often symptomatic, includes itching, pain, otorrhea, pruritis, tinnitus, tingling and loss of hearing.² Clinical examination usually shows grayish-white and black or cheese-like thick debris and inflammation of the outer ear.³⁻⁸ Prevalence of disease was more in young adults with female predominance. The predisposing factors included wearing head clothes, hot weather, presence of dermatomycoses, dusty working environment and swimming.^{9,10}

Infections may vary from mild to severe to external auditory meatus, in severe cases it is complicated by secondary bacterial infection. The pathogens isolated in

otomycosis were common for the fungal infection of the ear (*Aspergillus niger*, *Aspergillus flavus*, *Aspergillus fumigatus*, *Candida albicans*). The most common pathogenic fungus was *Aspergillus niger* in the otomycosis group.^{11,12} Majority fungal organisms are soil saprophytes and find injure sites for growth, but growth environment in the ear for fungi is dissimilar than systemic cutaneous infection. Almost fungal species can grow and cause infection to ear, but few are more opportunistic.

In the view of the above literature background the present study was designed to evaluate the relation between fungal appearance and clinical symptoms of otomycosis, and to see the incidence of various microbial isolates in otomycosis.

METHODS

The patients presenting with signs and symptoms of otomycosis attending the out-patient Department of E.N.T., Mallareddy Medical College, Hyderabad, during April 2016 to December 2017 in associated with the Department of Microbiology, Mallareddy Medical College, Hyderabad for laboratory studies. A total 100 clinically diagnosed otomycosis cases between 06-70 years were recruited. Cases with signs and symptoms of otomycosis, wax in the external auditory meatus associated with otomycosis, pruritis, otalgia, associated with chronic suppurative otitis media were included and cases without otoscopic evidence of fungi were excluded. While collecting the clinical history particular attention was paid to record nature of complaints, history of similar episodes and history of using ear drops, wooden sticks or metal wax picks for removing wax.

From the suspected cases of otomycosis, external auditory meatus debris was collected by sterile swabs. All samples were transported to the laboratory within 30-60 minutes for mycological and bacteriological investigations. The specimen was inoculated on Sabourauds dextrose agar and Czapek's agar on the same day. Added gentamycin 80mg to prevent bacterial growth and inoculated media were incubated at 25°C and 37°C and were observed for a week. Nutrient agar and Mac Conkey agar were used for bacterial culture. The inoculated medium plates were incubated at 37°C for 24 hours.

RESULTS

Table 1: Incidence of otomycosis during study period in ENT Department.

Year	Total no. of cases	Cases suffering from	
		Otitis Externa	Otomycosis
2016	12729	1802	418
2017	13416	2007	458

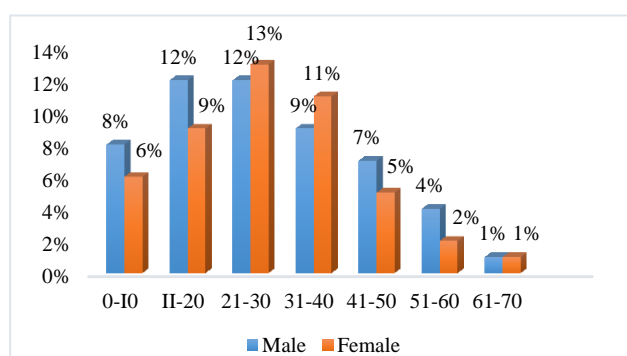


Figure 1: Age wise distribution of male and female otomycosis cases.

Majority cases belonged to the middle economic class (48%), followed by lower (34%) and upper economic

classes (18%). 78% cases belonged to urban areas and 22% were belonged to rural areas. Bilateral otomycosis was seen in 36% of cases, whereas unilateral otomycosis was seen in 64% cases (Figure 2).

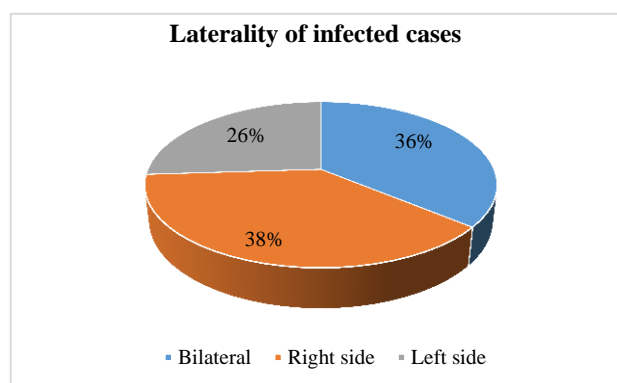


Figure 2: Showing the laterality of infected ear.

Table 2: Showing the various symptoms complained by the patients.

Complaints	Unilateral		Bilateral		Total	
	No.	%	No.	%	No.	%
Ear ache	39	39	26	26	67	67
Itching in the ear	51	51	38	38	89	89
Ear block	40	40	22	22	62	62
Discharge	32	32	16	16	48	48
Hearing impairment	38	38	18	18	56	56
Tinnitus	21	21	09	09	30	30

Table 3: Types of fungal isolates in otomycosis cases.

Type of fungus isolated	No. of cases	%
<i>Aspergillus niger</i>	37	37
<i>Aspergillus flavus</i>	19	19
<i>Aspergillus fumigatus</i>	11	11
<i>Candida albicans</i>	16	16
<i>Aspergillus niger with Candida albicans</i>	10	10
<i>Candida parapsilosis</i>	3	3
<i>Penicillium</i>	4	4

Table 4: Types of bacterial isolates in otomycosis cases.

Type of isolated bacteria	Number	%
<i>Staphylococcus aureus</i>	16	16
<i>Pseudomonas aeruginosa</i>	18	18
<i>E. coli</i>	11	11
<i>Klebsiella aerogenes</i>	10	10
<i>Proteus vulgaris</i>	5	5
<i>Proteus mirabilis</i>	8	8
<i>Coagulase negative staph.</i>	32	32

Table 5: Effect of various administered drugs on otomycosis cases.

Drugs administered	Number of cases	Sensitive	Resistance
Clotrimazole	65	62 (62)	3 (3)
2.5% salicylic acid in 70% alcohol	21	17 (17)	4 (4)
Tinaderm solution	08	7 (7)	1 (1)
Tyotocin ear drops	06	6 (6)	1 (1)

Among the cases (n=65) administered with clotrimazole, 62% of cases shown clinical improvement in signs and symptoms. There was resistance to the drug in 3% of the clotrimazole group (Table 5).

DISCUSSION

Otomycosis is a superficial fungal infection of the external ear, which needs long term treatment and tends to relapse. This study was aimed to assess the relationship between the fungal appearance and clinical symptoms of otomycosis, and to determine most prevalent microbial isolate in otomycosis. A total 100 cases (53 males, 47 females) between age group 06-70 years were considered. Incidence was highest in young adults. In some studies, the incidence of the disease was significantly higher in females, mainly housewives, than in males.^{10,13}

Itching in the ear was commonest symptom in 89% of the patients. The fungus growth mixed with the epithelial debris and cerumen forms characteristic mycotic plug. This gives rise the symptom of blocked ear. A study by Ravinder et al stated that ear blockage is the commonest symptom (93.7%) followed by itching (71.5%).¹⁴ Whereas itching (88%) was the most common symptom, followed by an ear block (87.5%), discharge (30%) and tinnitus (22%), in a study by Paulose et al and Oliveri et al.^{15,16}

In the present study, positive fungal growth was seen in 94% cases. *Aspergillus* was the common isolate in 63% cases, followed by *Aspergillus niger* with *Candida albicans* (10%), *Penicillium* in 4% cases and *Candida* in 3% cases. The results of the present study correlate with the study of Yehia et al and Than et al.^{17,18}

In the present study, coagulase negative staphylococcus was seen in 32% cases, followed by *Pseudomonas aeruginosa* (12%), *Staphylococcus aureus* (16%), *E. coli* (11%), *Klebsiella* (10%) and *Proteus* species in 8%. Staphylococcus areas are the most common bacterial isolate in a study by Arshad et al and Darko et al.^{19,20}

An attempt was made to evaluate the therapeutic effect of four antifungal agents. In 91% of cases, clinical

improvement was observed. All the patients were followed up at the weekly interval for their response to the medication. Among the cases (n=65) administered with clotrimazole, 62% of cases shown clinical improvement in signs and symptoms. There was resistance to the drug in 3% of clotrimazole group.

CONCLUSION

The right ear is more commonly affected than the left ear due to increased chances of self-inflicted trauma by the patients, who are mostly right handed. The commonest symptoms pertaining to otomycosis are itching, pain and discharge from the ears. Tinnitus and giddiness are caused by the mycotic plug pressing on the tympanic membrane. *Aspergillus* was the common isolate in 63% cases, followed by *Aspergillus niger* with *Candida albicans* (10%), *Penicillium* in 4% cases and *Candida* in 3% cases.

Funding: No funding sources

Conflict of interest: None declared

Ethical approval: The study was approved by the Institutional Ethics Committee

REFERENCES

- Vennevald I, Klemm E. Otomycosis: diagnosis and treatment. Clin Dermatol. 2010;28:202–11.
- Sangavi AKB, Peerapur B, Gummadi N. Clinico-mycological study of otomycosis in Raichur, Karnataka: a hospital based study. Int J Otorhinolaryngol Head Neck Surg. 2018;4(1):233-6.
- Gharaghani M, Seifi Z, Zarei Mahmoudabadi A. Otomycosis in Iran: a review. Mycopathologia. 2015;179(5-6):415–24.
- Jia X, Liang Q, Chi F, Cao W. Otomycosis in Shanghai: aetiology, clinical features and therapy. Mycoses. 2012;55(5):404–9.
- Kiakojuji K, Roushan MRH, Sepidgar SAA. Suction clearance and 2% topical miconazole versus the same combination with acidic drops in the treatment of otomycosis. Southeast Asian J Trop Med Public Health. 2007;38:749–53.
- Kombila M, Gomez dDM, De Bievre C, Crepet G, Debrie J, Belembaogo E, et al. Fungal otitis in Libreville. Study of 83 cases. Bull Soc Pathol Exot Filiales. 1988;82:201–7.
- Jung T, Jin T. Diseases of the external ear. In: Ballenger's otorhinolaryngology head and neck surgery. 6th ed. Spain: BC Decker; 2003.
- Mishra G, Mehta N, Pal M. Chronic bilateral otomycosis caused by *Aspergillus niger*. Mycoses. 2004;47:82–4.
- Ozcan KM, Ozcan M, Karaarslan A, Karaarslan F. Otomycosis in Turkey: predisposing factors, aetiology and therapy. J Laryngol Otol. 2003;117:39-42

10. Paulose KO, Al Khalifa S, Shenoy P, Sharma RK. Mycotic infection of the ear (otomycosis). *J Laryngol Otol.* 1989;103:30-5.
11. Nwabuisi C, Ologe FE. The fungal profile of otomycosis patients in Ilorin, Nigeria. *Niger J Med.* 2001;10:124-6.
12. Koç AN, Oğuzkaya M, Erdem F. Otomikoza neden olan mantar türleri. *Türk Mikrobiyol Cem Derg.* 1998;28:96-8.
13. Enweani IB, Igumbor H. Prevalence of otomycosis in malnourished children in Edo State, Nigeria. *Mycopathologia.* 1997-98;140:85-7.
14. Kaur R, Mittal N, Kakkar M. Otomycosis – A clinicomycologic study. *Ear, Nose, Throat J.* 2000;79:606-9.
15. Oliveris S, Capello G, Napolitano Ma Trido C. Cullae Study of otomycosis (aetiology and analysis of predisposing factors). *Boll Ist Sieroter Milan.* 1984;63:537-42.
16. Paulose KO, Khalifa SA, Shenoy P, Sharma RK. Mycotic infections of the ear. A prospective study. *J Laryngologyotol.* 1989;103:30-5.
17. Than KM, Naing KS, Min M. Otomycosis in Burma – The American journal of Tropical. *Med Hygiene.* 1980;29(4).
18. Yehia MM, Al Habib HM, Shehab NM, Otomycosis a common problem in North Iraq. *J Laryngology Otology.* 1990;104:387-9.
19. Arshad M, Khan NU, Ali N, Afridi NM, Sensitivity and spectrum of bacterial isolates in infectious otitis externa. *J Coll Physicians Surg Pakistan.* 2004;3(14):3146-9.
20. Darko E, Jenca A, Orenca KM. Otomycosis of Candidal origin in Eastern Slovakia. *Folia Microbiologica.* 2004;44(4):277-83.

Cite this article as: Singh TD, Sudheer CP. Otomycosis: a clinical and mycological study. *Int J Otorhinolaryngol Head Neck Surg* 2018;4:1013-6.