

## Case Report

# A rare case of sinonasal actinomycosis – enigmatic presentation

Vikas Gupta<sup>1</sup>, Gunjan Dwivedi<sup>1\*</sup>, P. Sengupta<sup>2</sup>, Shailendra Tripathi<sup>1</sup>,  
Sunil Goyal<sup>1</sup>, Manoj Kumar<sup>1</sup>, Amit Sood<sup>1</sup>

<sup>1</sup>Department of ENT-HNS, <sup>2</sup>Department of Pathology, Command Hospital, Armed Forces Medical College, Pune, India

**Received:** 11 March 2018

**Accepted:** 07 April 2018

### \*Correspondence:

Dr. Gunjan Dwivedi,

E-mail: entgunjan@gmail.com

**Copyright:** © the author(s), publisher and licensee Medip Academy. This is an open-access article distributed under the terms of the Creative Commons Attribution Non-Commercial License, which permits unrestricted non-commercial use, distribution, and reproduction in any medium, provided the original work is properly cited.

## ABSTRACT

Actinomycosis is most commonly seen in cervico-facial, abdominal, genital and thoracic regions as discharging sinuses. Most common organism implicated is *Actinomyces israelii*, gram positive anaerobic commensal bacteria of aero-digestive tract. Actinomycosis of paranasal sinuses is an extremely rare entity with isolated case reports and small case series published in literature. Among all sinuses maxillary sinus is most commonly afflicted by this disease. Pathogenesis involves inoculation of the bacteria into the tissues through breach in mucosa by trauma or surgical procedure. It requires anaerobic environment to grow into soft tissues and invade bone. It warrants treatment in form of surgical debridement and long term antibiotic therapy. Here, we present one such rare case of sinonasal actinomycosis in a 60 year old diabetic male who earlier had been treated as a case of sinonasal mucormycosis about one year back. This case was managed successfully with debridement encompassing infrastructure maxillectomy followed by a long course of Penicillin group of antibiotic. Preoperatively there was a diagnostic dilemma whether we were dealing with chronic invasive fungal sinusitis or actinomycosis. Actinomycosis was confirmed postoperatively on histopathology and microbiology.

**Keywords:** Actinomycosis, Sinonasal, Infrastructure maxillectomy

## INTRODUCTION

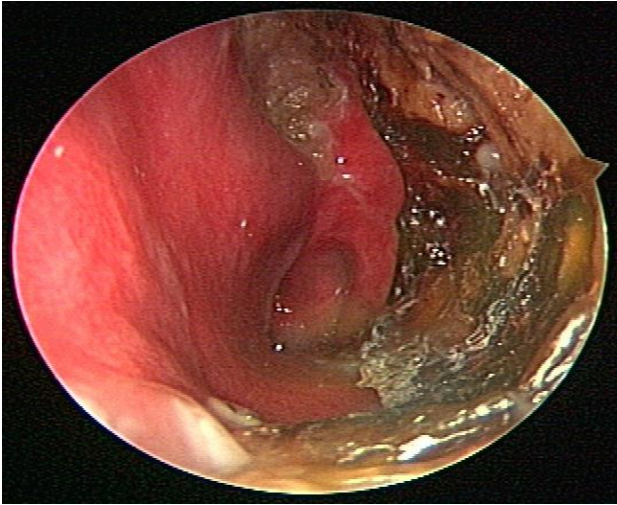
Actinomycosis is a very rare gram-positive, anaerobic bacterial infection. The organism implicated most commonly in this infection is *Actinomyces israelii*, a gram positive bacillus and anaerobic commensal of aero-digestive tract.<sup>1,2</sup> Other less commonly found organisms are *Actinomyces meyeri* and *A. viscosus*. Actinomycosis most commonly occurs in the cervico-facial region followed by abdominal, genital and thoracic regions as discharging sinuses.<sup>3,6</sup> Actinomycosis of paranasal sinuses is an extremely rare entity with isolated case reports and small case series published in literature. Among all sinuses, maxillary sinus is the most commonly afflicted sinus (>50%), by this disease.<sup>4</sup> Pathogenesis involves inoculation of the bacteria into the tissues

through breach in mucosa by trauma, dental surgery or other surgical procedures.<sup>4</sup> This disease being rare, there is a very low degree of suspicion for this disease which leads to difficulty in making this diagnosis. Following is a case report of one such rare and interesting case of sinonasal actinomycosis.

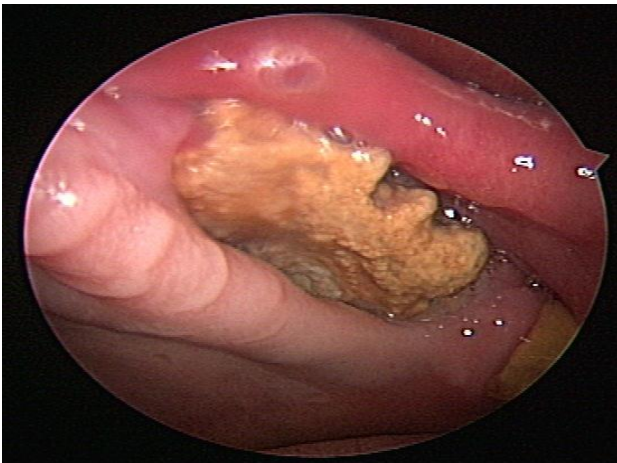
## CASE REPORT

Our patient was a 60 years old male, known case of diabetes mellitus type-II with poor glycemic control. Patient was a known case of (L) sinonasal mucormycosis who had been managed one year earlier in August 2016 with endoscopic surgical debridement of diseased tissue which included partial endoscopic medial maxillectomy (L), orbital decompression and Draf I procedure (L). He

was also given injectable antifungals. The disease had resolved.



**Figure 1: Bone erosion over (L) lateral nasal wall.**

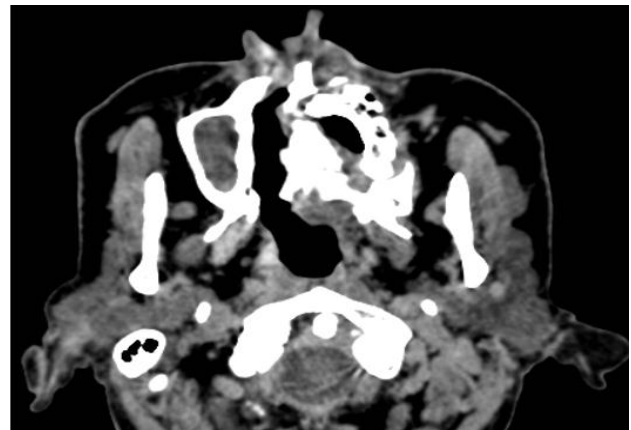

**Figure 2: Exposed upper alveolus bone.**

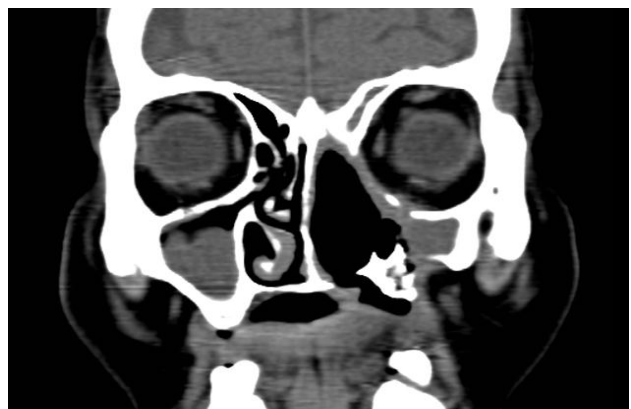Patient reported in September 2017 with symptoms of (L) side nasal obstruction and regurgitation of food from oral cavity into (L) nasal cavity and diminished vision in (L) eye. The patient had been non compliant with medication for diabetes mellitus for previous three months. Diagnostic nasal endoscopic examination revealed post operative status with crusts seen filling the (L) nasal cavity. Bone was found exposed over (L) lateral wall and floor of nasal cavity (Figure 1) and appeared necrosed. Oral cavity examination showed oro-nasal fistula with exposed and necrosed upper alveolus bone (Figure 2). On ophthalmological evaluation diminution of vision was attributed to cataract (L) eye and eye movements were full and free in all directions. Biopsy was taken from nasal cavity which was negative for mucormycosis or any other fungus and showed only inflammatory cells. In view of clinical suspicion of recurrence of mucormycosis, repeat biopsy was taken from the lesions in the nasal cavity and oral cavity separately. Microbiological study was negative for mucormycosis however on lactophenol

cotton blue mount it showed thin septate hyphae, doubtful for fungus, along with numerous inflammatory cells with epithelium in background. Histopathological examination of the specimen ruled out malignancy. Grocott and *p*-aminosalicylic acid (PAS) stains of the slides revealed entangled thin branching filaments spread in and around areas of necrosis and bacterial colonies. Differential diagnosis of mycetoma and actinomycosis were offered on histopathology. The repeat negative biopsy for mucormycosis and the indolent nature of disease raised a suspicion against the clinical diagnosis of recurrence of mucormycosis.

On further evaluation, he was diagnosed with chronic kidney disease, with deranged blood urea and serum creatinine, and also found to have hyperglycemia. The comorbidities were managed effectively in consultation with nephrologist.

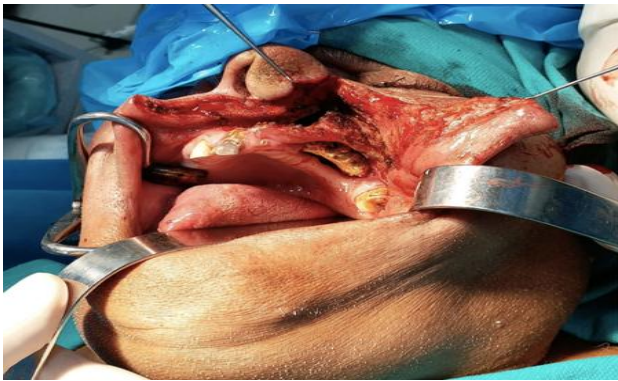

**Figure 3: Medial wall of (L) maxillary sinus is partially absent (probably due to previous surgery), hypodense contents were seen in maxillary sinus, erosion of posterolateral antral wall seen, fat plane with lateral pterygoid muscle preserved, posterior wall of (L) maxillary sinus was deficient with involvement of lower part of pterygomaxillary fissure and pterygopalatine fossa.**

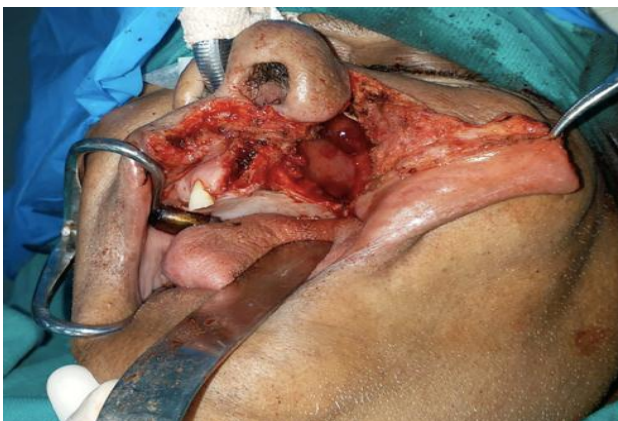


**Figure 4: Erosion of floor and medial wall of orbit seen with extension of soft tissue to extraconal compartment, extraocular muscles appear free.**

Contrast enhanced computed tomography (CT) imaging done at our center revealed following findings: medial wall of (L) maxillary sinus was partially absent (probably due to previous surgery), hypodense contents were seen in maxillary sinus, bone erosion was seen in posterolateral antral wall, however fat plane with lateral pterygoid muscle was preserved. Bone erosion was seen in posterior wall of maxillary antrum with involvement of pterygo-maxillary fissure and pterygo-palatine fossa in inferior part (Figure 3 and 4). Anterior wall, floor of maxilla and nasal cavity (L) also showed bone erosion. There was no extension to inferior orbital fissure. Erosion of floor and medial wall of orbit was seen with extension of soft tissue to extraconal compartment however extraocular muscles were free. No erosion of bone was seen in sphenoid or frontal sinus region. There was no intracranial extension or any evidence of cavernous sinus thrombosis. A plan for debridement of disease was made.



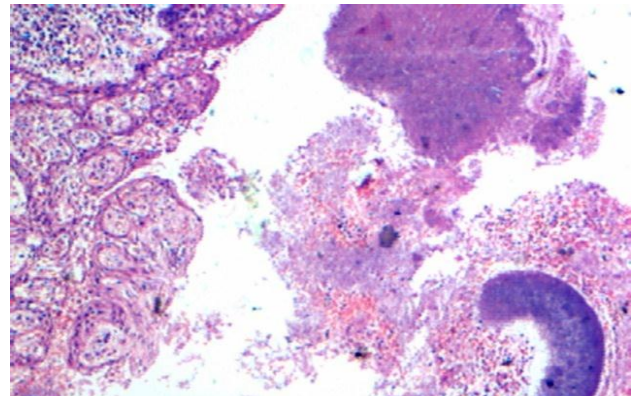
**Figure 5: Intraoperative photograph: showing oral cavity with necrosed hard palate.**



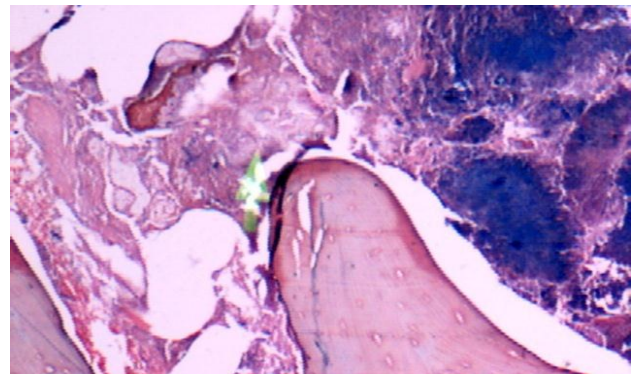
**Figure 6: Post debridement complete clearance of disease.**

He underwent debridement of diseased tissue, encompassing left infrastructure maxillectomy through Weber-Fergusson incision (Figure 5). Adequate clearance of diseased tissue was achieved on all sides (Figure 6). The specimen sent for histopathological examination revealed thin basophilic bacterial filaments along with extensive necrosis and dense inflammatory cells which

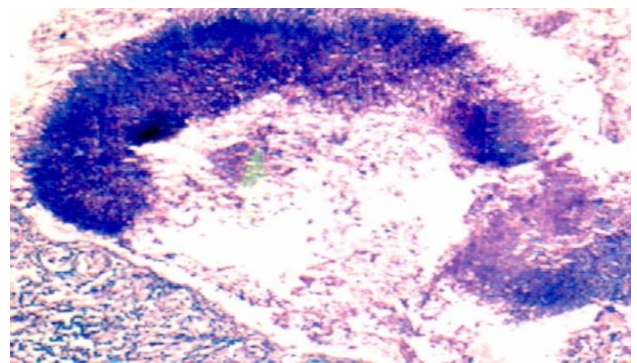
were predominantly neutrophils. Haematoxylin Eosin (HE) stain revealed lining epithelium with actinomycotic colonies (Figure 7) and it also showed invasion of actinomycotic colonies in maxillary bone (Figure 8).



**Figure 7: Lining epithelium with actinomycotic colonies.**



**Figure 8: HE stain showing invasion of actinomycotic colonies into maxillary bone.**



**Figure 9: PAS stain actinomycotic colonies.**

Periodic acid-Schiff and Grocott stains also revealed actinomycotic colonies (Figure 9 and 10). Patient was managed with injectable Amoxicillin+Clavulanate antibiotics for 3 weeks as admitted patient. Patient showed resolution of disease and after the wound had healed he was rehabilitated with palatal obturator for oronasal separation. He was continued on oral

amoxicillin for following three months. On follow up at 6 months post-surgery he has been found to be disease free (Figure 11 and 12). He continues to be on follow up at this centre.

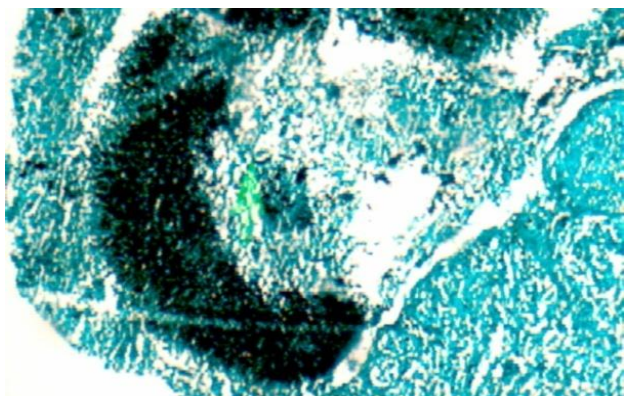


Figure 10: Grocott stained actinomycotic colonies.

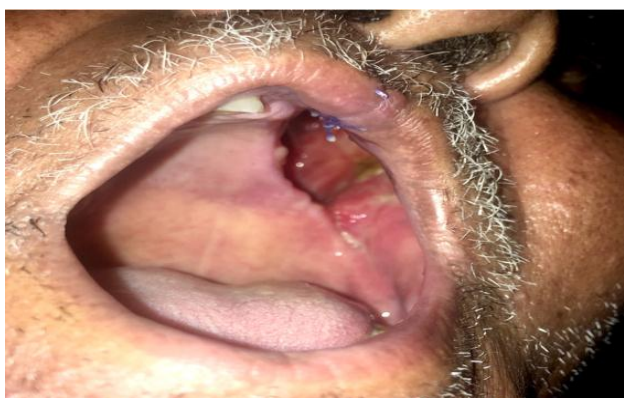

Figure 11: Post operatively well healing mucosa.

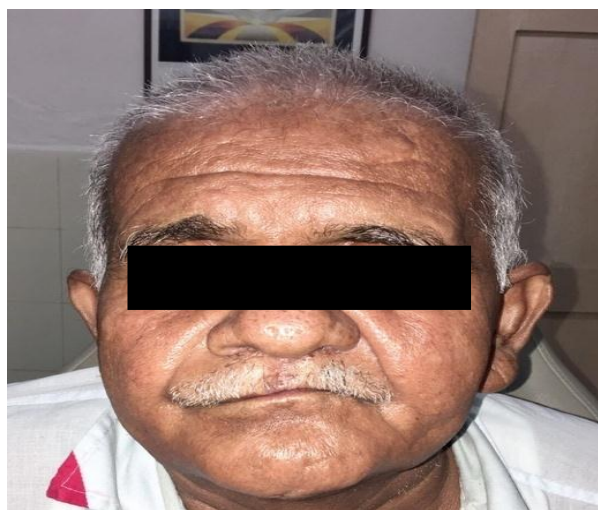

Figure 12: Healed facial wound.

## DISCUSSION

Various species of Actinomyces are known which infect humans and these include facultative anaerobes such as

*A. israelii*, *A. odontolyticus*, *A. meyeri*, *A. naeslundii*, *A. viscosus*, and *A. gerencseriae*.<sup>7</sup> The causative organism *A. israelii* was discovered by James Israel and thus it bears his name. Actinomyces is normally found in aerodigestive tract as a commensal. Infection occurs through breach in mucosa either due to trauma or surgical procedures, more commonly dental procedures.<sup>4,5</sup> Historically Actinomycosis was mistaken for fungal infection hence the misnomer.

The incidence of cervicofacial Actinomycosis has been found to be 25% of all odontogenic infections.<sup>7</sup> Actinomycosis of paranasal sinuses is very rare out of which maxillary sinus is most common.<sup>4</sup> Actinomycosis of paranasal sinuses is caused commonly by *A. israelii*, gram positive anaerobic bacteria. It causes chronic necrotizing infection in humans and animals. There is no person-to-person transmission of the pathogenic *Actinomyces* species.<sup>8</sup>

*Actinomyces* species are infrequently visible in sections stained with hematoxylin-eosin (HE), therefore special stains such as Grocott methenamine – silver nitrate stain, PAS, MacCallen-Goodpasture stain or Brown-Brenn stain can be used.<sup>9</sup> In our patient HE, PAS and Grocott stains were used for confirmation of diagnosis.

Penicillin is the drug of choice for all clinical forms of actinomycosis. Literature review shows, mild forms of cervicofacial infections can be managed with a 2 month course of oral penicillin V or one of the tetracyclines such as doxycycline (100 mg given orally twice daily) without surgical intervention.<sup>9</sup> For other more complicated forms of actinomycosis, parenteral penicillin G (10–20 million Units per day divided into four doses), should be administered for 4–6 weeks, followed by oral penicillin V, 2–4 g/d divided every 6 hours, for 6–12 months.<sup>10</sup> For patients allergic to penicillin, erythromycin, clindamycin, tetracycline or cephalosporins can be used as alternatives.<sup>11</sup> Long duration of treatment is required as the penetration of beta-lactam antibiotics into the bone is low. Therefore it is prudent to give a long duration of antibiotic treatment to prevent relapse.<sup>2,12</sup> Severity of disease and its site decides the exact duration of treatment.

Surgery is required in most of the cases to remove necrotic tissue which facilitates faster recovery with medical management. Thus most of the cases require combined medical and surgical management to cure this tenacious disease. Surgery is, most of the time, not curative in itself.

This disease occurs more commonly in immunocompromised patients such as patients of cancers, HIV, diabetes, malnourishment, on immunosuppressive drugs.<sup>2</sup>

The enigmatic presentation of actinomycosis in a known treated case of sinonasal mucormycosis (L) makes this an interesting case where the route of infection appears to be

mucosal breach due to previous surgery. Suspicion of recurrence of mucormycosis in this patient was distracting us from the diagnosis of actinomycosis initially. Malignancy was also in one of our differential diagnoses. Our case is a rare case of inoculation of actinomyces in a post-operative patient of mucormycosis.

This case is being reported so as to add to the myopic literature available on this subject.

*Funding: No funding sources*

*Conflict of interest: None declared*

*Ethical approval: Not required*

## REFERENCES

1. Bennhoff DF. Actinomycosis: diagnostic and therapeutic considerations and a review of 32 cases. *The Laryngoscope*. 1984;94(9):1198-217.
2. Valour F, Sénéchal A, Dupieux C, Karsenty J, Lustig S, Breton P, et al. Actinomycosis: etiology, clinical features, diagnosis, treatment, and management. *Infection and drug resistance*. 2014;7:183.
3. Sharkawy AA. Cervicofacial actinomycosis and mandibular osteomyelitis. *Infectious Disease Clinics*. 2007;21(2):543-56.
4. Roth M, Montone KT. Actinomycosis of the paranasal sinuses: a case report and review. *Otolaryngology—Head and Neck Surgery*. 1996;114(6):818-21.
5. Woo HJ, Chang Hoon B, Song SY, Choi YS, Kim YD. Actinomycosis of the paranasal sinus. *Otolaryngology—Head Neck Surg*. 2008;139(3):460-2.
6. Vorasubin N, Wu AW, Day C, Suh JD. Invasive sinonasal actinomycosis. *The Laryngoscope*. 2013;123(2):334-8.
7. Schaal KP, Lee HJ. Actinomycete infections in humans—a review. *Gene*. 1992;115(1):201-11.
8. Peabody Jr JW, Seabury JH. Actinomycosis and nocardiosis. *Journal of chronic diseases*. 1957;5(4):374-403.
9. Smego Jr RA, Foglia G. Actinomycosis. *Clin Infect Dis*. 1998;26(6):1255-61.
10. Martin MV. The use of oral amoxycillin for the treatment of actinomycosis. A clinical and in vitro study. *British Dental J*. 1984;156(7):252.
11. Schaal KP. Genus *Actinomyces* Harz 1877, 133. In: Sneath PHA, et al. (eds) *Bergey's manual of systematic bacteriology*. Williams and Wilkins, Baltimore; 1986:1383-418.
12. Bennhoff DF. Actinomycosis: diagnostic and therapeutic considerations and a review of 32 cases. *The Laryngoscope*. 1984;94(9):1198-217.

**Cite this article as:** Gupta V, Dwivedi G, Sengupta P, Tripathi S, Goyal S, Kumar M, et al. A rare case of sinonasal actinomycosis – enigmatic presentation. *Int J Otorhinolaryngol Head Neck Surg* 2018;4:863-7.