

## Case Report

# Life threatening complication of fine needle aspiration of neck mass in a child: a case report

Pramod S.<sup>1\*</sup>, Rewanth Reddy<sup>2</sup>

<sup>1</sup>Department of Paediatric Surgery, <sup>2</sup>Department of Surgery, Kempegowda Institute of Medical Sciences and Research Institute, Bangalore, Karnataka, India

**Received:** 02 March 2018

**Accepted:** 05 April 2018

### \*Correspondence:

Dr. Pramod S.,

E-mail: [pramodbmc76@gmail.com](mailto:pramodbmc76@gmail.com)

**Copyright:** © the author(s), publisher and licensee Medip Academy. This is an open-access article distributed under the terms of the Creative Commons Attribution Non-Commercial License, which permits unrestricted non-commercial use, distribution, and reproduction in any medium, provided the original work is properly cited.

### ABSTRACT

Fine needle aspiration biopsy has become an important first line of investigation in palpable neck masses. It is simple, sensitive, inexpensive and safe investigation. Minor complications include pain, rashes and irritation at the site of aspiration. Life threatening complication occurs rarely. This is a report of child who presented with internal carotid artery injury with a massive hematoma causing respiratory distress following Fine needle aspiration. The child underwent neck exploration with evacuation of hematoma. Though life threatening complications post Fine needle aspiration are rare, this case highlights the precautions to be taken while performing fine needle aspiration in deep seated neck mass.

**Keywords:** Fine needle aspiration biopsy, Neck, Hematoma, Pain

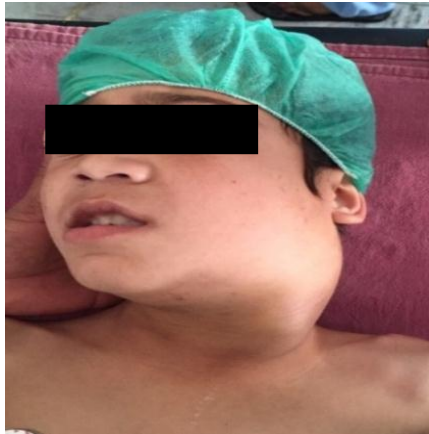### INTRODUCTION

Neck swellings in children may be due to various causes. Fine needle aspiration cytology (FNAC) has become an important first line of investigation in palpable neck masses. It was first described by Kunl.<sup>1</sup> It is simple, sensitive, inexpensive, rapid and safe investigation available in the assessment of patients with lateral neck swellings. Complications related to FNAC in neck are rare and insignificant. Common complication includes pain, minor hematoma and irritation at the site of aspiration.<sup>2</sup> Life threatening complications include hematoma, pseudoaneurysm, carotid artery hematoma, tracheal perforation, dysphagia, recurrent nerve paralysis, sinus along needle tract, vasovagal reaction, and secondary hemangioma.<sup>2,3</sup> Aim of this case report is create awareness about devastating consequence of simple procedure like FNAC- if not done cautiously.

### CASE PRESENTATION

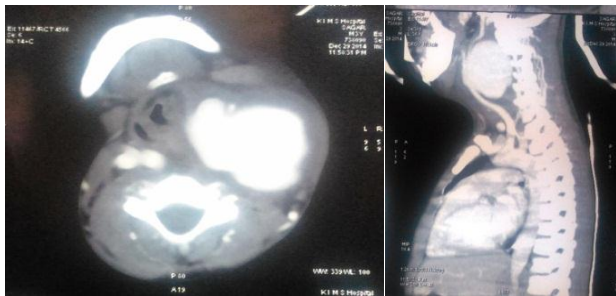
9 year old male child developed a painless swelling in the left lateral aspect of the neck since one and half months and had undergone diagnostic needle aspiration of the swelling at a local clinic 3 weeks ago following which there was a rapid increase in the size of the swelling associated with pain. Initially the neck mass (lymph node) was 2x2 centimeter. Other symptoms included hoarseness of voice, difficulty in swallowing. Child was comfortable in left lateral position as he had respiratory distress in supine position.

On examination, a large solitary, firm, non-pulsatile swelling was noticed in the left lateral aspect of the neck measuring about 12x8 cm (Figure 1). Trachea was displaced to the right. Child was admitted with the diagnosis of solid neck swelling with possibility of malignancy.



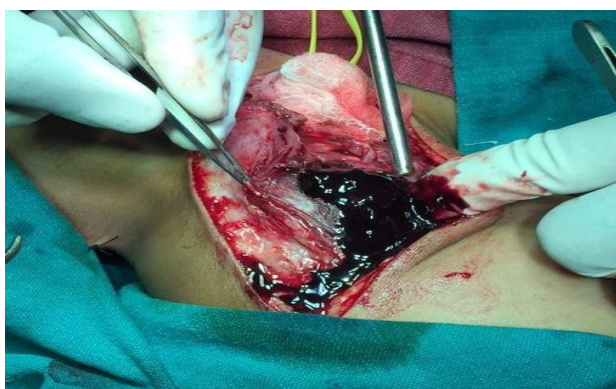**Figure 1: Extent of swelling in neck.**

Routine blood investigations were normal. CT scan of the neck revealed highly vascular lesion with a differential diagnosis of ICA pseudo aneurysm, arterio venous malformation (Figure 2).



**Figure 2: CT findings.**

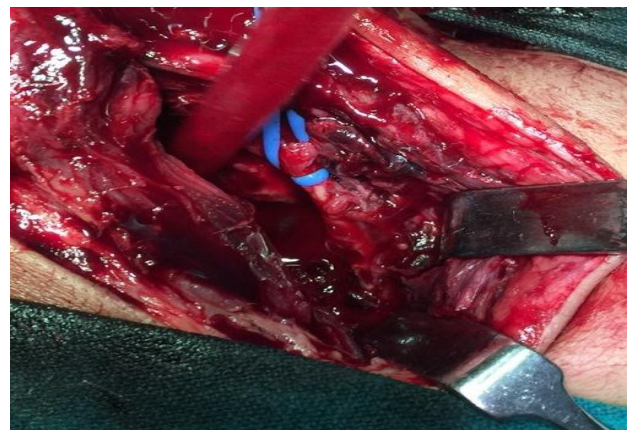
Child had to be shifted to pediatric intensive care unit (PICU) preoperatively in view of worsening of respiratory distress. In consultation with vascular surgeon child was taken up for neck exploration after counselling attenders regarding post-operative complication which included neurological deficits, seizures, mechanical ventilation.



**Figure 3: Blood clots.**

Intra operatively intubation was difficult due to tracheal deviation. Neck exploration revealed pseudo aneurysm of

left ICA with a thick fibrous capsule posterior to the left sternocleidomastoid muscle. Proximal and distal control of left ICA taken with application of slings. The muscle had to be released from its origin at the clavicle in order to take control of the proximal left common carotid artery. Once the capsule incised and swelling entered, blood clots to the extent of 800 ml to 1 litre was present (Figure 3). Following evacuation of the clots, site of injury to the left internal carotid artery (ICA) was identified. Closer examination revealed multiple puncture injuries to the left ICA for a length of 1 cm (Figure 4). Repair of the artery done using prolene 6'0. Distal pulsations were confirmed and the wound closed in layers after the placement of drain. Intra operatively child was hemodynamically stable, and required one packed cell transfusions. Post operatively child was monitored in PICU for 48 hours and was discharged after an uneventful recovery. The child is doing well on follow up after one year. Follow up Doppler shows good flow in the carotid artery.



**Figure 4: Puncture injuries to left internal carotid artery.**

## DISCUSSION

Fine needle aspiration cytology (FNAC) is an important tool in diagnosing neck masses. It was first described by Kunl.<sup>1</sup> FNAC was introduced in USA 80 years later by a surgeon in Memorial Sloan Kettering hospital.

FNAC was first reported in children by Jereb et al in 1978.<sup>4</sup> FNAC for paediatric neoplasms was first used by Shaller and colleagues in 1983.<sup>5,6</sup> Since then, FNAC has become a more acceptable diagnostic procedure in the paediatric age group and is well established in the adult population. Howell reported in his work the increasing application of fine needle aspiration cytology in superficial palpable lesions in the children.<sup>7</sup> Doing FNAC avoids the need for open surgical biopsy in 40-75% of patients.<sup>6-10</sup>

Neck masses in children can broadly be classified as congenital, inflammatory and malignant. Persistent or suspicious lymphadenopathy is the most common neck

mass encountered in children and the common indication for FNAC.<sup>6,8,10</sup> Van de Schoot et al in his study found that FNAC is a useful initial diagnostic tool in children with persistent or suspicious peripheral lymphadenopathy to distinguish between benign and malignant disease<sup>11</sup>. Reactive lymphadenitis has to be differentiated from tuberculosis and lymphoma in developing country

FNAC is usually done using a 22-25 gauge needle fitted to a 10 millilitre (ml) or a 20 ml disposable syringe. The swelling is immobilized and multiple passes are done to get sufficient material. In the present child, the size of punctures indicates a wide bore needle was used. Multiple punctures correlates to the multiple passes done to get enough aspirates.

Reported complications of FNAC in neck mass include ecchymosis, hematoma, a draining sinus tract, tumor tracking, pseudo aneurysm and pneumothorax. These complications are rare. Cases of carotid artery hematoma following fine needle aspiration have been reported. Reason for hematoma is because of the close proximity of the vessels to the lymph nodes. This is especially true wherein aspiration is being done for lymph nodes which are not properly palpable. Hematoma results from seepage of blood into the carotid sheath or the neck tissue following damage to the carotid wall during Fine needle aspiration process. In few cases the hematoma can grow to alarming size causing respiratory distress. Carotid artery hematoma should be considered in case of pain, increasing swelling, mass effect post aspiration. Hematoma can push the trachea towards opposite side. In our case the trachea was pushed to the right side and patient had respiratory distress. In patients where hematoma does not cause respiratory distress close monitoring of the patient is required with ultrasonography. Most of the cases the hematoma is reabsorbed spontaneously.<sup>2,3</sup> In patients with respiratory distress hematoma drainage is required. With the use of ultrasound guided FNAC the accuracy and safety of the procedure has increased.

## CONCLUSION

This case highlights the rare complication of FNAC. Though a simple procedure if not done properly may lead to devastating consequences. This case also emphasizes the importance of ultrasound guided FNAC in deep seated neck swellings.

*Funding: No funding sources*

*Conflict of interest: None declared*

*Ethical approval: Not required*

## REFERENCES

1. Kun MA. New instrument for the diagnosis of tumors. *Month J Med Sci.* 1847;7:853-4.
2. Polyzos SA, Anastasilakis AD. Clinical complications following thyroid fine-needle biopsy: a systematic review. *Clin Endocrinol.* 2009;71:157-65.
3. Anastasilakis AD, Polyzos SA, Nikolopoulos P. Subendothelial carotid hematoma after fine needle aspiration biopsy of a solitary thyroid nodule. *J Ultrasound Med.* 2008;27(10):1517-20.
4. Jereb B, Us-Krasovec M, Jereb M. Thin needle biopsy of solid tumors in children. *Med Pediatr Oncol* 1978;4:213-20.
5. Schaller Jr RT, Schaller JF, Buschman C, Kiviat N. The usefulness of percutaneous fine-needle aspiration biopsy in infants and children. *J Pediatr Surg.* 1983;18:398-405.
6. Ramadhan HH, Wax MK, Boyd CB. Fine-needle aspiration of head and neck masses in children. *AM J Otolaryngol.* 1997;18:400-4.
7. Howell LP. Changing role of fine needle aspiration in diagnosis of pediatric masses. *Diagn Cytopathol* 2001;24:65-70.
8. Wakely Jr PE, Kardos TF, Frable WJ. Application of fine needle aspiration biopsy to pediatrics. *Hum Pathol.* 1988;19:1383-6.
9. Tunkel DE, Baroody FM, Sherman ME. Fine-needle aspiration biopsy of cervicofacial masses in children. *Arch Otolaryngol Head Neck Surg* 1995;121:533-6.
10. Liu ES, Bernstein JM, Sculerati N, Wu HC. Fine needle aspiration biopsy of pediatric head and neck masses. *Int J Pediatr Otorhinolaryngol.* 2001;60:135-40.
11. Van De Schoot L, Aronson DC, Behrendt H, Bras J. The role of fine-needle aspiration cytology in children with persistent or suspicious lymphadenopathy. *J Pediatr Surg.* 2001;36:7-11.

**Cite this article as:** Pramod S, Reddy R. Life threatening complication of fine needle aspiration of neck mass in a child: a case report. *Int J Otorhinolaryngol Head Neck Surg* 2018;4:860-2.