

Original Research Article

DOI: <http://dx.doi.org/10.18203/issn.2454-5929.ijohns20181065>

Use of feracrylum in tonsillectomy

Sathyaki D. C.^{1*}, Mereen Susan Roy¹, Vishnu Kumar G.², Jyothiswarup R.¹

Department of E.N.T., ¹Sri Siddhartha Medical College, Tumkur, Karnataka, ²Kottayam medical college, Kottayam, Kerala, India

Received: 01 March 2018

Revised: 16 March 2018

Accepted: 17 March 2018

***Correspondence:**

Dr. Sathyaki D.C.,

E-mail: sathyaki_dc@yahoo.co.in

Copyright: © the author(s), publisher and licensee Medip Academy. This is an open-access article distributed under the terms of the Creative Commons Attribution Non-Commercial License, which permits unrestricted non-commercial use, distribution, and reproduction in any medium, provided the original work is properly cited.

ABSTRACT

Background: Haemorrhage is the most common complication which is encountered in tonsillectomy. Various methods have been employed to minimise it. One such method has been employed in this study. The objective of the study was to study the efficacy of feracrylum in reducing post tonsillectomy haemorrhage with that of tranexemic acid.

Methods: 40 patients who underwent tonsillectomy in a tertiary care centre were involved in this study. They were classified into two groups with 20 patients in each group.

Results: Use of feracrylum reduced the haemorrhage significantly. Only one patient required ligation of vessels.

Conclusions: Use of feracrylum reduces haemorrhage significantly as compared to that of intra venous tranexemic acid.

Keywords: Tonsillectomy, Feracrylum, Haemorrhage

INTRODUCTION

Tonsillectomy is one of the most common surgeries performed by otolaryngologists. Tonsillectomy is usually performed as an inpatient surgery because of apprehensions with respect to haemorrhage. Haemorrhage, is considered as a severe complication associated with this surgery, around 2–4% of patients suffer from haemorrhage.¹ Haemorrhage in tonsillectomy is classified into two types: primary haemorrhage which occurs within 24 hours and secondary haemorrhage that occurs upto two weeks after surgery.² The most common sequale and complications of tonsillectomy are swallowing disorders, pain, and postoperative haemorrhage, which are potentially life-threatening. Fatal postoperative haemorrhage has been reported to a range between 0.2 and 1.0 per 10,000 performed procedures resulting in an average of 0.9 : 10,000.³

Over the past four decades lot of efforts have been made to minimize the risk of post tonsillectomy haemorrhage in this surgical procedure. Surgical techniques employed to minimise haemorrhage are monopolar and bipolar dissection, CO2 laser, Coblation, and BiClamp. The results of large-scale register studies, audits, and systematic reviews have shown that the hot techniques have proven to carry a higher risk of developing Post tonsillectomy haemorrhage and therefore the cold steel/cold hemostasis technique remains the “gold standard”. On the other hand, a systematic review showed that Post tonsillectomy in children was not affected by the use of either the hot or the cold surgical technique.³

In this study we intend to evaluate the use of gauze soaked in feracrylum with that of i.v. tranexemic acid.

Aims and objectives

To evaluate the efficacy of feracrylum with that of i.v. tranexemic acid in the management of primary haemorrhage in tonsillectomy.

METHODS

40 patients who underwent tonsillectomy in a tertiary care centre from January 2016 to December 2016 were included in this study. They were divided into two groups of 20 patients each. Feracrylum was used to achieve haemostasis in 20 patients and i.v. tranexemic acid in another 20 patients. Dissection and snare method was performed.

Inclusion criteria

Inclusion criteria were age above 5 years; chronic tonsillitis; recurrent attacks of sore throat.

Exclusion criteria

Exclusion criteria were patients with bleeding diathesis; acute exacerbation of chronic tonsillitis; patients undergoing tonsillectomy for quinsy.

RESULTS

Age distribution

4 patients were present in the age group of below 10 years. In the age group of 11-20 years there were 12 patients. In the age group of 21-30 years there were 8 patients. In the age group of 31-40 years there were 13 patients. In the age group of above 40 years there were 3 patients (Table 1).

Table 1: Age distribution.

Age in years	Tranexemic acid (%)	Feracrylum (%)	Total (%)
<10	2 (10)	2 (10)	4 (10)
10-20	4 (20)	8 (40)	12 (30)
21-30	5 (25)	3 (15)	8 (20)
31-40	7 (35)	6 (30)	13 (32.5)
>40	2 (10)	1 (5)	3 (7.5)
Total	20 (100)	20 (100)	40 (100)

Sex distribution

Table 2: Sex distribution.

Gender	Tranexemic acid (%)	Feracrylum (%)	Total (%)
Female	13 (65)	13 (65)	26 (65)
Male	7 (35)	7 (35)	14 (35)
Total	20 (100)	20 (100)	40 (100)

There were 26 female patients and 14 male patients (Table 2).

Primary haemorrhage

Primary haemorrhage was present in 5 patients. P value was 0.02 which was significant (Table 3).

Table 3: Primary haemorrhage.

Primary haemorrhage	Tranexemic acid (%)	Feracrylum (%)	Total (%)
Absent	15 (75)	20 (100)	35 (87.5)
Present	5 (25)	0 (0)	5 (12.5)
Total	20 (100)	20 (100)	40 (100)

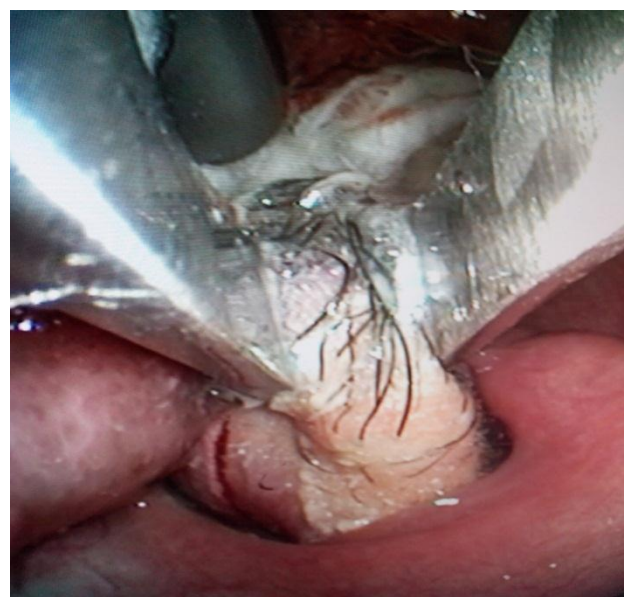


Figure 1: Holding of tonsil.

Bleeding vessels needed ligation in 10 patients (Table 4). P value was less than 0.001 which was also significant. Chi-square test was used.

Table 4: Ligation of vessels.

Ligation of vessels	Tranexemic acid (%)	Feracrylum (%)	Total (%)
Not ligated	10 (50)	20 (100)	30 (75)
Ligated	10 (50)	0 (0)	10 (25)
Total	20 (100)	20 (100)	40 (100)

DISCUSSION

Post-tonsillectomy hemorrhage remains the most critical and even fatal complication of tonsillectomy. Factors, which play a role in haemorrhage are postoperative pain, postoperative course of antibiotics, perioperative medication, obesity and age and gender and these need to be evaluated in the context of the same.²

Hemorrhage following tonsillectomy, which happens to be one of the most common procedures in otolaryngology, remains a challenge because it is potentially life-threatening and need surgical revision for bleeding control in 1% of cases. So many efforts were made to minimize the risk of post tonsillectomy hemorrhage. Primarily, different techniques were adopted to prevent bleeding by achieving proper hemostasis during primary surgery. Bipolar hemostasis and dissection, as well as monopolar dissection, have been used for decades. More recently, lasers, coblation, and harmonic scalpel were utilized for tonsillectomy.³

Tong et al did not report a single case of primary haemorrhage in their study of 90 tonsillectomies.⁴ Robb et al concluded that perioperative use of Tranexemic acid reduces primary haemorrhage.⁵ Clark et al concluded that incidence of post tonsillectomy haemorrhage is more in adults than children.⁶

Feracrylum is an incomplete ferrous salt (II and III) of polyacrylic acid and acts as a topical haemostatic agent, which can be used in control of haemorrhage in various surgical procedures. It also has antimicrobial properties and decreases the postoperative infection. Its mode of action is through activation of thrombin, which subsequently causes conversion of fibrinogen to fibrin eventually leading to clots formation along with that, feracrylum combines with blood proteins, especially albumin and forms a gel-like substance, which in turn forms a physical barrier on wound surface thus stopping capillary bleed and ooze. Feracrylum has molecular weight of 500,000-800,000 Daltons because of which it cannot be absorbed systemically, henceforth has no adverse effects on the liver, kidney, adrenals, cardiovascular and haemopoietic systems.⁷

Tranexemic acid is a synthetic lysine analogue, which produces an antifibrinolytic effect by the reversible blockade of lysine binding sites on plasminogen molecules. This can inhibit the conversion of plasminogen to plasmin on the surface of the fibrin. The drug is widely used parenterally in cardiac, orthopaedic and urological surgery to reduce perioperative blood loss. In orthopaedic surgery, it lessens blood loss during knee arthroplasty by 50%, which in turn reduces the need for transfusion with no increased risk of thromboembolic complications. It has also been used topically as a mouthwash following dental and oral surgery.⁵

Previous studies have not mentioned the use of feracrylum in reducing post tonsillectomy haemorrhage.

CONCLUSION

Use of feracrylum in tonsillectomy reduces the post-operative haemorrhage significantly as compared to that of tranexemic acid. As feracrylum has anti-microbial property it reduces the incidence of secondary haemorrhage also.

Funding: No funding sources

Conflict of interest: None declared

Ethical approval: The study was approved by the Institutional Ethics Committee

REFERENCES

1. Zaher G, Al-Noury K. The Value of Routine Preoperative Testing in the Prediction of Operative Hemorrhage in Adenotonsillectomy. *Indian J Otolaryngol Head Neck Surg.* 2014;66(1):30-6.
2. Lechner M, Chandrasekharan D, Vithlani R, Sutton L, Grandidge C, Elmiyeh B. Evaluation of a newly introduced tonsillectomy operation record for the analysis of regional post-tonsillectomy bleed data: a quality improvement project at the London North West Healthcare NHS Trust. *Brazilian Med J.* 2017;6(2):1-3.
3. Wilhelm T, Wittlinger J, Georgiew R, Güldner C, Hoch S, Teymoortash A, et al. Does Microscope Assistance in Cold Steel Tonsillectomy Reduce the Risk of Postoperative Hemorrhage? Results of a Prospective Cohort Study. *International J Otolaryngol.* 2017;1:1-4.
4. Tong WH, Hui TS, Wee CA. Is daycare tonsillectomy safe. *Iranian J Otorhinolaryngol.* 2016;28(3):183-8.
5. Robb PJ, Thorning G. Perioperative tranexamic acid in day-case paediatric tonsillectomy. *Annals of Royal College Surgeons England.* 2014;96:127-9.
6. Clark MPA, Waddell A. The surgical arrest of post-tonsillectomy haemorrhage: hospital episode statistics. *Annals of Royal College Surgeons England.* 2004;86:411-2.
7. Laddha AK, Mulla M, Sharma SS, Lahoti BK, Mathur R. A prospective comparison of topical feracrylum citrate versus adrenaline as haemostatic agent in hypospadias surgery in children. *Afr J Paediatr Surg.* 2014;11:215-8.

Cite this article as: Sathyaki DC, Roy MS, Vishnu Kumar G, Jyothiswarup R. Use of feracrylum in tonsillectomy. *Int J Otorhinolaryngol Head Neck Surg* 2018;4:663-5.