

## Original Research Article

DOI: <http://dx.doi.org/10.18203/issn.2454-5929.ijohns20181872>

# Endoscopic dacryocystorhinostomy with silicon stent: our experience

Neeraj Suri\*, Bhavya B. M.

Department of ENT, GMERS Medical College and Civil Hospital, Gandhinagar, Gujarat, India

**Received:** 28 February 2018

**Revised:** 26 March 2018

**Accepted:** 27 March 2018

### \*Correspondence:

Dr. Neeraj Suri,

E-mail: [singhn\\_16@yahoo.com](mailto:singhn_16@yahoo.com)

**Copyright:** © the author(s), publisher and licensee Medip Academy. This is an open-access article distributed under the terms of the Creative Commons Attribution Non-Commercial License, which permits unrestricted non-commercial use, distribution, and reproduction in any medium, provided the original work is properly cited.

## ABSTRACT

**Background:** Dacryocystorhinostomy is the current surgical modality of treatment preferred for patients with nasolacrimal duct obstruction. Both external and endonasal endoscopic approaches have been in practice with their own merits and demerits. Since the invention of endoscopes, endoscopic DCR is preferred for its scarless, minimally invasive technique and many modifications have been done over years like placement of silicon stents to reduce recurrence.

**Methods:** In our study we evaluated 70 patients with epiphora with obstruction in nasolacrimal duct, Fresh cases and revision cases who had undergone either external and/ endoscopic DCR without stent were included. All patients underwent endoscopic dacryocystorhinostomy (DCR) with silicon stent placement. Patients were followed postoperatively for a period of 6 months to 3 years.

**Results:** The results were compared with that of external DCR and endoscopic DCR without stent. In our study we found that, endoscopic DCR with silicon stent had less chances of recurrence and synechiae formation. Results at 3 years follow up have been good with 95.7% patients relieved of symptoms completely.

**Conclusions:** Endoscopic DCR is a cost effective and a safe alternative for External DCR in patients with nasolacrimal duct obstruction. We found that endoscopic DCR with stenting had several advantages over more conventional external approach.

**Keywords:** Endoscopic dacryocystorhinostomy, External DCR, Nasolacrimal duct obstruction, Silicon stenting

## INTRODUCTION

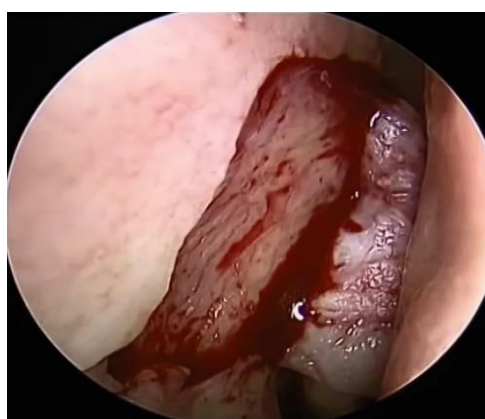Dacryocystorhinostomy is currently the mainstay of treatment of nasolacrimal duct obstruction occurring as a result of chronic dacryocystitis. Both external DCR and endoscopic DCR have been in practice for a long time. Platner in 1724, described the technique of treating chronic dacryocystitis. Toti in 1904, introduced the technique of External DCR for patients with Chronic dacryocystitis.<sup>1</sup> Caldwell was the first to describe intranasal DCR in 1893. Mc Donogh and Meiring described the endoscopic transnasal DCR.<sup>2</sup> The advent of rigid endoscope has awakened the interest in endonasal endoscopic DCR. Endoscopic DCR is a simple,

minimally invasive procedure well tolerated by patients of any age, gives wider exposure of the operating site with good success rate and lesser complications. Since its inception, many modifications have been described by various authors for endonasal endoscopic DCR. Lasers such as Holmium: YAG, Argon, CO<sub>2</sub>, in Endoscopic DCR are also being used by many surgeons.<sup>3,4</sup> Many studies have been carried out, which studied the use of silicon stents placed as a loop in the superior and inferior canaliculi, brought out through the common canaliculi and secured intranasally during endoscopic DCR. With newer advancements success rates of Endoscopic DCR have become at par with external DCR. Besides avoiding the facial scarring and disruption of lacrimal pump mechanism, endoscopic DCR has an additional advantage

of correction concomitant nasal pathologies like deviated nasal septum, hypertrophied turbinates and concha etc, in the same surgical setting.<sup>5</sup> Endoscopic DCR with stenting has several advantages over the classical external DCR, and endoscopic DCR without stents. The aim of this study is to evaluate the role of wide excision of the whole medial wall of the lacrimal sac into the nose by endonasal endoscopic DCR with insertion of silicon stent in patients with epiphora who have failed medical treatment and external DCR.

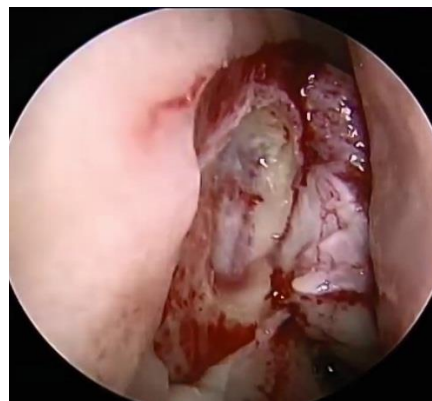
## METHODS

A prospective study was conducted in the Department of ENT, GMERS medical college, Gandhinagar, from January 2013 to December 2017 in 70 patients. All patients were assessed by complete ophthalmic and ENT examinations. In evaluating the patients with dacryocystitis, it is important to take a good clinical history and careful observation. Ophthalmic examination was carried out with emphasis on lacrimal sac and punctum, eyelid, conjunctiva, and cornea status. Palpation of the lacrimal fossa for enlarged lacrimal sac is essential. Mucoid or mucopurulent discharge reflux from the punctum on gentle pressure on the lacrimal sac establishes the diagnosis of chronic dacryocystitis. All patients underwent sac syringing after instilling 4% xylocaine drops in the fornix for 3-5 minutes. Patients who had nasolacrimal duct blockage were selected for this study. Patients were subjected to nasal endoscopy as part of initial examination to look for rhinitis, and other nasal pathologies like polyp, deviated nasal septum, hypertrophied turbinates, concha bullosa, tumour. Patients were also evaluated radiologically with x-ray paranasal sinuses Water's view or computed tomography of paranasal sinuses to look for any sinus pathology or to rule out any eroding or space occupying lesion. Endoscopic DCR was performed by the classical PJ Wormald technique.

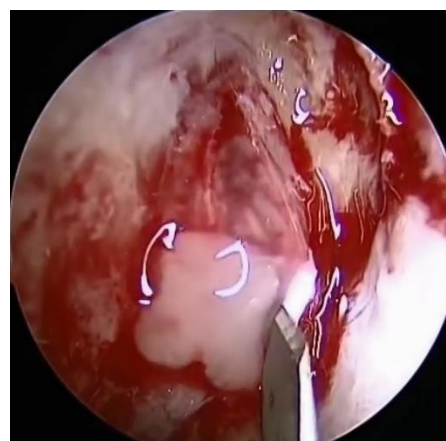


**Figure 1: Exposure of lacrimal crest.**

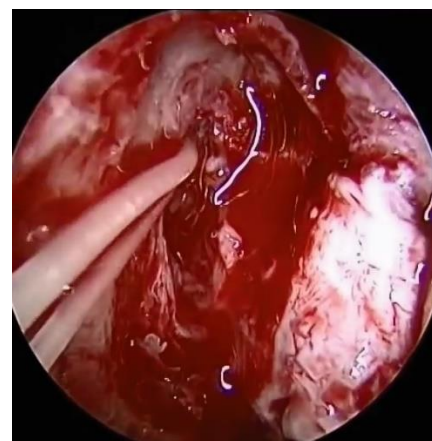
Predisposing nasal conditions like rhinitis and turbinate hypertrophy were treated preoperatively. Other conditions like deviated nasal septum or concha bullosa were treated simultaneously at the time of surgery.



**Figure 2: Exposure of lacrimal sac.**



**Figure 3: Incision of lacrimal sac.**



**Figure 4: Placement of silicon stents.**

All surgeries were done under local anaesthesia after packing the nose with 4% lignocaine and Adrenaline (1:100,000) solution 30 minutes prior to the procedure. This provides mucosal anaesthesia, causes vasoconstriction and bloodless field during surgery

During the procedure, patient was kept in supine position with head slightly turned to right side. Diseased eye of the patient was not covered with drape. Anterior ethmoidal nerve block was given. The area of the lateral

wall of nose anterior and above the axilla of the middle turbinate was infiltrated with 2% lignocaine and 1:100,000 adrenaline solution. 0°, 30° 4 mm endoscopes were used for the procedure. C shaped incision was made with the sickle knife in front of the anterior attachment of the middle turbinate. Posterior based mucoperiosteal flap was elevated using Freer's elevator. Frontal process of maxilla, lacrimal crest and lacrimal bone exposed. The junction between the lacrimal bone and lacrimal crest was identified; lacrimal crest was punched using Kerrison's bone punch. In some patients the thick lacrimal crest bone was drilled using a diamond burr or microdebrider with DCR blade. After widening the bony defect, lacrimal sac was exposed widely (above the axilla of the middle turbinate). Punctum was dilated using punctum dilator. Lacrimal probe was inserted through the punctum into the lacrimal sac and tenting effect on the lacrimal sac caused by the lacrimal probe was confirmed endoscopically. Then a vertical incision was given on the medial wall of the sac, muco-pus was drained. Perpendicular cuts were made over both ends of the vertical incision. Medial wall of lacrimal sac was completely marsupialized care taken not to injure the lateral wall of sac to prevent injury to the common canaliculus opening. Through the superior and inferior punctum, metal ends of the lacrimal intubation set were passed to bring the attached silicon stent through the common canaliculus which was tied in the nose. The mucoperiosteal flap was split into two halves in the centre and was repositioned inferiorly over inferior turbinate. An ointment soaked wick was placed in the operated nose for 24 hours. Postoperatively antibiotic eye drops were started. Patient follow up was done at 1 week post-surgery and every 15 days for next 3 months, then monthly for 6 months and yearly follow up thereafter.

During follow up, suction clearance was done endoscopically, and stoma was checked. Silicon stents were removed after 6-8 weeks. At every follow up sac syringing was done.

## RESULTS

In our study following observations were made. Out of the 70 patients, 43 (61.4%) patients were females and 27 (38.6%) males. Majority of the patients were aged between 30-45 years (Table 1). There were 39 (55.7%) newly diagnosed cases, 16 (22.6%) revision cases who had previously undergone Endoscopic DCR without stenting of which our own cases of revision without stenting were 9 (12.9%), 15 (21.4%) patients had undergone external DCR (Table 2).

We observed that dacryocystitis was more common on the right side as 45 patients (64.3%) had right sided disease, 21 patients (30%) had left sided disease and 4 (5.7%) had bilateral disease. 11 (15.7%) of these patients had deviated nasal septum which was corrected at the time of surgery simultaneously. The common cause of revision was synechiae formation or a small stoma.

**Table 1: Age distribution of cases studied.**

Age	15-30 years	31-45 years	46-60 years
<b>No of cases</b>	28	31	11
<b>Percentage (%)</b>	40	44.3	15.7

**Table 2: Distribution of cases studied.**

	No of cases	Percentage (%)
<b>New cases</b>	39	55.7
<b>Revision endoscopic DCR</b>	16	22.6
<b>External DCR</b>	15	21.4

Follow up period ranged from 6 months to 3 years. Postoperatively we observed adhesions, granulations, crusting in many cases which was addressed with meticulous follow up. 2 (2.9%) patients had stent displacement due to loosening of knots. There were no major complications. 63 patients (95.7%) has complete relief of symptoms at the end of the study. We observed placement of stent and regular follow up will reduce the no. of revision cases.

## DISCUSSION

DCR is a well known standard procedure of choice done for nasolacrimal duct obstruction. With the introduction of endoscopes and lasers, endoscopic DCR has greatly eased the surgical technique improving the outcome and reducing complications. The use of mucosal flaps to form an epithelial lined fistula has improves the success of Endoscopic DCR reducing stoma contraction. The extent of lacrimal sac exposure and size of the ostium are key points that determine long term patency.<sup>6-8</sup>

During this study we observed that failure of Endoscopic DCR especially in cases without stent placement was due to granulations or fibrosis, scarring of stoma, inadequate exposure of the lacrimal sac, damage to the lateral wall of the lacrimal sac causing scarring and impaired canaliculus function. Silicone stent placement can be done for patients with canaliculus obstruction as well.

Tan et al in their study observed that surgical outcome depended on the ostium size and that significant shrinkage of ostium happens in first 4 weeks post-surgery.<sup>9</sup> Wormald, in his study said adequate exposure of the lacrimal sac requires exposure above the level of the axilla of the middle turbinate using a drill to ensure surgical success.<sup>4</sup>

Proper selection of the cases is of paramount importance. Assessment of lid for any scars, atonic sac, ectropion, canaliculitis are important.

Endoscopic DCR with stenting has many advantages as compared to conventional external DCR – avoids facial

scarring, non division of medial canthal ligament, minimal tissue damage, preservation of lacrimal sac pump action, can be performed as a day care procedure under local anaesthesia, reduced operative time, reduced morbidity, simultaneous treatment of other nasal pathologies like deviated nasal septum, cost effective.<sup>10,11</sup>

## CONCLUSION

Endoscopic DCR is a cost effective and a safe alternative for External DCR in patients with nasolacrimal duct obstruction. Success of endoscopic DCR lies in adequate exposure of the sac, wide stoma, meticulous follow up to look for synechiae or granulations and by treating intranasal pathologies simultaneously. Placement of silicon stents maintains the patency of the canalicular function and regular follow up was the reason for the good surgical outcome in our study.

*Funding: No funding sources*

*Conflict of interest: None declared*

*Ethical approval: The study was approved by the Institutional Ethics Committee*

## REFERENCES

1. Priyokumar O, Niteshore MS, Nicola CL, Babu AP. Endonasal DCR without flap and stent (a new technique): our experience in RIMS, Manipur. IOSR J Dent Med Sci. 2014;13(4):50-4.
2. Mc Donogh M, Meiring JH. Endoscopic Transnasal Dacryocystorhinostomy. J Laryngol Otol. 1989;103:585-7.
3. Wormald PJ. Powered Endoscopic Dacryocystorhinostomy. Laryngoscope. 2002;112(1):69-72.
4. Tsirbas A, Wormald PJ. Mechanical endonasal dacryocystorhinostomy with mucosal flaps. Br J Ophthalmol. 2003;87:43-7.
5. Chougule SS, Suligavi SS, Hiremath CS, Doddamani SS. Endoscopic dacryocystorhinostomy: our experience. Clin Rhinol Int J. 2010;3(3):131-3.
6. Ben Simon GJ, Joseph J, Lee S, Schwarcz RM, McCann JD, Goldberg RA, et al. External versus endoscopic dacryocystorhinostomy for acquired nasolacrimal duct obstruction in a tertiary referral centre. Ophthalmology. 2005;112:1463-8.
7. Ramakrishnan VR, Hink EM, Durairaj VD, Kingdom TT. Outcome after endoscopic dacryocystorhinostomy without mucosal flap preservation. Am J Rhinol. 2007;21(6):753-7.
8. Mann BS, Wormald PJ. Endoscopic assessment of the dacryocystorhinostomy ostium after endoscopic surgery. Laryngoscope. 2006;116:1172-4.
9. Tan Neil C, Rajapaksa Suresh P, Gaynor James, Nair Salil B. Mechanical endonasal dacryocystorhinostomy—a reproducible technique. Rhinology. 2009;47:310-5.
10. Weidenbecher M, Hasemeenn W, Buhr W. Endoscopic endonasal dacryocystorhinostomy: results in 56 patients. Ann Otol Rhinol Laryngol. 1994;103:363-7.
11. Hartikainen J, Gernman R, Puukka P, Seppa H. Prospective randomised comparison of external dacryocystorhinostomy. Ophthalmology. 1998;105:1106-13.

**Cite this article as:** Suri N, Bhavya BM. Endoscopic dacryocystorhinostomy with silicon stent: our experience. Int J Otorhinolaryngol Head Neck Surg 2018;4:785-8.