

Original Research Article

A clinical study on paediatric aero digestive foreign body in emergency department

Selvam D. K.¹, Nirmal Kumar J.^{2*}, Anjan Kumar S.², Nagarajan P. S.²

¹Department of ENT Institute of Child Health, ²Upgraded Institute of Otorhinolaryngology, Madras Medical College, Chennai, Tamil Nadu, India

Received: 27 February 2018

Accepted: 15 March 2018

*Correspondence:

Dr. Nirmal Kumar J.,

E-mail: nelurek2003@yahoo.com

Copyright: © the author(s), publisher and licensee Medip Academy. This is an open-access article distributed under the terms of the Creative Commons Attribution Non-Commercial License, which permits unrestricted non-commercial use, distribution, and reproduction in any medium, provided the original work is properly cited.

ABSTRACT

Background: Foreign body ingestion and aspiration is a common clinical condition among the paediatric population. The management of the aero digestive foreign body requires clinical acumen, coupled with the radiological diagnosis and the necessary infrastructure for their management, it demands skill and expertise for removal of a foreign body.

Methods: A retrospective study was carried in the department of Otorhinolaryngology, between December 2016-May 2017, at Institute of Child Health and Hospital for Children, Madras Medical College. 68 cases were analysis of the nature of the foreign body was done. All the patients reported to the emergency department and the ENT surgeon opinion sought with aim of maintaining airway. Clinical assessment, with history, radiographs were obtained to ascertain level and nature of the foreign body and prompt removal by oesophagoscopy/bronchoscopy/direct laryngoscopy under general anaesthesia.

Results: The study of 68 children who reported with history/suspicion of foreign body ingestion/aspiration. There were 32 boys and 36 females, 37 cases of foreign body ingestion and 31 cases of foreign body aspiration. The most common foreign body in digestive tract was coin in 26 cases and peanut in the airway.

Conclusions: Foreign bodies in aero digestive tract in paediatric age group, is a common problem encountered by the otorhinolaryngologist. Careful assessment, clinical evaluation, radiological investigations with effective management in emergency department prompt removal of the foreign body in the aero digestive tract will lead to reduced mortality and morbidity.

Keywords: Paediatric, Foreign body, Aero digestive tract, Clinical study

INTRODUCTION

Foreign body ingestion and aspiration is a common clinical condition among the paediatric population. This clinical scenario is frequently encountered by the paediatricians and ENT surgeons. The management of the aero digestive foreign body requires clinical acumen, coupled with the radiological diagnosis and the necessary infrastructure for their management. The team must comprise of the ENT surgeon, Paediatrician, Paediatric surgeons, anaesthetist and the para medical staffs. Accidents with foreign body are common and the ease of dealing these depends on its location.¹

The foreign body ingestion/aspiration many times goes unnoticed. The history is of important component to understand the nature of foreign body, as most often these accidents are noted by parents, or siblings. The importance of history is that, some foreign bodies in aero digestive tract are sometimes radiolucent often leading to diagnostic dilemma. The foreign body should be effectively managed to prevent complication. Foreign bodies in the air passages is a challenging clinical problem although despite recent advances in anaesthesia and instrumentation, it demands skill and expertise on the part of the surgeon for removal of a foreign body.²

METHODS

A retrospective study was carried in the department of Otorhinolaryngology, between December 2016- May 2017, at Institute of Child Health and Hospital for Children, Madras Medical College. 68 cases were analysis of the nature of the foreign body was done. All the patients reported to the emergency department and the ENT surgeon opinion sought with aim of maintaining airway, medical management with oxygenation, intravenous fluids, antibiotics, steroid, nebulisation as the clinical scenario warrants. Clinical assessment, with history recorded from the care takers. An x-ray neck antero-posterior, lateral views with chest were obtained to ascertain level and nature of the foreign body, after stabilising the patients is shifted to the operation theatre for prompt removal by oesophagoscopy/bronchoscopy/direct laryngoscopy under general anaesthesia for digestive foreign body/jet ventilation for airway foreign body. Statistical analysis of the mean of age group was done.

Inclusion criteria

Inclusion criteria were all children suspected or confirmed cases of ingestion /inhalation of foreign body; age up to 0-12 years; both sexes; foreign body in hypopharynx, trachea, bronchus.

Exclusion criteria

Exclusion criteria were foreign bodies in ear, nose, Oropharynx.

RESULTS

Table 1: Sex of the child.

Male	Female
32	36

Table 2: Location of foreign body.

Digestive tract	Airway
37	31

The study group included 68 children, who reported with history /suspicion of foreign body ingestion/aspiration. There were 32 boys and 36 females in the study group (Table 1). There were 37 cases of foreign body ingestion and 31 cases of foreign body aspiration (Table 2). The average of foreign body ingestion was 5 years and the mean age group for foreign body aspiration was 3.1 years. The most common foreign body in digestive tract was coin in 26 cases, followed by 8 cases of button battery (Table 3, Figures 1, 2). The most common site in the digestive tract was in cricopharynx. The most common foreign body encountered in the airway was peanut in 14 cases, followed by nuts in 5 cases (Table 4,

Figures 3, 4). The most common sites of lodgement was in the bronchus, right main bronchus lodgement in 15 cases, left main bronchus in 15 cases and 1 case in glottis. There was hyper inflation in case of partial obstruction in airway and collapse in complete obstruction of airway (Figure 5, 6). We did not encounter any complications while retrieval of foreign body in digestive tract or airway.

Table 3: Foreign body types in digestive tract.

Type of foreign body	Numbers
Coin	26
Button battery	8
Chicken bone	1
Metal piece	1
Safety pin	1

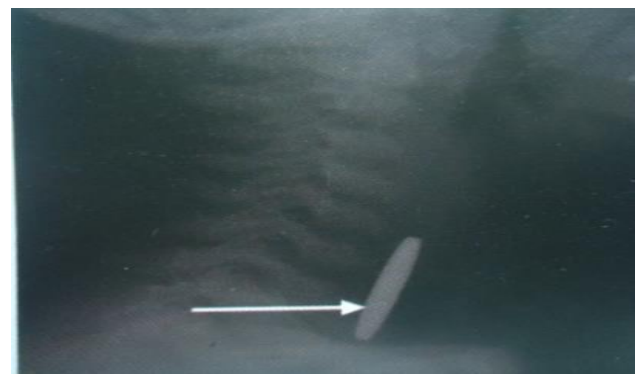


Figure 1: Coin cricopharynx.

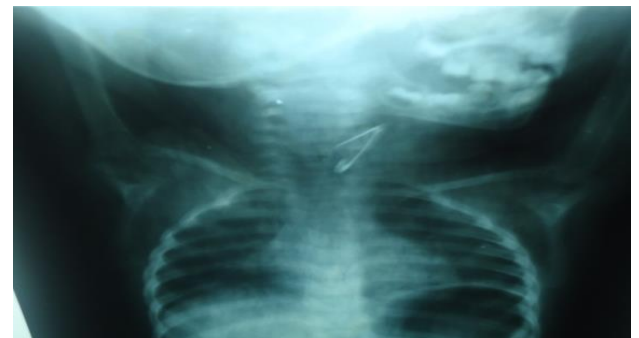

Figure 2: Safety pin cricopharynx.

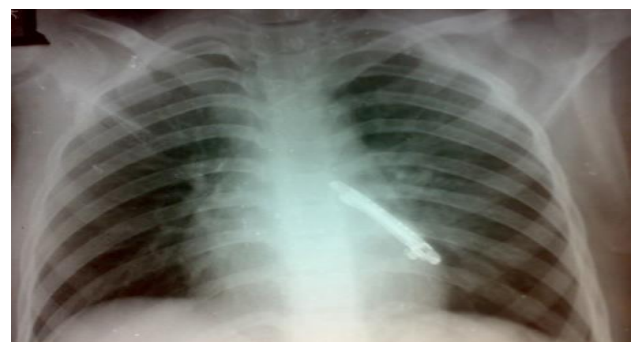

Figure 3: Metal clip left bronchus.

Table 4: Foreign body type in airway.

Type of foreign body	Numbers
Peanut	14
Nuts	5
Tamarind seed	2
Green chilli	1
Pen cap	1
Betul nut	1
Sapotta seed	1
Whistle	1
Safety pin	1
Fish bone	1
Metallic clip	1
Nose stud	1
Paper piece	1

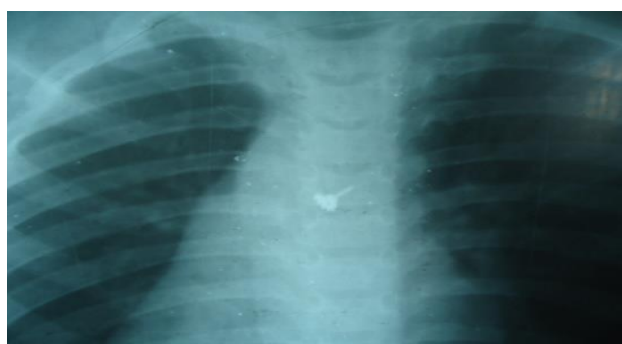

Figure 4: Nose stud right bronchus.

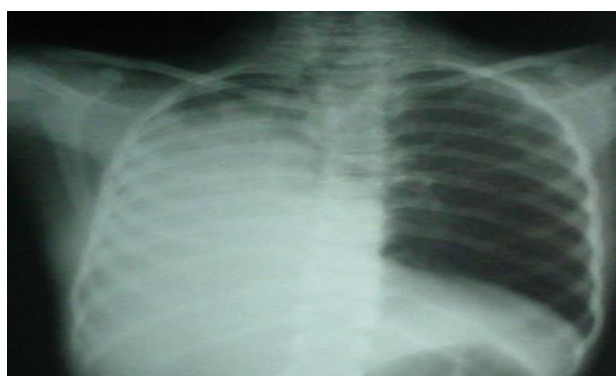


Figure 5: Collapse right lung.

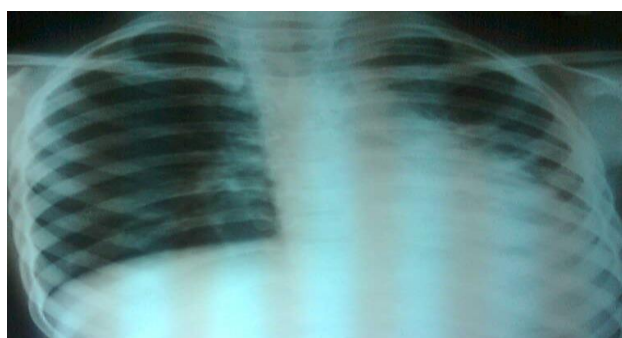


Figure 6: Hyper inflation right lung.

DISCUSSION

The foreign body in the aero digestive tract in children is a perennial problem encountered by otorhinolaryngologist. The diagnosis, management of aero digestive tract in children is a challenge to treating clinician, which has be prompt in retrieval of the foreign body.

In our study of short period of 6 months, which is a tertiary based hospital, 68 cases were diagnosed and it revealed a high frequency of foreign body ingestion/aspiration, in digestive tract/airway of children similar to other studies.³⁻⁵

In our study, we had 37 cases of oesophageal foreign body and 31 cases in airway, in our exclusive study in paediatric age group The study group had 32 male children and 36 female children, differing from other studies, reason due to the short duration of study of 6 months.⁶ The reason which was given in their study was due to the over active nature of the male babies as compared to the females.

Majority of the foreign bodies in digestive tract were radio-opaque, while it was radiolucent with hyper inflation or collapse of lung in airway foreign bodies. There were 26 coins, 8 button battery, 1 each of chicken bone, metal piece, safety pin in digestive tract and nuts (peanut 14 cases, nuts 5 cases, betel nut 1 case) in the airway similar to other studies.⁷ The most common site of lodgement of digestive tract was in cricopharynx, while in airway it was in bronchus, in right main bronchus 15 cases, left main bronchus 15 cases, glottis 1 case. The site of localisation in digestive and airway foreign body were similar to other studies, but difference in our study that there was equal incidence of the lodgement in the both bronchus, can be attributed to the fact that the angulation of the bronchus, occurs after the age of 7 years.⁸⁻¹¹

There was no complication in our study while doing oesophagoscopy/direct laryngoscopy/bronchoscopy, due to the reason that prompt removal of foreign body was done. All our patients were discharged by 3rd post – operative day.

CONCLUSION

Foreign bodies in aero digestive tract in paediatric age group, is a common problem encountered by the otorhinolaryngologist. Careful assessment, clinical evaluation, radiological investigations with effective management in emergency department after stabilising the child and prompt removal of the foreign body in the aero digestive tract will lead to reduced mortality and morbidity. The team work of Paediatricians, anaesthetist, paediatric surgeons (cases where foreign body removal from stomach in cases of button battery in stomach where removal by upper GI endoscopy not available), ENT

surgeons is needed for effective management of aero digestive tract foreign bodies.

Funding: No funding sources

Conflict of interest: None declared

Ethical approval: The study was approved by the Institutional Ethics Committee

REFERENCES

1. Ngo A, Ng KC, Sim TP. Otorhinolaryngeal foreign bodies in children presenting to the emergency department. *Singapore Med J.* 2005;46(40):172-8.
2. Merchant SN, Kirtane MV, Shah KL, Karnik PP. Foreign bodies in the bronchi (a 10 year review of 132 cases). *J Postgrad Med.* 1984;30:219.
3. Hariga I, Khamassi K, Zribi S, Amor MB, Gamra OB, Mbarek C, Khedim AE. Management of Foreign Bodies in the Aerodigestive Tract. *Indian J Otolaryngol Head Neck Surg.* 2014;(66):220-4.
4. Hsu WC, Sheen TS, Lin CD, Tan CT, Yeh TH, Lee SY. Clinical experiences of removing foreign bodies in the airway and oesophagus with rigid endoscope: a series of 3217 cases from 1970 to 1996. *Otolaryngol Head Neck Surg.* 2000;122:450-4.
5. Higo R, Matsumoto T, Ichimura K, Kaga K. Foreign bodies in the aerodigestive tract in Pediatric patients. *Auris Nasus Larynx.* 2003;30:397-401.
6. Hussain G, Iqbal M, Khan SA, Iqbal M, Zaman J. An Experience Of 42 Cases Of Bronchoscopy At Saudi Group Of Teaching Hospitals, Swat. *J Ayub Med Coll Abbottabad.* 2006;18(3):59-62.
7. Hughes CA, Baroody FM, Marsh BR. Paediatric tracheo-bronchial foreign bodies: historic review from the John Hopkins Hospital. *Ann Otol Rhino Laryngol.* 1996;105:555-61.
8. Li ZS, Sun ZX, Zou DW, Xu GM, Wu RP, Liao Z. Endoscopic management of the foreign bodies in the upper GI Tract: experience with 1088 cases in China. *Gastrointest Endosc.* 2006;64:485-92.
9. Little JS, Shah SR, St Peter SD, Calkins CM, Morrow SE, Murphy JP, et al. Oesophageal foreign bodies in the pediatric population: our first 500 cases. *J Pediatr Surg.* 2006;41:914-8.
10. Fenneria H, Ben Slimene D, Bourguiba M et al. Corpus e'strangers trache'o-bronchiques de l'enfant. Aspects diagnostiques et ther'apeutiques. *Tun Med.* 2004;82:817-26.
11. Ozguner IF, Buyukyavuz BI, Savas C, Yavuz MS, Okutan H. Clinical experience of removing aerodigestive tract foreign bodies with rigid endoscopy in children. *Pediatr Emerg care.* 2004;20:671-3.

Cite this article as: Selvam DK, Nirmal Kumar J, Anjan Kumar S, Nagarajan PS. A clinical study on paediatric aero digestive foreign body in emergency department. *Int J Otorhinolaryngol Head Neck Surg* 2018;4:682-5.