

Case Report

Unusual foreign body in the upper digestive tract: case report

Snigdha Elaprolu, Gowri Sankar Marimuthu*, Raghul Sekar, Sunil Kumar Saxena

Department of ENT, Jawaharlal Institute Postgraduate Medical Education and Research (JIPMER), Pondicherry, India

Received: 16 February 2018

Accepted: 26 March 2018

***Correspondence:**

Dr. Gowri Sankar Marimuthu,

E-mail: drent5555@gmail.com

Copyright: © the author(s), publisher and licensee Medip Academy. This is an open-access article distributed under the terms of the Creative Commons Attribution Non-Commercial License, which permits unrestricted non-commercial use, distribution, and reproduction in any medium, provided the original work is properly cited.

ABSTRACT

Unusual foreign bodies in the digestive tract are common in psychiatric patients and children requiring screening of the entire gastrointestinal tract. We here report two cases of unusual ingested blunt foreign body in the upper digestive tract managed differently.

Keywords: Blunt foreign body, Upper digestive tract, Esophagoscopy

INTRODUCTION

Swallowed foreign bodies are a common problem and considered as serious causes of morbidity and mortality, classically presenting with dysphagia. Radiological localization is mandatory for decision making regarding removal.¹ Sharp or pointed foreign bodies if not retrieved at the earliest may penetrate the esophageal wall causing complications, while smooth foreign bodies do not pose much threat to the patient, but may create a challenge in the process of removal due to difficulty in gripping the foreign body, especially if the foreign is large with a slippery surface. We here report two cases of unusual ingested blunt foreign body in the upper digestive tract managed differently, aiming to highlight their peculiarities and various methods of management of blunt foreign body in the upper digestive tract.

CASE 1

A 30 year old male, known case of psychiatric disorder – paranoid schizophrenia on irregular medications presented with complains of dysphagia following ingestion of a foreign body. The patient was psychologically stable. On examination- indirect laryngoscopy showed Jackson's sign bilaterally. Plain X-ray neck showed a radio-opaque pear shaped foreign

body in the left pyriform fossa (Figure 1). X ray chest, abdomen and pelvis was within normal limits.

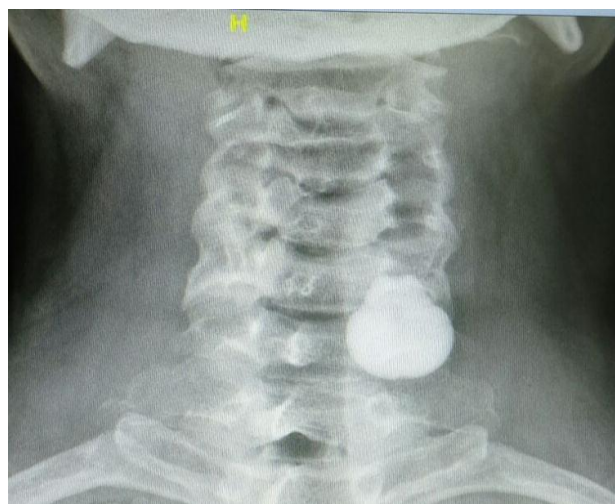

Figure 1: Plain x-ray soft tissue neck AP view showing pear shaped radiopaque foreign body in left pyriform fossa region.

The patient was taken up for foreign body removal under general anesthesia, a hypopharyngoscope was introduced, the foreign body was visualized in left pyriform fossa and

was removed with large foreign body removal forceps. The foreign body was a pear shaped smooth surfaced-“pebble” -measuring 3×1.5 cm (Figure 2). Postoperative period was uneventful and he was discharged the next day after psychiatric counseling.

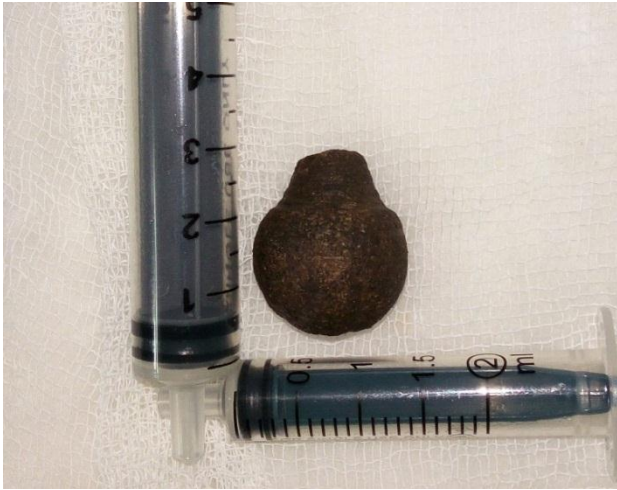

Figure 2: Recovered foreign body - 3×1.5 cm in case 1.

CASE 2

A 10 year old child presented 6 hours after accidental ingestion of a marble complaining of difficulty in swallowing and throat pain. On evaluation, X-ray soft tissue neck showed radiopaque elliptical foreign body in esophagus at T1 level (Figure 3). Child was posted for rigid esophagoscopy and foreign body removal under general anesthesia.

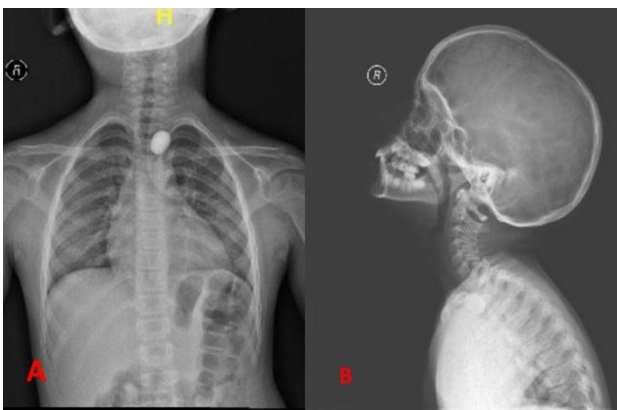


Figure 3: (A) X-ray soft tissue neck AP view; (B) Lateral view showing radiopaque oval shaped foreign body (marble) in esophagus at T1 level.

On esophagoscopy, difficulty was encountered in gripping the foreign body owing to the large size, smooth and slippery surface of the marble. The foreign body was pushed with an esophageal bougie through the lower esophageal sphincter into the gastric region expecting a natural passage out. Child passed out the foreign body (in stool) on postoperative day one.

DISCUSSION

The factors responsible for foreign body impaction in the digestive tract are carelessness of parents (in case of children), poor vision, mental infirmity, drug addiction, rapid eating while on dentures, excessive alcohol ingestion and intake of markedly cold fluids. Foreign bodies less than 2.5 cm in diameter and/or <5 cm in length usually pass through whole gut.² The sites of impaction of foreign bodies in esophagus are post cricoid region (commonest 80%), level of aortic arch, left main bronchus and diaphragm.³ The foreign body encountered in children are coins(commonest), buttons, marbles, crayons, parts of toys etc, while fish bone, meat and chicken bones, dentures, nails etc. are the most common foreign bodies ingested by adults.⁴⁻⁹ Majority of the foreign bodies are radio-opaque, and requires radiological screening the entire gastro-intestinal tract particularly in children and psychiatric patient for detection of multiple foreign body.

Blunt foreign bodies can be removed safely from esophagus without any major complications.¹⁰ However they cause erosions if present for a long time, or may pose a challenge during removal of the foreign body particularly if they are large and smooth surfaced which are expected to have a poor grip with forceps due to their size and slippery nature (with added secretions). Fortunately, we didn't experience any difficulty in removal of the foreign body as it was pear shaped, especially the narrow end being up, helped us in easy removal. We would have encountered a difficulty if the foreign body was inverted.

Rigid oesophagoscopy is routinely used as an effective tool to remove foreign body. Alternate techniques have been advocated for removal of blunt foreign bodies. The most popular being the use of Foley's catheter to extract foreign body under fluoroscopy.¹¹ The others techniques being pushing the foreign body into the stomach with a bougie and intravenous glucagon as a method of treatment for esophageal meat impaction has been tried.^{12,13} The effect of glucagon is thought to be secondary to relaxation of oesophageal and oesophagogastric junction smooth muscles. When it fails, oesophagoscopy has to be performed within 6 hours.¹³

CONCLUSION

Unusual foreign bodies in the digestive tract are common in psychiatric patients and require screening of the entire gastro intestinal tract. Technique of removal may be customized for each individual case pertaining to difficulty in removal for few blunt foreign bodies.

Funding: No funding sources

Conflict of interest: None declared

Ethical approval: Not required

REFERENCES

1. Marcon NE. Overtubes and foreign bodies. *Can J Gastroenterol.* 1990;4:599-602.
2. Shivakumar AM, Naik AS, Prashanth KB, Hongal GF, Chaturvedy G. A, Foreign bodies in Upper digestive tract. *Indian J Otolaryngol Head Neck Surg.* 2006;58(1):63-8.
3. Han S, Kayhan B, Dural K, Kocer B, Sakinci U. A new and safe technique for removing cervical esophageal foreign body. *Turk J Gastroenterol.* 2009;16(2):108-10.
4. Wyllie R. Foreign bodies in the gastrointestinal tract. *Curr Opin Pediatr.* 2006;18(5):563-4.
5. Schunk JE, Harrison AM, Cornelli HM, Nixon GW. Fluoroscopic foley's catheter removal of esophageal foreign bodies in children: experience with 415 episodes. *Pediatrics.* 1994;94(5):709-14.
6. Seo JK. Endoscopic management of gastrointestinal foreign bodies in children. *Indian J Pediatr.* 1999;66(1):s75-s80.
7. Hachimi-Idrissi S, Come L, Vandenplas Y. Management of ingested foreign bodies in childhood: Our experience and review of the literature. *Eur J Emerg Med.* 1998;5(3):319-23.
8. Wu WT, Chiu CT, Kuo CJ, Lin CJ, Chu YY, Tsou YK, et al. Endoscopic management of suspected esophageal foreign body in adults. *Dis Esophagus.* 2011;24(1):131-7.
9. Gausam V, Phillips J, Bowmer H, Reichl M. Foreign body in the throat. *J Accid Emerg Med.* 1994;11(3):113-5.
10. Hawkins D. Removal of blunt foreign bodies from the esophagus. *Ann Otol Rhinol Laryngol.* 1990;99:935-40.
11. Campbell JB, Condon VR. Catheter removal of blunt esophageal foreign bodies in children: Survey of the Society for pediatric radiology. *Pediatr Radiol.* 1989;19:361-5.
12. Bonadio WA, Jona JZ, Glicklich M, Cohen R. Esophageal bouginage technique for coin ingestion in children. *J Pediatr Surg.* 1988;23:917-8.
13. Ferrucci JT, Long JA. Radiologic treatment of esophageal food impaction using intravenous glucagons. *Radiology.* 1977;125:25-8.

Cite this article as: Elaprolu S, Marimuthu GS, Sekar R, Saxena SK. Unusual foreign body in the upper digestive tract: case report. *Int J Otorhinolaryngol Head Neck Surg* 2018;4:850-2.