

Research Article

Tonsillostyloidectomy for Eagle's syndrome: a study of 20 cases

Roohie Singh^{1*}, Jeevan R. Galagali²

¹Department of ENT, Military Hospital, Jodhpur, Rajasthan, India

²Department of ENT & HNS, Command Hospital, Pune, Maharashtra, India

Received: 22 November 2015

Accepted: 05 December 2015

*Correspondence:

Dr. Roohie Singh,

E-mail: roohiesingh@yahoo.in

Copyright: © the author(s), publisher and licensee Medip Academy. This is an open-access article distributed under the terms of the Creative Commons Attribution Non-Commercial License, which permits unrestricted non-commercial use, distribution, and reproduction in any medium, provided the original work is properly cited.

ABSTRACT

Background: Eagle's syndrome is a pain syndrome which occurs due to elongated and misdirected styloid process. It is commoner than generally thought.

Methods: 20 cases of styalgia were diagnosed and prospectively studied at two hospitals. The characteristic symptoms were chronic throat pain and foreign body sensation in throat. Diagnosis was made with clinical symptoms, physical examination in form of intraoral palpation of styloid and radiological correlation. All patients underwent Tonsillostyloidectomy for affected sites under General anaesthesia. The patients were followed up for 12 weeks post-operatively and relief of symptoms was noted.

Results: Chronic throat pain was the commonest symptom. Most cases were associated with chronic tonsillitis or Laryngopharyngeal reflux disease (LPRD). 19 (95%) patients were symptom free by 4 weeks postoperatively.

Conclusions: In an established case of Styalgia with intraoral palpable styloid tip, tonsillostyloidectomy by intra-oral approach gives good results. Also, LPRD may be a possible aetiology of the disease. Incidentally, it was found that position of head over neck should be intraoperatively adjusted in order to suit easy approach to the styloid depending on antero-posterior angulation of styloid.

Keywords: Eagle's syndrome, Misdirected, Styalgia, Styloid process, Tonsillostyloidectomy

INTRODUCTION

Pain in head and neck can be a diagnostic dilemma for the treating doctor and frustrating for the patient. The diagnosis at times becomes difficult due to overlap of similar pain syndromes. Such patients usually have received a variety of treatment en route while undergoing treatment through multiple specialists like neurologists, dental surgeons, otolaryngologists and even psychiatrists. These further clouds up the diagnosis.

Eagle's syndrome or styalgia was first described by W Watt Eagle in 1937 as a pain syndrome which occurs due to elongation and/or ossification of styloid process and/or stylohyoid ligament impinging on local neurovascular structures.¹ The incidence of elongated styloid process is

4% but only a small percentage (4 - 10.3%) of this group is actually symptomatic.²⁻⁴ Thot et al stressed that length in combination with increased anterior and/or medial angulation from norm makes it symptomatic.⁵

Though there can be wide spectrum of symptoms, commonest is chronic throat pain. Eagle identified two types of syndrome complexes. 'Classical' variety presents as throat pain, referred otalgia and foreign body sensation in throat. A second variety is 'Carotid artery' type presenting as carotidynia, headache, facial pain and dizziness.^{1,6,7}

Genetic predisposition, trauma, early onset of menopause, post tonsillectomy local stretching and scarring resulting in tendinosis of insertion of stylohyoid ligament and many more causes have been postulated as

possible aetiology for styalgia. But a robust cause is still not confirmed.⁸

In the presence of clinical symptoms, diagnosis can be made by gloved digital palpation of styloid process in tonsillar fossa on the affected side which is felt as sharp pick which elicits similar pain.^{8,9} The pain subsides on lidocaine infiltration over anterior pillar.¹¹ This can be further correlated with radiological examination in form of Orthopantogram (OPG) or plain radiographs which are relatively cheaper than Computed Tomography (CT) imaging. CT scan with 3 D reconstruction is the most valuable method for establishing diagnosis and laying treatment plan.¹²

Appropriate treatment is based on severity of symptoms. Temporary relief is possible by conservative management which includes physiotherapy, anti-inflammatory drugs, anticonvulsants, antidepressants and local infiltration of anaesthetics/ corticosteroids in tonsillar fossa.¹³

A styloidectomy under General anaesthesia is treatment of choice which can be done by intra or extra-oral approach. If tip of styloid is palpable in tonsillar fossa, an intraoral approach is acceptable. External approach suffices in case of extremely long styloid process.¹⁴

The study has been undertaken to evaluate efficacy of surgical outcome in treating styalgia with a special reference to positioning of head over neck in order to conveniently approach the styloid. Associated co-existent diseases were also noted in order to support the postulated etiology.

METHODS

It was a prospective study carried out in two hospitals. 20 patients with symptoms of Styalgia not responding to conservative management were recruited in the study. They presented with chronic throat pain radiating to neck, jaw and ear. Some had foreign body sensation in throat and some presented with tinnitus. Symptoms aggravated on swallowing or turning of head to affected side.

A comprehensive evaluation of these patients was undertaken including age, gender, relevant history including co-existent diseases like chronic tonsillitis, Laryngopharyngeal reflux disease (LPRD), Oral Submucous fibrosis (OSMF), Trismus and menopause.

Diagnosis was confirmed by gloved finger palpation of styloid in tonsillar fossa on affected side which reproduced similar pain. It subsided on local infiltration of 2% lignocaine in tonsillar fossa. It was further correlated with an Orthopantogram (OPG) (Figure 1A) or X-ray skull Antero-posterior view (Figure 1B). In few patients who presented with 'Carotid artery' type symptoms, 3D CT of skull base with reconstruction was advised in order to assess proximity of great vessels to styloid process (Figure 2).

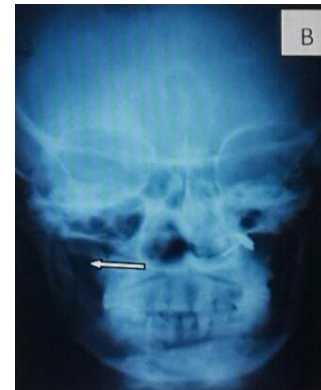
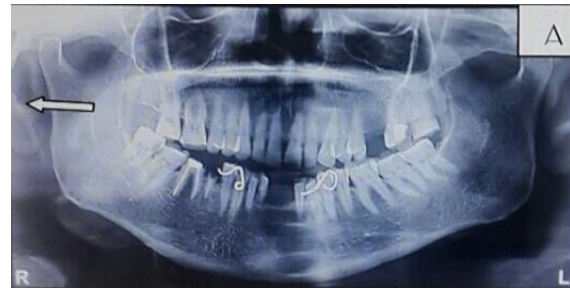

Figure 1: Orthopantogram (a) and x-ray skull anteroposterior view (b) showing elongated styloid (arrow).

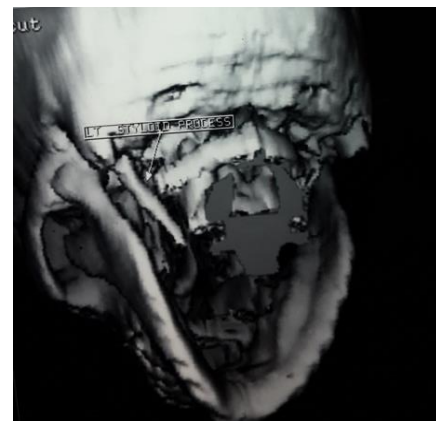


Figure 2: 3 D - CT scan with reconstruction.

All patients were given 2 weeks of conservative treatment with anti-inflammatory drugs to rule out tendonitis or myositis. Surgery in form of Tonsillostyloidectomy under General anaesthesia was proposed to all such patients.

Surgical procedure

In Rose Position, tonsillectomy (Dissection snare cautery) was done. After removal of tonsil, sharp styloid tip was palpated and overlying superior constrictor fibres were separated to expose it (Figure 3). The soft tissue attachment of styloid was stripped off and with help of long heavy duty sturdy curved artery forceps, styloid was grasped, mobilized, broken as close to base of skull as possible and removed (Figure 4). The remnant part of

styloid was smoothened with help of rasp. After confirming hemostasis, 2-0 vicryl was used to approximate separated fibres of superior constrictor muscle so that no dead space remains (Figure 5). The procedure was repeated on opposite side in bilateral cases. All patients were discharged in 3-4 days and advised oral antibiotics and anti-inflammatory along with antacids and prokinetics. Patients were followed up at 1 week, 2 weeks, 4 weeks and 12 weeks.

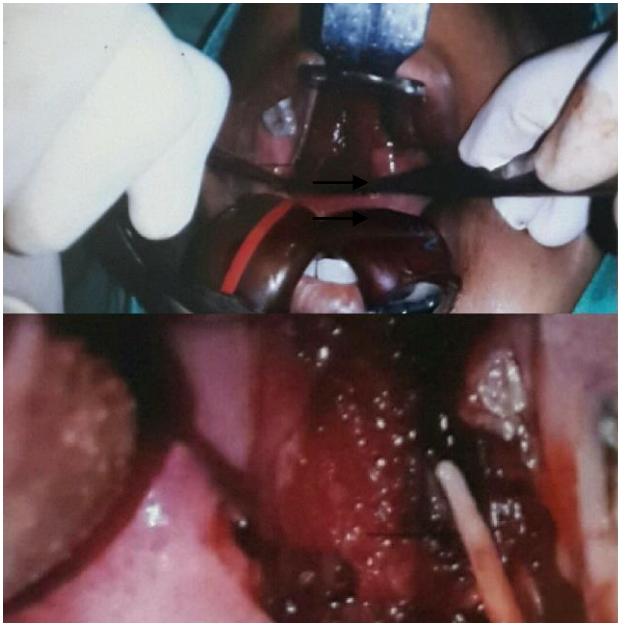

Figure 3: Bilateral styloid processes in tonsillar fossa (arrow).

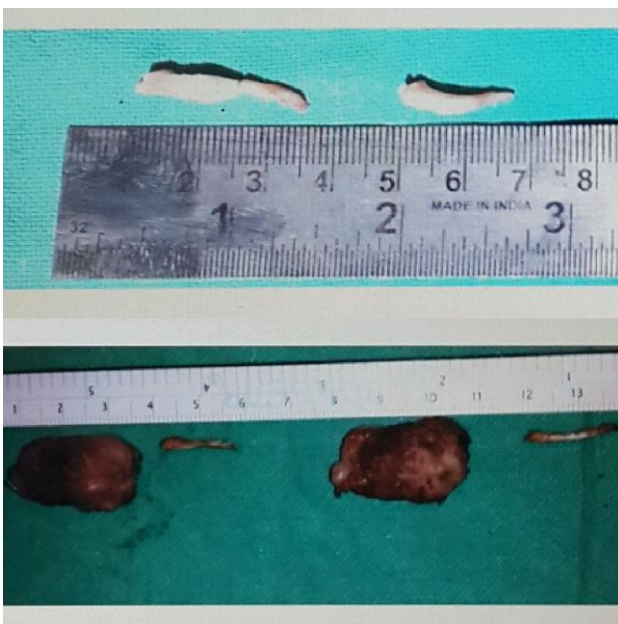

Figure 4: Tonsillostyloidectomy specimens.

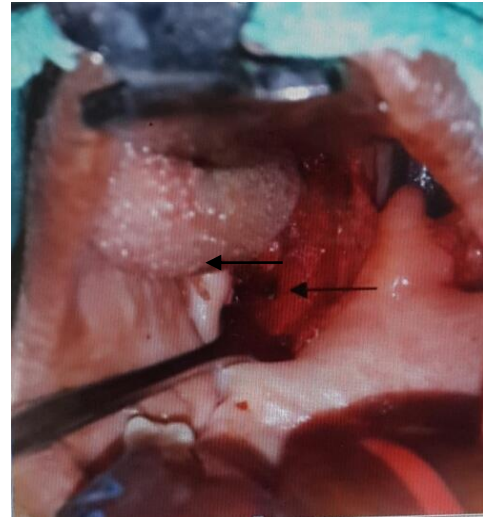

Figure 5: Sutures applied to superior constrictor fibres (arrow).

RESULTS

There were 30 symptomatic styloids in 20 patients. There were 8 male and 12 female patients. Of these, 9 patients had bilateral and 11 had unilateral stygia on presentation. Amongst the 11 unilateral cases, one male patient underwent unilateral tonsillostyloidectomy but in two separate sittings at interval of 4 months, since he was symptomatic only on one side in initial presentation. Majority of patients were in age groups of 31 to 50 yrs. Youngest patient was of age 24 years and eldest of 64 years (Table 1).

Table 1: Age wise sex distribution of patients.

| | Group (yrs) | | | Age | |
|--------|-------------|-------|-------|-------|-------|
| | 21-30 | 31-40 | 41-50 | 51-60 | 61-70 |
| Male | 4 | 3 | 1 | 0 | 0 |
| Female | 0 | 5 | 3 | 2 | 2 |

The longest styloid removed was of length 3.7 cm and shortest 1.5 cm. There was difficulty in locating styloid intra-operatively in 8 styloids. In all such cases, the styloids were directed anteriorly.

In this study, 17 (85%) patients presented with chronic throat pain, 15 (75%) patients had aggravation of symptoms on swallowing, 14 (70%) presented with foreign body sensation, 12 (60%) presented with referred pain in ear and jaw and 2 (10%) patients presented with only tinnitus.

Of the coexistence diseases, 12 (60%) were noted to have chronic tonsillitis, 8 (40%) had LPRD, 7 (35%) had OSMF and 1 (5%) had trismus. Among 12 female patients, 5 were perimenopausal (Table 1).

After surgery, 10 (50%) pts were symptom free at 1 week, 16(80%) at 2 weeks and 19 (95%) at 4 weeks.

patient did not get relief even at 12 weeks post-operatively and was advised oral carbamazepine for pain (Table 2).

Table 2: Post Operative follow up of patients.

| | 1 week | 2 weeks | 4 weeks | 12 weeks |
|--------------|-----------|------------|------------|-------------|
| Symptom Free | 10 | 16 | 19 | 19 |
| Symptomatic | 10 | 04 | 01 | 01 |

DISCUSSION

Eagle's Syndrome is a definite clinical entity caused by increased length and anterior angulation of styloid process. It was noted that patients with long styloid process and those with misdirected angulation presented with maximum symptoms. Naik et al showed similar result.¹⁵

In anteriorly angulated styloids, care was taken to maneuver position of the patient intraoperatively. The usual amount of extension of head over neck was decreased which rendered styloid processes palpable and accessible.

The irritation of a number of neurovascular structures coursing through parapharyngeal space results in throatpain. Chronic throatpain and aggravation of symptoms on swallowing were the two main symptoms in this study. This is comparable with findings of Maru et al.^[16] and Haluk.¹⁷

In our study, chronic tonsillitis, LPRD and menopause were found to be significantly co-existent with styalgia and thus support the postulated etiological factors for the disease. No patient had earlier tonsillectomy on affected side. This is comparable to studies by Eagle and many other studies.^{2,8}

Tonsillostyloidectomy in 95% of Styalgia cases provided with excellent relief at 4weeks postoperatively. These observations are comparable to other studies.¹⁵⁻¹⁷

CONCLUSION

In summary, in an established case of Eagle's syndrome, tonsillostyloidectomy is a promising treatment of choice. Hence, awareness of this syndrome is important to all health practitioners.

Funding: No funding sources

Conflict of interest: None declared

Ethical approval: The study was approved by the Institutional Ethics Committee

REFERENCES

1. Eagle WW. Elongated styloid process. Report of two cases. Arch Otolaryngol. 1937;25:584-7.
2. Corell RW, Jensen JL, Taylor JB, Rhyne RR. Mineralization of the styloid-stylomandibular ligament complex. Oral Surg Oral Med Oral Pathol. 1979;48:286-91.
3. Eagle WW. Elongated styloid process. Arch Otolaryngol. 1948;47:639-40.
4. Kaufman SM, Elzay RP, Irish EF. Styloid process variation: radiological and clinical study. Arch Otolaryngol. 1970;91:460-3.
5. Thot B, Revel S, Mohandas R, Rao AV, Kumar A. Eagle Syndrome. Anatomy of the styloid process. Indian J Dent Res. 2000;11:65-70.
6. Eagle WW. Elongated styloid process; symptoms and treatment. AMA Arch Otolaryngol. 1958;67(2):172-6.
7. Eagle WW. The symptoms, diagnosis and treatment of the elongated styloid process. Am Surg. 1962;28:1-5.
8. Zeckler SR, Betancur AG, Yaniv G. The eagle is landing: Eagle syndrome-an important differential diagnosis. Br J Gen Pract. 2012;62(602):501-2.
9. Beder E, Ozgursoy OB, Ozgursoy SK. Current diagnosis and transoral surgical treatment of Eagle's syndrome. J Oral Maxillofac Surg. 2005;63:1742-5.
10. Strauss M, Zohar Y, Haurian N. Elongated styloid process syndrome: intraoral versus extraoral approach for styloid surgery. Laryngoscope. 1985;95:976-9.
11. Prasad KC, Kamath MP, Reddy KJM, Raju K, Agarwal S. Elongated styloid process (Eagle's Syndrome): a clinical study. J Oral Maxillofac Surg. 2002;60:171-5.
12. Nayak DR, Pujary K, Aggrawal M, Punnoose SE, Chaly VA. Role of three-dimensional computed tomography reconstruction in management of elongated styloid process: a preliminary study. J Laryngol Otol. 2007;121(4):349-53.
13. Hoffmann E, Rader C, Fuhrmann H, Maurer P. Styloid-carotid artery syndrome treated surgically with Piezosurgery: A case report and literature review. Journal of Cranio-Maxillo-Facial Surgery. 2013;41:162-6.
14. Diamond LH, Cottrell DA, Hunter MJ, Papageorge M. Eagle's syndrome: a report of 4 patients treated using modified extraoral approach. J Oral Maxillofac Surg. 2001;59(12):1420-6.
15. Naik SM, Naik SS. Tonsillo-Styloidectomy for Eagle's Syndrome: A Review of 15 cases in KVG Medical College Sullia. Oman Med J. 2011;26920:122-6.
16. Maru YK, Patidar K. Styalgia and its surgical management by intra oral route- clinical experience of 332 cases. Indian Journal of Otolaryngology and Head and Neck Surgery. 2003;55(2):87-90.
17. Yavuz H, Caylakli F, Yildirim T, Ozluoglu LN. Angulation of the styloid process in Eagle's syndrome. Eur Arch Otorhinolaryngol. 2008;265:1393-6.

Cite this article as: Singh R, Galagali JR.

Tonsillostyloidectomy for Eagle's syndrome: a study of 20 cases. Int J Otorhinolaryngol Head Neck Surg 2016;2:22-5.