

Original Research Article

Diagnosis and management of radio opaque nasal foreign bodies in children

Satish Kumar P.¹, Vikram V. J.^{2*}, Mannarmannan N.², Bhavani R.²

¹Department of ENT, Institute of Child Health, ²Upgraded Institute Of Otorhinolaryngology, Madras Medical College, Chennai, Tamil Nadu, India

Received: 15 January 2018

Revised: 08 February 2018

Accepted: 10 February 2018

***Correspondence:**

Dr. Vikram V. J.,

E-mail: dr.vjvikram@gmail.com

Copyright: © the author(s), publisher and licensee Medip Academy. This is an open-access article distributed under the terms of the Creative Commons Attribution Non-Commercial License, which permits unrestricted non-commercial use, distribution, and reproduction in any medium, provided the original work is properly cited.

ABSTRACT

Background: Nasal foreign body impaction is a common problem in paediatric population. Children are more affected because they have tendency to put anything in the nose or by their playmates. This study is about the various radio opaque nasal foreign bodies we encountered and their management.

Methods: A retrospective study between January 2013 - January 2015, at Institute of child health/Madras Medical College, Chennai, was done in paediatric patients, who have accidentally inserted the radio opaque foreign body in their nostrils. The case record were analysed for the nature of radio opaque nasal foreign body, the symptoms, complications encountered.

Results: There were 11 patients with radio opaque foreign body in our study. The most common age group was between 1 to 5 years 7 patients were in this age group. The type of foreign was button battery were 5 in number, safety pins 4, marble 1, bolt 1. All the patients were brought to hospital within 4 hours of insertion. We did not encounter any complications while removal of the nasal foreign bodies.

Conclusions: Nasal foreign bodies are a common problem among children's. The foreign body retrieval can be posing a great challenge to the otorhinolaryngologists. The radio opaque foreign body especially button battery, if not removed may lead to serious complications like septal perforation.

Keywords: Nasal foreign bodies, Radio opaque, Children

INTRODUCTION

Nasal foreign body impaction is a common problem in paediatric population. Highest incidence of nasal foreign bodies is seen in the age group of 2 to 4 years. Children are more affected as they have tendency to put anything in the nose or by their playmates.¹ Nasal foreign bodies are typically discovered around the floor of the nose below the inferior turbinate and another common location is immediately anterior to the middle turbinate.²

These objects are generally placed by children or mentally retarded patients whose curiosity leads them to explore body orifices. Foreign bodies in the nasal cavity, can be a great challenge and their management require great skill.³ Any article enough to be admitted into the nasal orifice has, at one time or the other, been removed from the nose.^{3,4} Nasal cavity foreign bodies usually go unnoticed until the child develops, an unilateral foul smell nasal discharge.^{5,6} Otorhinolaryngologist encounters different types of nasal foreign bodies ranging

from seed, paper, beads, beans, foam, screws, safety pin, button battery of toys or wrist watches.

X-rays are usually diagnostic for radiopaque foreign bodies. Several techniques has been described for removing nasal foreign bodies. Removal is often done by curved right angel hook, suction or Foley’s catheter.⁷ Nasal endoscope is a good tool for diagnosis and management of foreign bodies in nose. The objective of this article is about discussion on different types of nasal foreign bodies, their presentation, management, complications.

METHODS

A retrospective study between January 2013- January 2015, at Institute of child health/Madras Medical College, Chennai, was done on radio opaque foreign body removal in nostril of the paediatric patients, who have accidentally inserted the radio opaque foreign body in their nostrils. The case record were analysed for the nature of radio opaque nasal foreign body, the symptoms, complications encountered. The statistical analysis of the mean age group is done.

Inclusion criteria

Inclusion criteria were patients with nasal foreign body; radio opaque in X-ray nose; age up to 12 years.

Exclusion criteria

Exclusion criteria were patients with non-radio opaque nasal foreign body such as beads, seeds, stick piece, sticker, paper, foam paper, thermocol; radio opaque foreign body in ear, throat, bronchus; more than 12 years.

RESULTS

There were 11 patients with radio opaque foreign body in our study. The most common age group was between 1 to 5 years 7 patients were in this age group (Table 1). The mean age group was 3.5 years. The type of foreign was button battery were 5 in number, safety pins 4, marble 1, bolt 1 (Table 2). All the patients were brought to hospital within 4 hours of insertion. The method of removal was endoscopic removal of foreign body under general anaesthesia in 10 cases, while 1 safety pin was removed in outpatient department. In 3 patients of button battery black slough was present in the nose making it difficult to visualise and remove foreign body because of local tissue reaction. After removal of button battery the children will be monitored for further tissue reactions and normal saline drops will be instilled with antibiotic coverage and discharged from hospital with weekly follow up in ENT outpatient department.

Safety pin removal did not pose any difficulty as it was closed and no pointing end to tear or puncture the tissues. The retrieval of marble stone was difficult, it slipped in to oro-pharynx and removed per oral (Figures 1-5). We did

not encounter any complications while removal of the nasal foreign bodies.

Table 1: Age group with number of cases.

Age group	Number of patients
Less than one year	1
1 year to 5 years	7
5 to 12 years	3

Table 2: Types of radio opaque nasal foreign with number of cases.

Type of foreign body	Number of patients
Button battery	5
Safety pin	4
Marble stone	1
Bolt	1

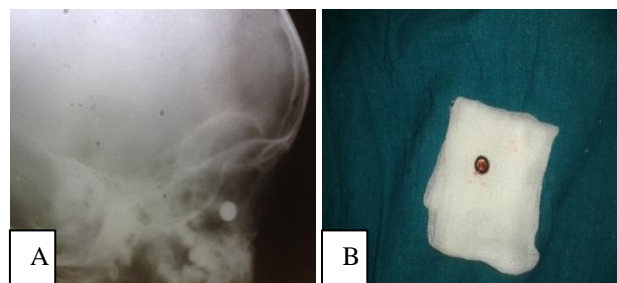


Figure 1: A= X-ray button battery; B= Button battery.

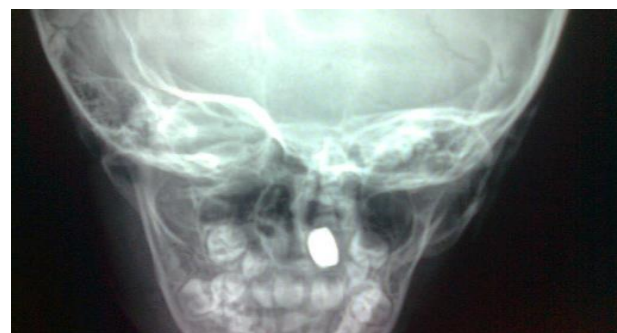

Figure 2: X-ray left nasal button battery.

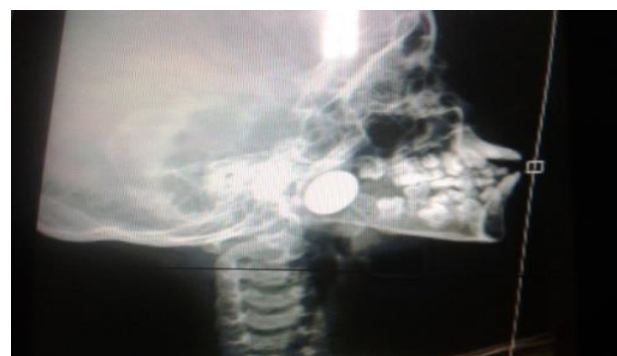

Fig 3: X-ray marble.

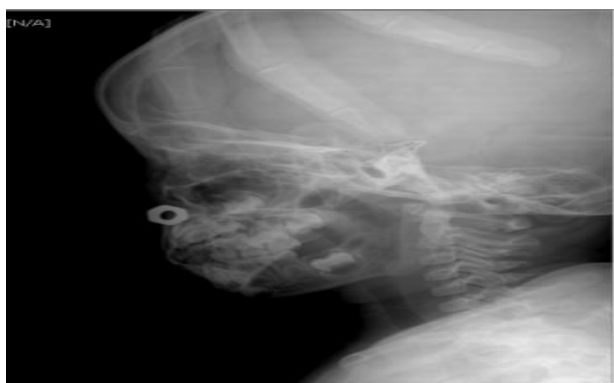

Figure 4: X-ray bolt.

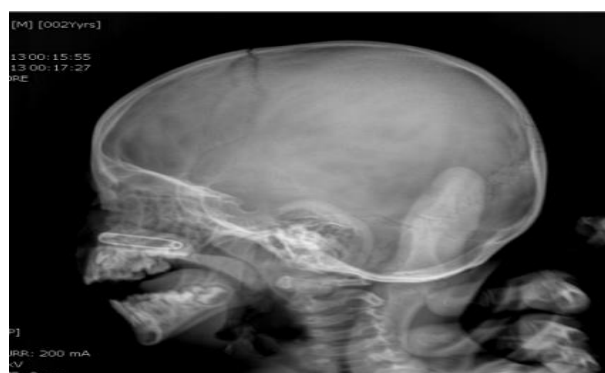

Figure 5: X-ray safety pin.

DISCUSSION

The nose is easily accessible by reason of its location on the face. Foreign body insertion into the nasal cavity is common among children. An unilateral mucopurulent nasal discharge with foul odour is the most common finding in patients with a nasal foreign body. Occasionally the discharge can be bloodstained.⁸ In our study, either the child revealed of accident self insertion of foreign body in nostril or noticed by parents. Black mucoid discharge was present in 5 button battery inserted in nostril patients. Since the incident was noticed by parents, medical attention was sought immediately we did not have complications of septal perforation.

The vast majority of button batteries today is of the alkaline variety.⁹ Four mechanisms of injury have been suggested: (1) Leakage of battery contents with direct corrosive damage on the mucosa, (2) direct electrical current effects on the mucosa resultant mucosal burns, (3) pressure necrosis as a result from prolonged local pressure on the tissue, and (4) local toxic effect due to absorption of substances.¹⁰⁻¹⁴

In our study 3 safety pins were removed with forceps under anaesthesia, while 1 case the removal was done in outpatient department. All 4 were closed pins and removed without any injury to nasal mucosa.

All the 10 patients' foreign body prompt removal was done using 0 degree nasal endoscope, hence we did not encounter any serious complication, similar to study by Bose et al.¹⁵

CONCLUSION

Nasal foreign bodies are a common problem among children's. The foreign body retrieval can be posing a great challenge to the otorhinolaryngologists as the child will not co-operate for removal. The radiolucent foreign body may pose a diagnostic challenge and any unilateral foul smelling blood tinged should be examined with nasal endoscope for any foreign body. The radio opaque foreign body especially button battery, if not removed may lead to serious complications like septal perforations, as the discharge from button battery may obscure the proper visualisation and removal. These foreign bodies need to be immediately without any delay.

Funding: No funding sources

Conflict of interest: None declared

Ethical approval: The study was approved by the Institutional Ethics Committee

REFERENCES

1. Krishnappa BD. Endoscopic Removal of an Unusual Foreign Body in the Nasopharynx in a 3-Year-Old Child. *Int J Head Neck Surg.* 2013;4(3):140-1.
2. DeWeese DD, Saunders AH. Acute and chronic diseases of the nose. In: DeWeese DD, Saunders AH, eds. *Textbook of otolaryngology.* St Louis: CV Mosby; 1982.
3. Baluyot ST. Foreign bodies in the nasal cavity. In: Paparella MM, Shumrick DA, eds. *Otolaryngology.* Philadelphia: WB Saunders; 1980: 2009–16.
4. Kelemen G. Spontaneous expulsion of a foreign body by transmigration through the nasal wall after 28 years. *Laryngoscope.* 1955;55:375–9.
5. Brown CR. Intranasal button battery causing septal perforation. A case report. *J Laryngol Otol.* 1994;108:589-90.
6. Tong MC, Van Hasselt CA, Woo JK. Hazard of button batteries in the nose. *J Otolaryngol.* 1992;21:458-60.
7. Kalan A, Tariq M. Foreign bodies in the nasal cavities. A comprehensive review of the aetiology, diagnostic pointers and therapeutic measures. *Postgrad Med J.* 2000;76:484-7.
8. Walby AP. Foreign bodies in the ear or nose. In: Kerr AG, ed. *Scott-Brown's otolaryngology.* 6th Ed. Oxford: Butterworth-Heinemann; 1997: 1–6.
9. Lin VY, Daniel SJ, Papsin BC. Button batteries in the ear, nose and upper aerodigestive tract. *Int J Pediatr Otorhinolaryngol.* 2004;68(4):473-9.
10. Soerdjbalie-Maikoe V, van Rijn RR. A case of fatal coin battery ingestion in a 2-year-old child. *Forensic Sci Int.* 2010 20;198(1-3):19-22.

11. McRae D, Premachandra DJ, Gatland DJ. Button batteries in the ear, nose and cervical esophagus. 1989;18(6):317-9
12. Alvi A, Bereliani A, Zahtz GD. Miniature disc battery in the nose. a dangerous foreign body. *Clin Pediatr (Phila)*. 1997;36(7):427-9.
13. Temple DM, McNeese MC. Hazards of battery ingestion. *Pediatrics*. 1983;71(1):100-3.
14. Premachandra DJ, McRae D. Severe tissue destruction in the ear caused by alkaline button batteries. *Postgrad Med J*. 1990;66(771):52-3.
15. Majumdar AB, Sengupta A, Paul SS. A case series of button batteries as nasal foreign bodies among children. *Int J Advances Med*. 2014;1(3):273-6.

Cite this article as: Satish KP, Vikram VJ, Mannarmannan N, Bhavani R. Diagnosis and management of radio opaque nasal foreign bodies in children. *Int J Otorhinolaryngol Head Neck Surg* 2018;4:424-7.