

Original Research Article

DOI: <http://dx.doi.org/10.18203/issn.2454-5929.ijohns20181858>

Endoscopic transcanal tympanoplasty: a case series

Bela J. Prajapati, Nikhil D. Patel, Shreya Rai*

Department of Otorhinolaryngology, B.J. Medical College, Civil Hospital, Ahmedabad, Gujarat, India

Received: 26 January 2018

Revised: 12 March 2018

Accepted: 14 March 2018

*Correspondence:

Dr. Shreya Rai,

E-mail: drshreyarai@gmail.com

Copyright: © the author(s), publisher and licensee Medip Academy. This is an open-access article distributed under the terms of the Creative Commons Attribution Non-Commercial License, which permits unrestricted non-commercial use, distribution, and reproduction in any medium, provided the original work is properly cited.

ABSTRACT

Background: Microscopes have ruled ear surgeries for years. The invention of endoscope and its use in otorhinolaryngology have become an important alternative for use. Importance of endoscope lies in giving the operating surgeon a wider exposure of the EAC and access in various hidden areas without need of a post auricular incision. Aim of this study is to analyze the outcome of endoscopic transcanal tympanoplasty.

Methods: This prospective study was conducted in the Department of ENT, B.J. Medical College, Ahmedabad, from July 2015 to July 2017. Thirty patients with tympanic membrane perforation (tubotympanic type) were included in study. Patients were followed up for a mean duration of 12 months and the outcome was analyzed.

Results: The patients included in the study ranged in the age group of 15-55 years. Out of them 16 were males and 14 were females. All of them underwent endoscopic transcanal tympanoplasty. 2 out of 30 patients had graft failure while others had good graft uptake. Overall success rate was 93.3%.

Conclusions: Transcanal endoscopic tympanoplasty is highly successful, safe and less traumatic and thus can be used for ear surgeries.

Keywords: Endoscopic tympanoplasty, Transcanal, Tubotympanic type

INTRODUCTION

The invention and use of microscope in otology was a significant occurrence as it changed the course of ear surgeries but there has been no major developments in their basic science and its limitations and straight line magnification have remained the same. Thus there was a need for newer techniques.¹ Endoscopes were used in otorhinolaryngology for several years and especially in rhinology thus with the use of endoscope in otology the wide angled view has made transcanal approach to ear very easy and even approaches to areas like attic, sinus tympani, facial recess, supratubal recess and hypo tympanum is accessible which were not possible with microscopes.² Ventilation pathways through isthmus tympanicum anticus and posticus are visualized with use of endoscope and thus can be cleared if blocked due to

any disease process and aeration from mesotympanum to epitympanum and thus to the mastoid air cells is established. Endoscope also gives a high definition view of the middle ear and Eustachian tube.³ Transcanal endoscopic tympanoplasty is also beneficial as it demands lower operative time, less morbidity and no external post auricular incision.⁴ These are the most important reasons for its success. The aims and objectives of this study is to evaluate the outcome of endoscopic transcanal tympanoplasty and to study the techniques and various graft materials used.

METHODS

This prospective cross sectional study was carried out in patients presenting with chronic otitis media in Department of ENT, BJ medical college and civil

hospital, Ahmedabad over a period of two years from July 2015 to July 2017. The data collected was tabulated and subjected to statistical analysis using SPSS software.

Sample

Sample size was of 30 patients. All those who fit the inclusion criteria and gave consent for the study were included.

Inclusion criteria

Inclusion criteria were all patients with chronic otitis media-inactive mucosal type (tubotympanic); more than 12 years of age; patients with no evidence of ear discharge; no active foci of infection; wide EAC.

Exclusion criteria

Exclusion criteria were all patients with evidence of cholesteatoma; less than 12 years of age; patients with active ear discharge; active foci of infection; narrow EAC.

Surgical procedure

Informed and written consent was taken and every patient underwent pre anesthetic checkup. Endoscopic transcanal tympanoplasty was performed under general anesthesia. Patients were placed in the conventional position for otology surgery.



Figure 1: Showing endoscopic holder designed by the author herself.

For the procedure a Zye 0 degree rigid endoscope was used which was attached to an optofine microscope using an endoscopic holder which was designed by the author herself (Figure 1). This was connected to a Karl Storz monitor. Surgical instruments were used same as in routine surgeries.

After putting patient in surgical position painting and draping was done. EAC was infiltrated with 1:2 lac adrenaline and 2% xylocaine. Tragal cartilage or fascia lata graft was taken. Endoscopic examination was done

and size of perforation was assessed. Perforation margin was freshened and rosens incision kept. Tympanomeatal flap was elevated and after checking the ossicular status and round window reflex and the ventilation pathways, the graft was kept after adjusting its size with the size of the perforation and tragal cartilage slicer was used and cartilage was kept of 0.4 mm thickness. Graft was stabilized by GMDM gel foam and neosporin wick was kept. Dressing was given.

Prophylactic postoperative antibiotic therapy was started and patients were discharged day after the procedure.

Patients were followed up at one, four and twelve weeks postoperatively to assess graft uptake. Post-operative audiometry was carried out 3 months post procedure to check the hearing improvement and followed up till 12 months for any graft defect.

RESULTS

A total of 30 patients with chronic otitis media –inactive mucosal type were selected for the study. Of these 53% (16) were males and 47% (14) were females (Figure 2). It was noted that prevalence was highest in third decade which was 67% (20). Twenty percent (6) patients were less than 20 years old and 13% (4) were more than 30 years old (Table 1).

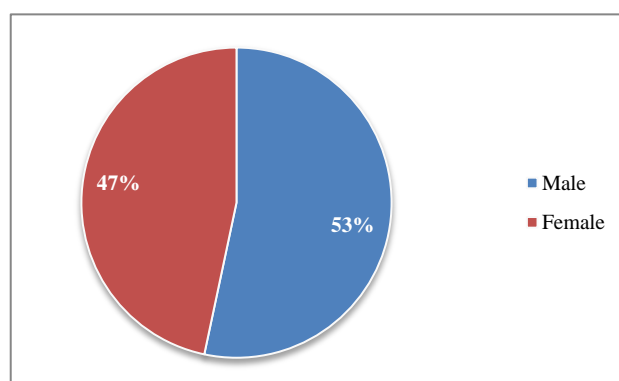


Figure 2: Showing sex prevalence in our study.

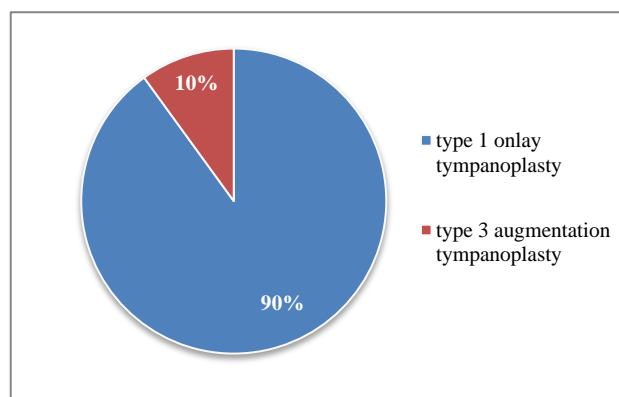


Figure 3: Showing type of tympanoplasty done.

In our clinical study, 90% (27) patients underwent type 1 onlay tympanoplasty and 10% (3) patients underwent type 3 augmentation tympanoplasty (Figure 3).

Table 2: Showing various type of graft materials used.

S. No	Type of graft material used	No. of patients	Percentage (%)
1)	Fascia lata	12	40
2)	Tragal cartilage	17	57
3)	Fascia lata + tragal cartilage	1	3

Fascia lata graft was used in 40% (12) patients, tragal cartilage in 57% (17) patients and tragal cartilage plus fascia lata graft was used in 3% (1) patient (Table 2).

In our study, success rate post endoscopic transcanal tympanoplasty was found to be 93.3%. Two out of 30 patients had graft failure. One patient with graft failure was managed with revision microscopic tympanoplasty and the second patient was managed by freshening of perforation margin using TCA. Both patients are on follow up with us.

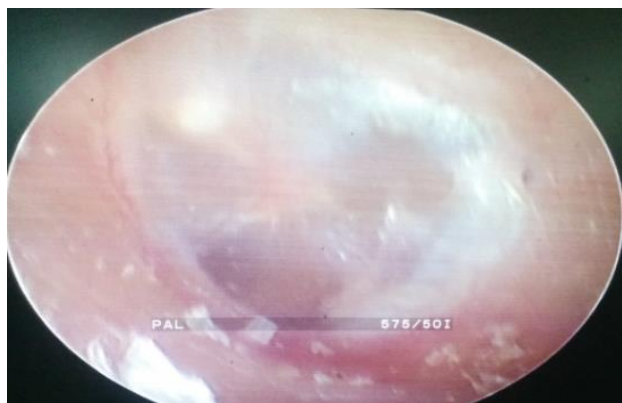


Figure 4: Showing graft uptake after 3 months post type 1 only endoscopic transcanal tympanoplasty (fascia lata graft).

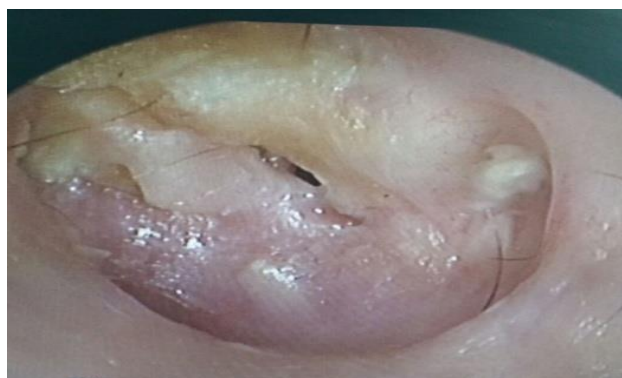


Figure 5: Showing graft defect after 3 months post type 1 onlay endoscopic transcanal tympanoplasty (fascia lata graft).

Endoscopic picture of graft uptake after 3 months post type 1 onlay endoscopic transcanal tympanoplasty (fascia lata graft) is given in (Figure 4) and image of graft failure after 3 months post type 1 onlay endoscopic transcanal tympanoplasty (fascia lata graft) is given in (Figure 5).

DISCUSSION

Chronic otitis media is one of the most common encountered disease in an otorhinolaryngologists day to day practice. The majority of the influx in the routine OPD is due to this very same disease. Microscopic surgery has been done since last few decades for this disease and thus various other methods have been researched since a long time and with the advent of endoscope and its used in otology for non complicated chronic otitis media cases a difference has been made in our management of the said disease.⁵

This present clinical study reviewed the effectiveness of endoscopic transcanal tympanoplasty in a government centre. Chronic otitis media which is non suppurative and non cholesteatomous is the best choice that was taken as there is minimal inflammation and surgical outcomes mainly depend on graft uptake and ossicular status.⁶ For years endoscopes have been used in various ENT surgeries but recently there has been a boom of use of it in various ear surgeries like myringoplasties, ossiculoplasties, stapedotomies etc.⁷⁻⁹

Sixty seven percent (20) of the patients were in age group 21-30, 20% (6) were less than 20 years and 13% (4) were more than 30 years in our study. There were 53% (16) males and 47% (14) females which was dissimilar to the study done by Choi et al.¹⁰

In our clinical study, 90% (27) of patients underwent type 1 only tympanoplasty and 10% (3) patients underwent type 3 augmentation tympanoplasty which was similar to the study done by Lade et al.¹¹ Fascia lata graft was used in 40% (12) patients, tragal cartilage in 57% (17) patients and tragal cartilage plus fascia lata graft was used in 3% (1) patient similar to the study done by Aiyar et al.¹²

Various studies have been done for endoscopic transcanal tympanoplasty. In a study of Ayache et al the success rate with endoscopic tympanoplasty was 96% which is similar to our study (93.3%).¹³

ACKNOWLEDGMENTS

A special mention goes to my Department of ENT, Civil hospital Ahmedabad for their constant support.

Funding: No funding sources

Conflict of interest: None declared

Ethical approval: Not required

REFERENCES

1. Furukawa T, Watanbe T, Ito T, Kubota T, Kakehata S. Feasibility and advantages of transcanal endoscopic myringoplasty. *Otol Neurotol*. 2014;35(4):140-5.
2. Karchier EB, Niemczyk K, Orlowski. A Comparison of visualisation of the middle by microscope and endoscope of 30 degree and 45 degree through posterior tympanotomy. *Videosurg Miniinvasive Tech*. 2014;9(2):276-81.
3. Marchioni D, Mattioli F, Alicandri-Ciufelli M, Molteni G, Masoni F, Presutti L. Endoscopic evaluation of middle ear ventilation route blockage. *Am J Otolaryngol*. 2010;31(6):453-66.
4. Hong P, Bance M, Gratzner PF. Repair of tympanic membrane perforation using novel adjuvant therapies: a contemporary review of experimental and tissue engineering studies. *Int J Paediatric Otorhinolaryngol*. 2013;77:3-12.
5. El-Guindy A. Endoscopic transcanal myringoplasty. *J Laryngol Otol*. 1992;106:493-5.
6. John SK, Jung MK, Hoffman MD, Drew BR, Preciado DA, Sausen NJ et al. The role of inflammatory mediators in the pathogenesis of otitis media and sequelae. *Clin Exp Otorhinolaryngol*. 2008;1:117.
7. Tarabichi M. Endoscopic transcanal middle ear surgery: *Indian J Otolaryngol Head Neck Surg*. 2010;62:6-24.
8. Mohindra S, Panda NK. Ear surgery without microscope: is it possible? *Indian J otorhinolaryngol Head Neck Surg*. 2010;62:138-41.
9. Junior JFN, Martins MJB, Aguiar CV, Pinheiro AI. Fully endoscopic stapes surgery (stapedotomy): technique and preliminary results. *Braz J Otorhinolaryngol*. 2011;77:721-7.
10. Choi N, Noh Y, Park W, Lee JJ, Yook S, Choi JE. Comparison of Endoscopic Tympanoplasty to Microscopic Tympanoplasty. *Clin Experimental Otorhinolaryngol*. 2017;10(1):44-9.
11. Lade H, Choudhary SR, Vashisth A. Endoscopic vs microscopic myringoplasty: a different perspective. *Eur Arch Otorhinolaryngol*. 2014;271:1897-902.
12. Patel J, Aiyer RG, Gajjar Y, Gupta R, Raval J, Suthar PP. Endoscopic tympanoplasty vs microscopic tympanoplasty in tubotympanic csom: a comparative study of 44 cases. *Int J Res Med Sci* 2015;3(8):1953-7.
13. Ayache S. Cartilaginous myringoplasty: the endoscopic transcanal procedure. *Eur Arch Otorhinolaryngol*. 2013;270:853-60.

Cite this article as: Prajapati BJ, Patel ND, Rai S. Endoscopic transcanal tympanoplasty: a case series. *Int J Otorhinolaryngol Head Neck Surg* 2018;4:717-20.