

Case Report

Right submandibular gland metastasis from an occult papillary thyroid cancer

Sheetal Radia¹, Chandra Veer Singh^{2*}, Priyanka Chamoli²

Department of Otorhinolaryngology, ¹Bharat Ratna Dr Babasaheb Ambedkar Municipal General Hospital, Kandivali West, ²Bombay Hospital and Institute of Medical Science, Mumbai, Maharashtra, India

Received: 17 January 2018

Revised: 03 March 2018

Accepted: 05 March 2018

***Correspondence:**

Dr. Chandra Veer Singh,

E-mail: cheer7us@yahoo.com

Copyright: © the author(s), publisher and licensee Medip Academy. This is an open-access article distributed under the terms of the Creative Commons Attribution Non-Commercial License, which permits unrestricted non-commercial use, distribution, and reproduction in any medium, provided the original work is properly cited.

ABSTRACT

Papillary microcarcinoma may present with clinical symptoms, most commonly jugulodigastric and pretracheal lymphadenopathy with or without palpable thyroid nodules. Isolated submandibular metastases are rare. We are presenting here a case report of 40-year old lady with an isolated submandibular gland metastasis arising from a papillary thyroid carcinoma. Submandibular gland excision of right side was done based on the fine needle aspiration cytology (FNAC) which suggested features of Basal cell adenoma vs cellular pleomorphic adenoma. USG neck s/o 3×3.5×2.8 cm sized hypoechoic lesion right submandibular. Histopathologic examination of the specimen suggested a metastatic papillary carcinoma. Total thyroidectomy was done, no other site of metastasis was found on radio-iodine scanning.

Keywords: Thyroid gland, Papillary carcinoma, Salivary gland, Submandibular gland metastasis

INTRODUCTION

The salivary glands are rarely involved by metastatic tumors. 10% of all malignant salivary gland tumors are metastatic, which definitely involve the parotid gland much more frequently than the submandibular glands, due to the differences in the number and anatomic relationships of the lymph nodes and their drainage.^{1,2} Parotid gland as the first clinical evidence of occult metastasis of thyroid carcinoma is known.³ Papillary microcarcinoma may present with clinical symptoms, most commonly jugulodigastric and pretracheal lymphadenopathy with or without palpable thyroid nodules. Isolated submandibular metastases are rare. In this case isolated metastasis to the submandibular gland was the first clinical evidence of primary occult thyroid carcinoma. In this case FNAC of submandibular gland study suggests features of basal cell adenoma vs. cellular

pleomorphic adenoma. USG neck s/o 3×3.5×2.8 cm sized hypoechoic lesion in right submandibular gland.

CASE REPORT

A 40-year old, lady presented with right side progressively increasing swelling in the right submandibular region since three years duration. There was no history of pain, and increase in size of the swelling during meals. No h/o bone pains, cough or haemoptysis. Urinary or bowel habits were normal.

On examination, the thyroid gland was enlarged on right side and had a smooth surface. In the neck region, there was a mass, 3 cm × 3 cm in size, arising from the submandibular gland and protruding from the under surface of the mandible. The swelling was nodular, non tender and not fixed to the mandible. Fine needle aspiration cytology study suggests features s/o Basal cell

adenoma vs cellular pleomorphic adenoma USG neck s/o 3×3.5×2.8 cm sized hypoechoic lesion right submandibular of the swelling. Right Side submandibular gland excision was done & specimen sent for histopathology. Biopsy report gives a final diagnosis of papillary carcinoma favouring metastatic mass postoperatively USG neck was done which revealed few tiny nodules in both the thyroid lobes. USG guided FNAC of the thyroid gland revealed inconclusive report. Patient subsequently underwent total thyroidectomy with right side MND type 3 (level I-V) along with bilateral Central compartment clearance. Specimen was sent for histopathological examination. Biopsy report gives a final diagnosis well differentiated papillary carcinoma with extra nodal extension and one of the four nodes shows metastasis without perinodal invasion. Postoperatively, on examination no abnormality in the thyroid, breasts, lungs, or abdomen found. Mammography of both breasts and ultrasound of the abdomen were normal. In radionuclide thyroid scan no active foci seen.

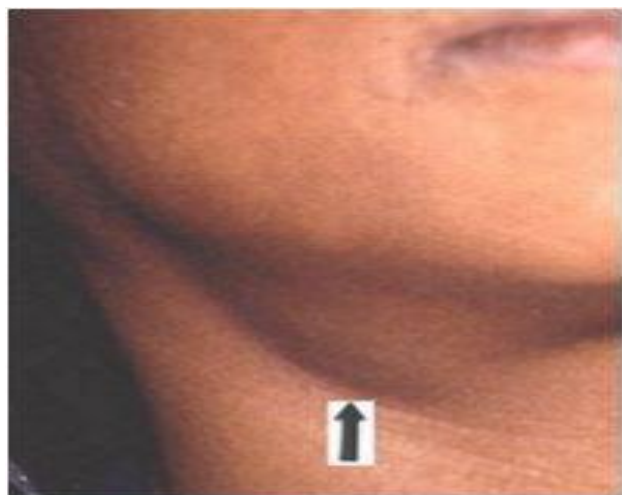

Figure 1: Submandibular swelling.

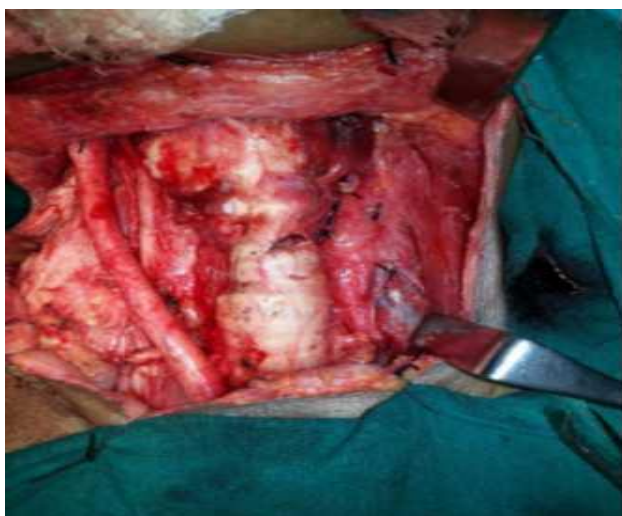

Figure 2: Intraoperative total thyroidectomy.

After six weeks and radio-ablation was performed. At follow-up, no residual tumor in the neck and no distant metastases were found. The patient is well without recurrent or metastatic disease after a year follow up.

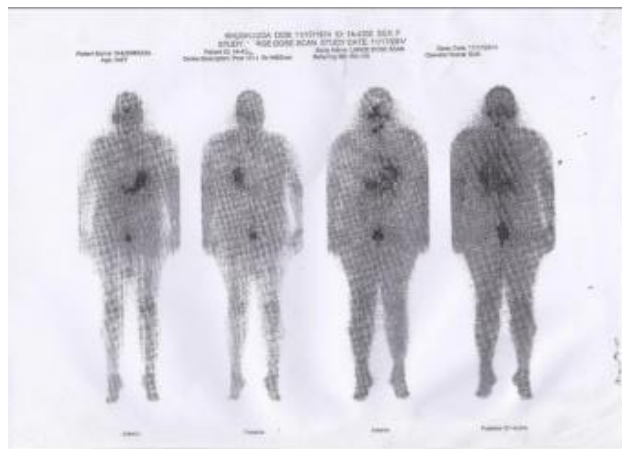


Figure 3: Thyroid scan after 1 month.

DISCUSSION

As per BTA guidelines (2007), a suspicious node in lateral compartment is treated with selective neck dissection (level IIa-Vb). Rarely, patients with clinical occult thyroid papillary carcinoma may present with metastasis at level I. Occult thyroid papillary carcinoma rarely presents with cervical lymph node metastasis.⁴ Some report of ectopic tissue in submandibular salivary glands are present.⁵ Although tumors metastatic to the salivary glands are rare but often located in the parotid gland (80-90%). In the parotid gland tumours, metastatic tumors constitute 10% of all the malignancies and 40% were melanoma, 40% were squamous cell carcinomas, the remaining were from primary sites in the head and neck region, mainly the scalp and ear, and rarely, thyroid and tonsils. Metastases to the submandibular gland were even rarer (10% to 20%).¹

Out of all salivary gland tumors mostly 85% occurred in the parotid gland. Out of which 18% were malignant, 7% salivary gland tumors were in the submandibular gland of which 37% were malignant.⁶ Metastatic spread to the submandibular gland had been reported previously albeit rare, being usually infraclavicular in origin, coming from the breast, lungs or kidneys⁸ and even the urinary bladder, colon and liver.⁹

This case is unusual as metastasis was confined to a single site in the right submandibular region with right juglar metastatic lymph node; along with pretracheal and paratracheal metastatic lymph node, and the aetiology arose from papillary carcinoma within both the thyroid lobes.

Papillary carcinomas within the thyroid gland are multifocal in 10–20% of cases.¹⁰ An unusual case of

isolated metastatic papillary carcinoma of submandibular nodes with extensive squamous metaplasia were reported, with a 2 cm size primary papillary carcinoma lesion in the ipsilateral thyroid gland.¹¹ A further case described ipsilateral submandibular nodal metastases from a papillary microcarcinoma.¹²

CONCLUSION

A palpable lesion in the submandibular gland is a primary salivary gland tumor; metastatic tumors are rare. In this case report we are emphasizing that whenever an unusual carcinoma is seen in a submandibular gland; metastasis from a papillary thyroid carcinoma should be considered.

Funding: No funding sources

Conflict of interest: None declared

Ethical approval: Not required

REFERENCES

1. Vaidya AM, Vaidya AM, Petruzzelli GJ, McClatchey KD. Isolated submandibular gland metastasis from oral cavity squamous cell carcinoma. *Am J Otolaryngol.* 1999;20:172-5.
2. Batsakis JG, Bautina E. Metastases to major salivary glands. *Ann Otol Rhinol Laryngol.* 1990;99:501-3.
3. Markitziu A, Fisher D, Marmary Y. Thyroid papillary carcinoma presenting as jaw and parotid gland metastases. *Int J Oral Maxillofac Surg.* 1986;15:648-53.
4. Allo MD, Christianson W, Koivunen D. Not all "occult" papillary carcinomas are "minimal". *Surgery.* 1988;104:971-6.
5. Aguirre A, de la Piedra M, Ruiz R, Portilla J. Ectopic thyroid tissue in the submandibular region. *Oral Surg Oral Med Oral Pathol.* 1991;71:73-6.
6. Eneroth CM. Salivary gland tumors in the parotid gland, submandibular gland, and the palate region. *Cancer.* 1971;27:1415-8.
7. Conley J, Arena S. Parotid gland as a focus of metastasis. *Arch Surg.* 1963;87:69-76.
8. Cain AJ, Goodland J, Denholm SW. Metachronous bilateral submandibular gland metastases from carcinoma of the breast. *J Laryngol Otol.* 2001;115:683-4.
9. Ichikawa T, Takagi H, Abe T, Ito H, Nagamine T, Mori M. Hepatocellular carcinoma with solitary metastasis in pleomorphic adenoma of the submandibular gland. *Histopathology* 2001;38:80-1.
10. Ahuja AT. The thyroid and parathyroids. In: Ahuja AT, Evans R, (eds). *Practical head and neck ultrasound.* London: Greenwich Medical Media Limited, 2000: 37-64.
11. Kunisue H, Mikami Y, Tanaka K, Sonoo H, Udagawa K, Yamamoto Y, et al. Metastatic papillary thyroid carcinoma of the submandibular lymph nodes with extensive squamous metaplasia: report of a case. *Surg Today.* 2003;33:751-4.
12. Sarda AK, Pandey D, Bhalla SA, Goyal A. Isolated submandibular gland metastases from an occult papillary thyroid cancer. *Indian J Cancer.* 2002;41:89-91.

Cite this article as: Radia S, Singh CV, Chamoli P. Right submandibular gland metastasis from an occult papillary thyroid cancer. *Int J Otorhinolaryngol Head Neck Surg* 2018;4:836-8.