

Original Research Article

Unusual sites of dermoid cysts

Sathyaki D. C.*, Mereen Susan Roy, Razal Mohammed Sherif, Ashish Rao

Department of E. N. T, Sri Siddhartha Medical College, Tumkur, Karnataka, India

Received: 28 December 2017

Revised: 28 January 2018

Accepted: 30 January 2018

***Correspondence:**

Dr. Sathyaki D. C.,

E-mail: sathyaki_dc@yahoo.co.in

Copyright: © the author(s), publisher and licensee Medip Academy. This is an open-access article distributed under the terms of the Creative Commons Attribution Non-Commercial License, which permits unrestricted non-commercial use, distribution, and reproduction in any medium, provided the original work is properly cited.

ABSTRACT

Background: Epidermoids are ectoderm lined inclusion cysts which can be present anywhere in the body, but are rare in head and neck. Although only 7% of the dermoid cysts occur in head and neck region they are a part of differential diagnosis of neck swellings. They are more common in midline. This study presents to you the dermoids which present in unusual sites.

Methods: It was a descriptive study. Cases which were proven as dermoid or epidermoid cysts by FNAC or by histopathology were included in this study.

Results: Male patients were more affected than female patients.

Conclusions: Complete removal should be carried out to prevent recurrence.

Keywords: Dermoid cysts, Parotid, Head and neck

INTRODUCTION

Dermoids and epidermoids are inclusion cysts that are lined by stratified squamous epithelium with variable amount of pilosebaceous units and sweat glands supported by fibrous connective tissue wall.¹ Both arise from trapped pouches of ectoderm, near normal folds or from failure of surface ectoderm to separate from the neural tube. These slowly expanding, unilocular cystic masses are usually asymptomatic or may produce mild symptoms.²

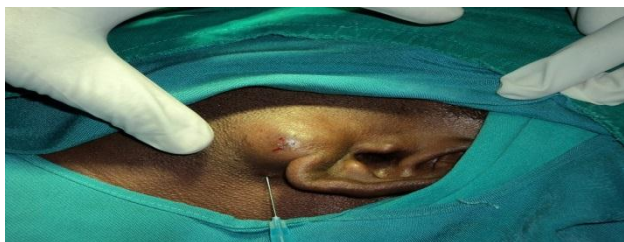

Figure 1: Clinical picture showing swelling in the parotid region.

Only 7% of them occur in head and neck region.³ They commonly occur in the orbit, calvarial diploic space and intracranially². It is rare in parotid region (Figure 1). Till the recent past only 17 cases have been reported. In this study we present a series of dermoid and epidermoid cysts who presented to our institution over a period of one year.

METHODS

This was an observational study carried out in the department of otorhinolaryngology, Sri Siddhartha Medical College, Tumkur, Karnataka from January 2013 to December 2013. A total of 25 patients of the 3432 out patients were included. In the same period 156 cases of dermoid and epidermoid cysts were diagnosed in various departments of our institution.

Patients aged more than 16 years who had a history of swelling in the head and neck region of more than 6 months, which were proven as dermoid or epidermoid cyst either by FNAC or histopathological examination were included in the study.

The selected patients were subjected to detailed history followed by complete clinical examination. All patients underwent either ultrasonography or computed tomography over the region of the swelling and FNAC of the swelling and the diagnosis of dermoid or epidermoid cyst were made. Patients later underwent surgical excision and the diagnosis was confirmed by histopathology.

Procedure

Patients with dermoid cyst in the parotid region and pre auricular region underwent excision through standard parotidectomy approach (Figure 2). In case of epidermoid cyst over the maxilla, sublabial approach was followed. In case of dermoid cyst over forehead and posterior triangle an elliptical incision was made and the cyst was dissected.

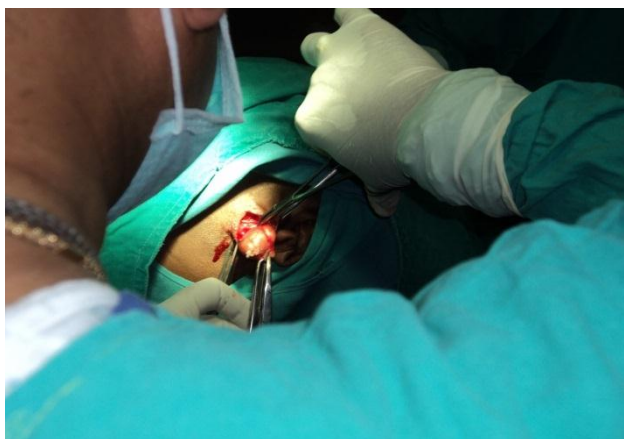

Figure 2: Showing the surgical approach.

RESULTS

In our study the age of patients varied between 20 years and 60 years. They were no patients who were above 61 years. In this series there were 7 patients in the age group of 21-30 years and 51-60 years. There were 8 patients in the age group of 31-40 years and 4 in the age group of 41-50 years. There were 6 patients in the age group of 51-60 years. The Chi-square test done shows the difference between the age-group prevalence is not significant.

Table 1: Age distribution.

Age group	No. of out patients	Percentage (%)	No. of cases
21-30	549	16	7
31-40	755	22	8
41-50	961	28	4
51-60	412	12	6
61<	755	22	Nil

In this series there were 21 male patients and 4 female patients (Table 2). In this series there were ten patients

with dermoid cysts in the fore head region, seven in the posterior triangle, five patients in the parotid region and two in the pre auricular and one over the maxilla (Table 3).

Table 2: Sex distribution.

Sex	No. of out patients	Percentage (%)	No. of cases
Males	1842	53.7	21
Females	1590	46.3	4

Table 3: Site distribution.

Site	No. of cases	Percentage (%)
Parotid	5	20
Pre auricular	2	8
Over the maxilla	1	4
Posterior triangle	7	28
Fore head	10	40%

Histopathological examination of the specimens (Figure 3) showed fibrofatty tissue and lymphoid aggregates with keratin material. It also showed haemorrhage with inflammatory infiltrate. It showed tissues derived from mesoderm. It was lined by squamous epithelium. It was suggestive of a dermoid cyst (Figure 4).

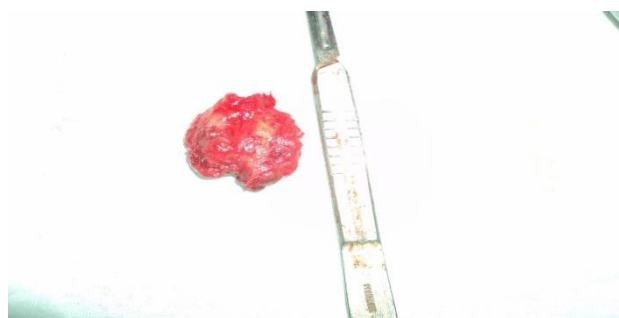


Figure 3: Showing the specimen.

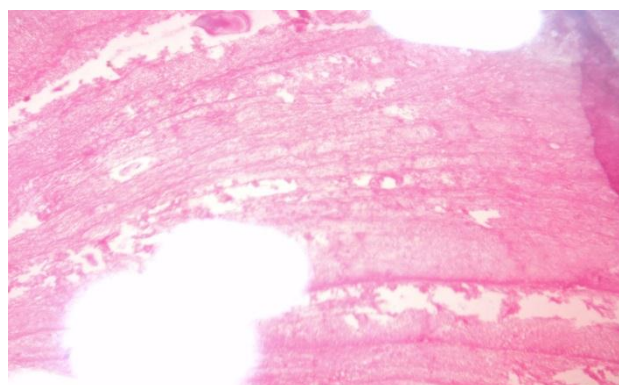


Figure 4: Histopathological examination.

DISCUSSION

Epidermoids arise from ectoderm, but they are inclusion cysts that are lined only by squamous epithelium. A dermoid is also an ectodermal inclusion cyst, but it contains more complex tissues which are also derived from ectoderm. Teratoma need not necessarily contain tissues derived from all three germ layers. A teratoma can be defined as a true neoplasm that contains tissues that are either foreign to the primary site of origin or histologically diverse and represent more than one of the embryonic germ layers. The designation of teratoma may be appropriate even for a lesion with tissues derived from a single embryonic germ layer, if the tumor shows histologically divergent differentiation. Such teratomas can be found in the head and neck and can be purely ectodermal.¹

Epidermoid cysts are classified into congenital and acquired type. Congenital type occurs due to entrapment of ectodermal substance between the midline fusion of first and second branchial arches during third and fourth intrauterine life. Acquired type cysts usually occur due to infection around pilosebaceous follicle and sometime deep implantation of epidermis as a result of penetrating or blunt injury. It is slow growing and non-tender mass. When present in dermis, it raises epidermis to produce a firm elastic dome-shaped protuberance which is mobile over the deeper structures. They grow slowly and may become inflamed and firm time to time. Suppuration may occur.² New and Erich classified these cysts into these categories:

- Congenital of teratoma type: They arise from the embryonic germinal layers. Depending on the dormant layer, they can contain skin, hair or teeth etc. They are almost always limited to the ovaries and testes.
- Acquired: They are inclusion cysts as a result of traumatically implanted skin in the deeper tissues. They occur on the hands and the other exposed parts of the body.
- Congenital inclusion cysts: These develop from inclusions of displaced dermal cells along the lines of embryologic fusion. This category is subdivided into four subgroups:
 - a) Cysts around the eyes and orbits, originating along the nasooptic groove,
 - b) Those around the nose, resulting from intrusion of the frontonasal plate,
 - c) Those around the floor of the mouth, and in submental and submaxillary regions, originating from the 1st and 2nd branchial arches,
 - d) Those around the suprasternal, suboccipital, thyroidal, lower lip and palate, most of which occur along the midventral or middorsal lines of the body.¹

Manoharan et al reported post auricular sinuses are the most common etiology for recurrent post aural abscess followed by dermoid cyst.⁴ Ravindranath et al reported epidermoid cyst to be most common in the lateral side of the neck and gingiva followed by the forehead region.⁵ Dhabholkar et al reported 3 cases of dermoid cysts out of which 2 were located in the floor of the mouth and another in the midline of the neck.⁶ Ultrasonography is the best investigation for these types of cyst. It is economical, reliable and without radiation exposure. Surgical excision of the cyst is often required and the entire cyst wall is removed to prevent recurrence. Incomplete removal is common if attempted in the presence of recent infection.³ Our study shows males are more affected than in females which have not been reported in previous studies.

CONCLUSION

Although only 7% of the dermoid and epidermoid cysts occur in head and neck, they form an important differential diagnosis of parotid swellings among adults. Surgical excision is required and histopathological examination should be mandatory. Incomplete removal may result in recurrence. It is more common in males

Funding: No funding sources

Conflict of interest: None declared

Ethical approval: The study was approved by the Institutional Ethics Committee

REFERENCES

1. Yigit N, Karlioglu Y, Yildizoglu U, Karakoc O. Dermoid Cyst of the Parotid Gland: Report of a Rare Entity with Literature Review. *Head Neck Pathol.* 2015;9(2):286-92.
2. Smiriniotopoulos JG, Chiechi MV. Teratomas, dermoids and epidermoids of the head and neck. *Radiographics.* 1995;15(6):1437-55.
3. Baisakhiya N, Deshmukh P. Unusual sites of epidermoid cyst. *Indian J Otolaryngology Head Neck Surg.* 2011;63(1):149-51.
4. Manoharan KS, Saxena SK, Gopalakrishnan S. Congenital anomalies presenting as recurrent post-auricular abscesses: An institution based retrospective study. *International J Pediatr Otorhinolaryngol.* 2013;5876(13):242-5.
5. Ravindranath AP, Ramalingam K, Natesan A, Ramani P, Premkumar P, Thirevengadam C. Epidermoid cysts: an exclusive palatal presentation and a case series. *Int J Dermatol.* 2009;48(4):412-5.
6. Dhabholkar JP, Patole AD, Seth AS, Saaj R. Congenital cystic lesions in head and neck. *Indian J Otolaryngol Head Neck Surg.* 2003;55(2):128-30.

Cite this article as: Sathyaki DC, Roy MS, Sherif RM, Rao A. Unusual sites of dermoid cysts. *Int J Otorhinolaryngol Head Neck Surg* 2018;4:459-61.