

## Original Research Article

# Conventional vs. endoscopic septoplasty: our experience

Visweswara Rao Suraneni<sup>1\*</sup>, Suneel Kudamala<sup>1</sup>, Srikanth K.<sup>2</sup>

<sup>1</sup>Department of ENT, Maharajah's Institute of Medical Sciences, Nellimarla, Vizianagaram, Andhra Pradesh, India

<sup>2</sup>Consultant, Department of ENT, KIMS Hospital, Srikakulam, Andhra Pradesh, India

**Received:** 04 December 2017

**Revised:** 20 December 2017

**Accepted:** 21 December 2017

### \*Correspondence:

Dr. Visweswara Rao Suraneni,

E-mail: [dr.s.visweswararao@gmail.com](mailto:dr.s.visweswararao@gmail.com)

**Copyright:** © the author(s), publisher and licensee Medip Academy. This is an open-access article distributed under the terms of the Creative Commons Attribution Non-Commercial License, which permits unrestricted non-commercial use, distribution, and reproduction in any medium, provided the original work is properly cited.

## ABSTRACT

**Background:** A straight septum is the exception rather than the rule. A deviated septum can be asymptomatic or can cause functional and cosmetic abnormality. Different surgeries have been proposed for correction of deviated septum but septoplasty has been the procedure of choice. Septoplasty is a more conservative surgery with fewer complications and endoscopic septoplasty has become increasingly popular over the last few decades.

**Methods:** This is a comparative study conducted at a tertiary care centre over a period of 1 year on 100 cases to compare the efficacy of endoscopic septoplasty with conventional septoplasty. 50 cases underwent conventional septoplasty while the other 50 cases underwent endoscopic septoplasty. Relief from pre-operative symptoms, anatomical correction of deformity and intraoperative/postoperative complications were studied.

**Results:** Patients belonging to endoscopic septoplasty group showed better symptomatic relief and lesser incidence of complications when compared to the conventional septoplasty group.

**Conclusions:** Endoscopic septoplasty has better illumination and additional magnification which aid in accurate identification of pathology and precise excision of the deviated septal part. It is also useful for correction of posterior and high deviations of septum and for revision surgeries. Conventional septoplasty has got its own merits like dealing with situations in which septal damage is more and post trauma. Though better patient compliance, better relief from symptoms and lesser rate of complications give an edge for endoscopic over conventional septoplasty, both the procedures need to be done together in some situations to achieve optimal results.

**Keywords:** Deviated nasal septum, Conventional septoplasty, Endoscopic septoplasty

## INTRODUCTION

A straight septum is the exception rather than the rule.<sup>1</sup> Nasal obstruction caused by a deviated nasal septum (DNS) is one of the most common presentations at any Otorhinolaryngology outpatient department. DNS can become symptomatic at any age. DNS not only causes breathing difficulties but also causes improper aeration of para nasal sinuses leading to infection of the same. Any functional or cosmetic disturbance caused by a deviated septum needs to be addressed.

Different surgeries have been proposed for the correction of DNS. Initially, submucosal resection of septum was proposed but was later replaced by septoplasty as it was less radical.<sup>2</sup> With the advent of endoscopy, its use in septoplasty was proposed. Endoscopic septoplasty has the advantage of better illumination and magnification. It helps in the accurate diagnosis of the septal deviation, intensity of nasal obstruction as well as its correlation with the lateral nasal wall.<sup>3</sup>

Endoscopic septoplasty was found to be very helpful in dealing with nasal polyposis and lateral wall

abnormalities. Endoscopic septoplasty is also done as prior procedure in different intra-nasal surgeries requiring space for instrumentation. It is an excellent tool for the examination of nasal cavities following septoplasty in early as well as late postoperative periods.<sup>4</sup>

The present study is carried out in a tertiary care hospital to compare the pre-operative symptoms, post-operative outcomes and objective complications of Endoscopic and Conventional septoplasty.

## **METHODS**

This Institution based prospective study was conducted on 100 clinically diagnosed cases of deviated nasal septum attending the ENT Out Patient Department from Aug 2016 to Aug 2017. All patients presenting to OPD meeting the inclusion criteria were included in the study. Patients with age greater than 16 years and symptomatic DNS were included in the study. Patients with age less than 16 years and greater than 65 years, asymptomatic DNS, patients with acute rhinitis or allergic rhinitis, diabetes and hypertension were excluded from the study.

A pre-designed case-sheet proforma was put forward to the patients and detailed history taken. Presence or absence of symptoms like nasal block, discharge, hyposmia, sneezing, bleeding, headache and post nasal drip was noted. Thorough local examination of the nose, ear and throat was done.

Bi-digital palpatory examination of nose was done to check for deformity. Tip rotation, if present was noted. Anterior rhinoscopy followed by cold spatula test was done to check the patency of respective nasal cavity. Septal deviations were classified as right, left or S shaped. Caudal dislocations, spurs were noted down. Posterior rhinoscopy was done.

All the cases were examined endoscopically to observe the contributing factor for the deviation, its extent and also to check for posterior and high deviations. Routine hematologic tests and X-ray PNS (Water's view) were done. In cases with suspected paranasal sinus pathologies, a non-contrast computerised tomogram of the PNS was done. The patients were divided into two groups; one group underwent conventional septoplasty and the other, endoscopic septoplasty.

### ***Pre-operative preparation***

Xylocaine test dose was given and part preparation done. Pre-medication with 25 mg Phenargan (Promethazine) and 30 mg Fortwin (Pantazocine) was given 30 min prior to surgery. Nasal packing with ribbon gauze soaked in 4% xylocaine with 1 in 1,00,000 adrenaline was done 10 min prior to surgery. All cases were done under local anaesthesia.

## ***Surgical techniques***

### ***A. Conventional septoplasty (CS)***

2% xylocaine with adrenaline (1 in 2,00,000) infiltrated into entire septum on both sides. Incision given at caudal border of septal cartilage (Freer's incision) on the left side of patient. Mucoperichondrial and mucoperiosteal flaps elevated on left side. Bony cartilaginous junction dislocated. Mucosperiosteum of opposite side elevated. Deviated bony septum removed with Luc's forceps. A strip of 0.5 mm of cartilage removed from inferior border of septal cartilage. Incision is given on the maxillary crest and periosteum is elevated on the crest as well as anterior nasal spine. Bony spur is chiseled out leaving anterior nasal spine in place. Incision sutured with 3-0 chromic catgut and nasal cavities packed with ribbon gauze impregnated with Soframycin (Framycetin) ointment.

### ***B. Endoscopic septoplasty (ES)***

2% xylocaine with adrenaline (1 in 2,00,000) infiltrated into area of interest such as isolated spur or along the floor. An incision is made posterior to caudal end of septum in most of the cases. It was given on the convex side in cases of anterior deviation, on the concave side for subluxation. In cases of isolated bony spur, incision was made parallel to the floor. Mucoperichondrial flap was elevated initially with Freer's elevator and nasal speculum. Further elevation was done using 0° rigid nasal endoscope (4 mm). Bony cartilaginous junction dileneated and deviated septal part removed with Luc's forceps. Caudal dislocation or anterior buckling of cartilage was corrected at the end after correcting the rest of the septum. Isolated spur without any septal deviation was resected after incision and exposure directly over the spur. Deviations contributed by maxillary crest were chiseled out. Flap was repositioned and nasal cavities packed with ribbon gauze impregnated with Soframycin (Framycetin) ointment.

### ***Postoperative management***

On the second postoperative day, nasal packs were removed and nasal endoscopy with suctioning was done for all the patients. Most of the patients were discharged after pack removal and were put on appropriate antibiotics for 1 week along with analgesics and decongestant nasal drops. They were advised to follow up on the seventh post op day and weekly thereafter for one month. At each follow up visit, subjective assessment about nasal obstruction, headache, discharge was done and objective assessment by nasal endoscopy was carried out. Complications if any, were addressed and the outcomes of the surgery measured.

### ***Statistical analysis***

The observations were tabulated on a spreadsheet in microsoft excel and statistical analysis was carried out with paired "t" test and independent "t" test using SPSS

software. A “p” value <0.05 was considered statistically significant.

## RESULTS

In this present study 50 cases of conventional and 50 cases of endoscopic septoplasty were assessed.

### Age distribution

In the group who underwent conventional septoplasty, the age range was 19-42 years and in the group who underwent endoscopic septoplasty it was 17-45 years. The age group wise distribution of cases who underwent both the techniques is depicted in Table 1.

**Table 1: Age distribution of cases.**

Age group (in years)	Type of septoplasty		Total number of cases (n=100)	Percentage (%)
	Conventional	Endoscopic		
11-20	06	20	26	26
21-30	31	22	53	53
31-40	13	06	19	19
41-50	00	02	02	02

**Table 2: Presenting symptoms.**

Symptoms	Number of cases		Total number of cases (n=100)	Percentage (%)
	Conventional	Endoscopic		
Nasal obstruction	50	50	100	100
Headache	22	28	50	50
Post nasal discharge	03	08	11	11
Hyposmia	08	03	11	11
Nasal discharge	03	07	10	10

**Table 3: Postoperative symptomatology.**

Symptom	Conventional septoplasty			Endoscopic septoplasty		
	Post op/pre op	Total number of cases relieved of symptom	Percentage of benefit (%)	Post op/pre op	Total number of cases relieved of symptom	Percentage of benefit (%)
Nasal obstruction	4/50	46	92	2/50	48	96
Headache	3/22	19	86.37	1/28	27	96.42
Post nasal discharge	1/3	02	66.67	0/8	08	100
Hyposmia	1/8	07	87.5	0/3	3	100
Nasal discharge	0/3	03	100	0/7	07	100

### Sex distribution

In the study, 47 were males and 53 females. In the conventional septoplasty group, 26 (52%) were males and 24 (48%) were females. In the endoscopic septoplasty group, 21 (42%) were males and 29 (58%) were females. The sex distribution of cases who underwent both the techniques is depicted in Figure 1.

### Presenting symptoms

In this study, all the 100 patients presented with nasal obstruction. The next common symptom was headache present in 50 patients, out of which 22 (44%) belonged to

conventional septoplasty group and 28 (56%) belonged to endoscopic septoplasty group. This was followed by post nasal discharge and nasal discharge present in 11 and 10 cases respectively. Hyposmia, a neglected symptom was present in 11 cases. The presenting symptoms are shown in Table 2.

### Postoperative symptomatology

All the patients were reviewed on 7<sup>th</sup> postoperative day and weekly thereafter for a period of 1 month. During each visit patients were asked about relief from the preoperative symptoms, the data of which is depicted in Table 3.

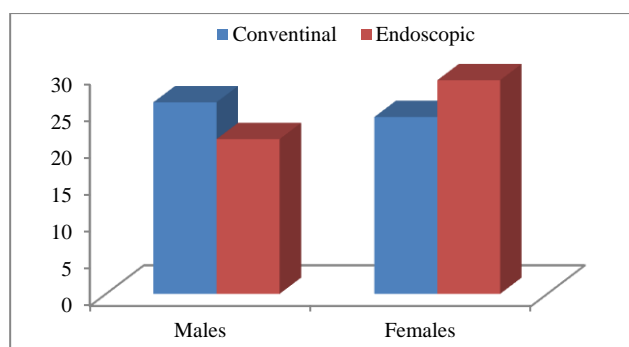


Figure 1: Sex distribution of cases.

### Complications

In this study, 6 patients (12%) in the conventional septoplasty group had intra operative or postoperative bleeding while only 2 patients (4%) in endoscopic septoplasty group had this complication. Mucosal tears were seen in 8 patients (16%) in conventional group and in 3 patients (6%) in endoscopic group. Postoperative synechiae were seen in only 2 patients (4%) belonging to conventional septoplasty group while this complication was absent in endoscopic septoplasty group. These are presented in Table 4.

Table 4: Complications.

Complications	Conventional		Endoscopic		Total	Percentage (%)
	No. of cases	Percentage (%)	No. of cases	Percentage (%)		
Haemorrhage	06	12	02	04	08	08
Mucosal tears	08	16	03	06	11	11
Synechiae	02	04	00	00	02	02

Table 5: Group statistics.

	Procedure	N	Mean	Std. dev	Std. error mean
Nasal block	Post CS	50	1.92	0.274	0.039
	Post ES	50	1.96	0.198	0.028
Headache	Post CS	50	1.94	0.240	0.034
	Post ES	50	1.98	0.141	0.020
PND	Post CS	50	1.98	0.141	0.020
	Post ES	50	2.00	0.000	0.000
Hyposmia	Post CS	50	1.90	0.303	0.043
	Post ES	50	2.00	0.000	0.000
Nasal discharge	Post CS	50	2.00	0.000 <sup>a</sup>	0.000
	Post ES	50	2.00	0.000 <sup>a</sup>	0.000

<sup>a</sup> =t cannot be computed because the Std. dev of both groups are zero, CS= Conventional septoplasty, ES= Endoscopic septoplasty.

Table 6: Independent samples test.

		Levene's test for equality of variances		T-test for equality of means		
		F value	Sig.	T value	d.f.	Sig. (2-tailed)
Nasal block	Equal variances assumed	2.876	0.093	-0.837	98	0.405
	Equal variances not assumed			-0.837	89.190	0.405
Headache	Equal variances assumed	4.299	0.041	-1.016	98	0.312
	Equal variances not assumed			-1.016	79.387	0.313
PND	Equal variances assumed	4.168	0.044	-1.000	98	0.320
	Equal variances not assumed			-1.000	49	0.322
Hyposmia	Equal variances assumed	27.562	0.000	-2.333	98	0.022
	Equal variances not assumed			-2.333	49	0.024

### Statistical calculations

The statistical calculations are given in Tables 5 and 6. According to the calculations from the above tables, p value for headache, post nasal discharge and hyposmia is

<0.05. Hence the results are considered to be significant inferring that there is improvement in postoperative symptomatology in endoscopic group when compared to conventional group. The p value for nasal block is >0.05, the result being not significant, inferring that there is no difference between two groups.

## DISCUSSION

Surgical techniques to address the nasal block caused by a deviated nasal septum have greatly developed over the years. The trend has been from septoplasty to SMR (sub mucosal resection) and again back to septoplasty. With the advent of endoscopy, its use in septoplasty has had its own implications. Symptomatic relief and significant reduction in postoperative morbidity, due to precise manipulation in steps like flap elevation and resection of septal framework, have been the added benefits of endoscopic septoplasty.<sup>5</sup>

In the present study, an attempt has been made to compare the preoperative symptoms, postoperative outcomes and objective complications of endoscopic and conventional septoplasty taking 50 cases in each group respectively.

In this study all the 100 cases were adults with age varying between 17 and 45 years. The average age of patients in conventional septoplasty group was 27.82 years and 25.26 years in endoscopic group with overall mean age of 28.82 years. This result is similar to the existing literature. The male to female ratio was 1.08:1 with 26 males and 24 females in conventional septoplasty group and it was 1:1.38 with 21 males and 29 females in the endoscopic septoplasty group. This result is contrary to the study conducted by Muhammad et al, who conducted a descriptive study on 200 patients to assess the complications of septoplasty and submucosal resection of septum, in which 162 patients (81%) were males and 38 patients (19%) were females with a male to female ratio of 4.26:1.<sup>6</sup>

All the 100 patients in the study presented with nasal obstruction. 50 patients (50%) complained of headache, 11 patients (11%) had hyposmia, 11 patients (11%) had post nasal discharge and 10 patients (10%) complained of nasal discharge. This result is comparable to a study conducted by Nayak et al, on 60 patients of whom, 47 patients (78.3%) had complaint of nasal obstruction, 46 patients (76.66%) had headache, 27 patients (45.00%) had rhinorrhoea, 35 patients (58.33%) had post nasal discharge and 5 patients (8.33%) had hyposmia.<sup>7</sup> In another study conducted by Aranachlam et al, nasal obstruction was the predominant complaint present in 74% patients.<sup>8</sup>

In the present study, all the patients were discharged on the 2<sup>nd</sup> postoperative day after pack removal and followed up on the 7<sup>th</sup> post op day and weekly thereafter for one month. The nasal obstruction was persistent in 4 patients (benefit -92%) in conventional septoplasty group and in 2 patients (benefit -96%) in endoscopic septoplasty group. 27 out of 28 patients were relieved of headache (96.42%) in endoscopic septoplasty group and 19 out of 22 patients (86.37%) in conventional septoplasty group. Post nasal discharge was absent in all the patients after endoscopic septoplasty (100% benefit) while the benefit was 66.67%

in conventional septoplasty group. Similarly all the patients were relieved of hyposmia after endoscopic septoplasty (100%) while the benefit was 87.5% in the conventional group. Similar results were obtained by Park et al, who conducted a comparative study between endoscopic and classical septorhinoplasty on 44 patients in whom the patient satisfaction and complication percentage were 87.5% and 0% in endoscopic group and, 71.4% and 14.3% in classical septorhinoplasty group.<sup>9</sup>

In the present study, haemorrhage was the most common complication seen in 6 cases (12%) of conventional septoplasty group compared to 2 cases (4%) in endoscopic septoplasty group. Mucosal tears occurred in 8 patients (16%) in conventional septoplasty group compared to 3 patients (6%) in endoscopic septoplasty group. Postoperative synechiae were absent in endoscopic group while they were present in 2 patients of conventional group. These findings are in agreement with a study done by Park et al, in which complications were present in 14.3% of patients in classical septoplasty group when compared to 0% in endoscopic group. The obtained results are also similar to a study conducted by Rajguru et al, on 100 patients to compare the efficacy of endoscopic septoplasty with conventional septoplasty in which the complication rate was found to be less in the endoscopic septoplasty group.<sup>10</sup>

## CONCLUSION

In this study we found higher postoperative symptomatic relief and lesser rate of complications in endoscopic septoplasty group when compared to conventional group. Endoscopic septoplasty has the advantage of better illumination and magnification which aid in precise correction of the deformity. Endoscopic septoplasty is particularly useful for correction of posterior and high deviations of septum and for isolated spurs. Endoscopic septoplasty is also done as prior procedure in different intra-nasal surgeries requiring space for instrumentation. It is also useful for documentation of intra operative findings and serves as an efficient teaching tool. Conventional septoplasty on the other hand, has its own merits and cannot be completely replaced by endoscopic technique. It is specially useful in correcting the malunited septal fragments at cartilage level in grossly neglected injuries. The external deformity of nose and anterior deviations of septum are better corrected in conventional technique. As such, both endoscopic and conventional septoplasty procedures need to be done in combination in some cases for achieving optimal results. To sum up, endoscopic septoplasty surpasses conventional septoplasty in various aspects but it has its own learning curve and one requires mastering the technique.

*Funding: No funding sources*

*Conflict of interest: None declared*

*Ethical approval: The study was approved by the Institutional Ethics Committee*

## REFERENCES

1. Gleeson M, Scott-Brown W. Scott-Brown's otorhinolaryngology, head and neck surgery. 7th edn. London: Hodder Arnold; 2008: 1574.
2. Maran AGD. Septoplasty. *J Laryngol Otol.* 1974;88:393-402.
3. Cantrell H, Limited septoplasty for endoscopic sinus surgery. *Otolaryngol Head Neck Surg.* 1997;116:274-7.
4. Sautter NR, Smith TL: Endoscopic Septoplasty. *Otolaryngol Clin North Am.* 2009;42(2):253-60.
5. Lanza DC, Rosin DF, Kennedy DW. Endoscopic septal spur resection. *Am J Rhinol.* 1993;7(5):213-6.
6. Muhammad IA, Nabil-Ur Rahman. Complications of the surgery for deviated nasal septum. *J Coll Physicians Surgery Pak.* 2003;13(10):565-8.
7. Nayak DR, Balakrishnan R, Murthy DK. An endoscopic approach to the deviated nasal septum-a preliminary study. *JLO.* 1998;112:934-9.
8. Aranachlam PS, Kitcher E, Gray J. Nasal septal surgery: evaluation of symptomatic and general health outcomes. *Clin Otolaryngol.* 2001;26(5):367-70.
9. Park DH, Kim TM, Han DG. Endoscopic –assisted correction of the deviated nose aesthetic. *Plast Surg.* 1988;22(3):190-5.
10. Rajguru R, Singh I, Galagali JR, Singh A. Septoplasty techniques- conventional versus endoscopic: our experience. *Int J Otorhinolaryngol Head Neck Surg.* 2017;3:990-6.

**Cite this article as:** Suraneni VR, Kudamala S, Srikanth K. Conventional vs. endoscopic septoplasty: our experience. *Int J Otorhinolaryngol Head Neck Surg* 2018;4:403-8.