

## Case Report

# Classical presentation of Ackerman's tumour of tongue: a case report

Ravi D., Hanumanth Prasad M., Madhuri M. Gudikote\*, Balaji N. K., Sowmya T. R.

Department of ENT, Mandya Institute of Medical Sciences, Mandya, Karnataka, India

**Received:** 08 December 2017

**Revised:** 12 January 2018

**Accepted:** 16 January 2018

**\*Correspondence:**

Dr. Madhuri M. Gudikote,

E-mail: madhuri5291@gmail.com

**Copyright:** © the author(s), publisher and licensee Medip Academy. This is an open-access article distributed under the terms of the Creative Commons Attribution Non-Commercial License, which permits unrestricted non-commercial use, distribution, and reproduction in any medium, provided the original work is properly cited.

### ABSTRACT

Ackerman's tumour also called verrucous carcinoma (VC) is a controversial manifestation of well differentiated squamous cell carcinoma (SCC). It manifests as proliferative cauliflower like growth which is characteristic. Histologically it has a deceptively benign microscopic appearance. Hence it requires expertise for diagnosis. Although VC is illustrated as a benign lesion with minimum aggressive potential, over a period of time it can evolve into SCC. We report here a case of verrucous carcinoma of tongue in a young male with a history of tobacco chewing.

**Keywords:** Ackerman, Verrucous, Tongue

### INTRODUCTION

Verrucous Carcinoma (VC) or Ackerman's tumour is a controversial manifestation of well differentiated Squamous Cell Carcinoma (SCC). It is known to occur most commonly in the oral cavity which accounts to 2-12%.<sup>1</sup> Higher incidence of mucosal verrucous carcinoma of the head and neck region has been found to occur in those who use both inhaled and smokeless tobacco. Betel nut chewing and poor dental hygiene have also been considered as risk factors in the development of verrucous carcinoma in this region. Verrucoid or warty appearing lesions also have human papilloma virus (HPV) as one of the etiological factor.<sup>2</sup>

Verrucous carcinoma is described as a warty and exophytic lesion that arises from a broad base. It has a superficial spreading growth, but can be deeply infiltrative extending into muscle, cartilage or bone. Histologically, verrucous carcinoma lacks significant atypia and is characterized by blunt incursions and an expansile advancing margin sometimes showing brisk lymphocytic response.

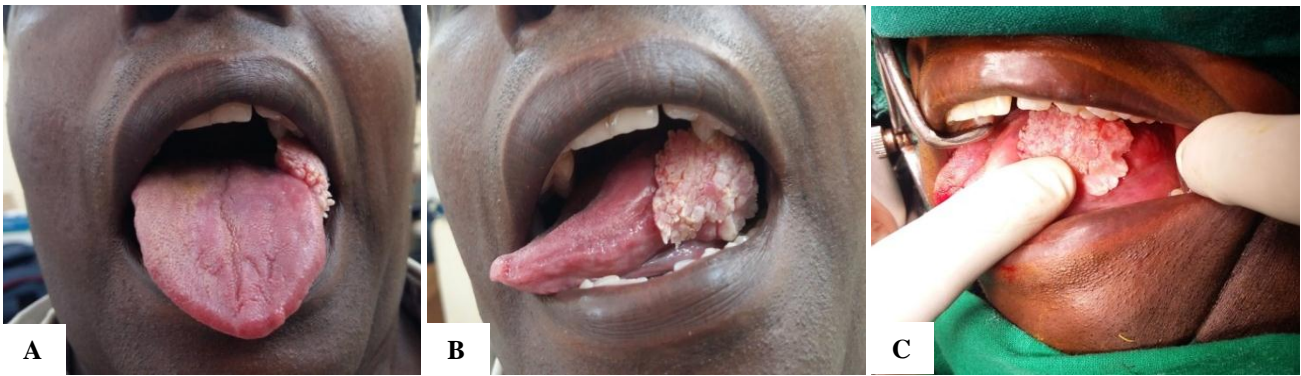Incisional biopsy diagnosis of verrucous carcinoma is problematic as it may be indistinguishable from benign squamo-proliferative lesions on superficial or limited volume material.<sup>1</sup>

Controversy has persisted regarding the appropriate treatment for verrucous carcinoma since the time it was first reported by Ackerman in 1948. Most investigators have suggested surgical excision as the treatment of choice.<sup>2</sup>

### CASE REPORT

A 30 year old gentleman with history of Tobacco chewing presented to our out-patient department with history of swelling in the left side of tongue since 3 months. It was insidious in onset and gradually progressive in size.

On examination a warty exophytic lesion was seen in the left side of dorsum and left lateral border of tongue measuring 3×3 cms, hard in consistency, fixed to tongue and non-tender.

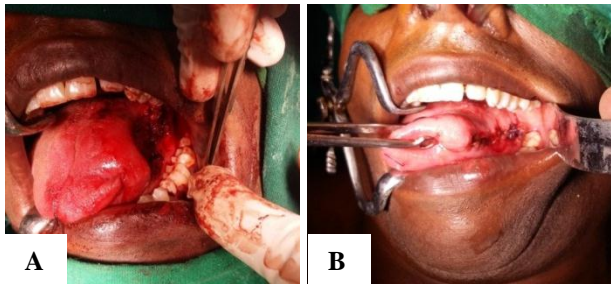


**Figure 1 (A-C): Images showing the lesion over the dorsum and left lateral border of the tongue.**

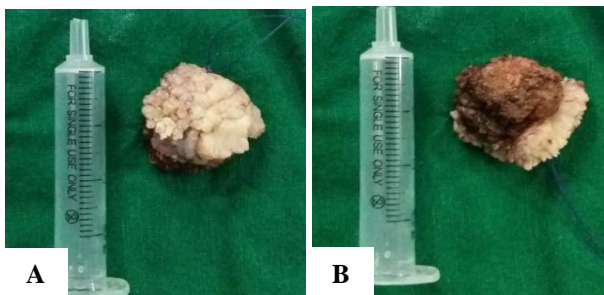Rest of the examination of oral cavity was normal. No palpable lymph nodes in the neck.

An Incisional biopsy was done which was suggestive of benign squamous papilloma. Plain CT scan of neck was done which was normal.

Patient was planned for wide local excision under general anesthesia. Wide local excision was done followed by primary closure. Post-operative period was uneventful. Excised mass was sent for histopathological evaluation.



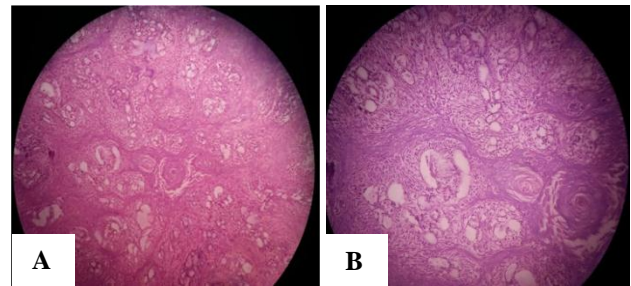
**Figure 2: Intraoperative image showing sutured wound.**



**Figure 3: Surgical specimen showing a cauliflower like mass.**

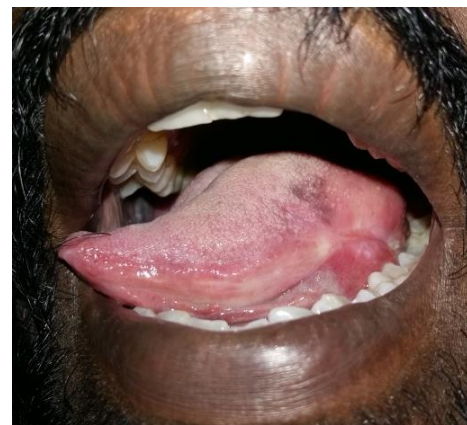Histopathology revealed tumour of squamoid nature, with marked acanthosis, hyperkeratosis and elongation of rete ridges. Tumour cells showed large vesicular nuclei with nucleoli. The dermis showed marked lymphocytic

infiltrates beneath the rete ridges. Features suggestive of well differentiated squamous cell carcinoma.



**Figure 4: Microscopic picture showing features of well differentiated squamous cell carcinoma. A= Low power magnification; B= High power magnification.**

Patient is on regular follow up every 3 months and is disease free till date.



**Figure 5: Postoperative image at 6 months showing healed wound.**

## DISCUSSION

Verrucous carcinoma (VC) is an uncommon variant of squamous cell carcinoma. It is characterised by proliferative outgrowing clinical appearance of the tumor. It was first described by Ackermann in 1948 and hence

the name.<sup>3</sup> VC accounts for 2–12 % of the oral cancers and is seen more commonly in males above sixth decade of life.<sup>2,4</sup>

Its slow growth, rare dysplasia and lack of metastasis distinguishes it from squamous cell carcinoma<sup>5</sup>

Chewing betel nut, tobacco, poor oral hygiene and human papilloma virus infection have been implicated as the various etiological factors in the causation of verrucous carcinoma.<sup>6</sup>

Histopathologically, verrucous carcinoma has a deceptively benign microscopic appearance. It is characterized by wide and elongated rete ridges that appear to push into the underlying connective tissue. Abundant keratin production, papillary surface and parakeratin plugs between the surface projections with an intense infiltrate of chronic inflammatory cells in the connective tissue are seen which is in accordance to the histological features of our case. Individual cells are rarely dysplastic, thus the pathologist must very careful to evaluate the overall histomorphologic configuration of the lesion to arrive at a correct diagnosis.<sup>5</sup>

Since areas of squamous differentiation are often missed even with adequate biopsy, verrucous carcinoma becomes an extremely challenging pathological diagnosis.<sup>4</sup>

Verrucous hyperplasia needs to be distinguished from verrucous carcinoma as it is considered as a forerunner of verrucous carcinoma, and transition is so consistent that the hyperplasia, once diagnosed, should be treated as verrucous carcinoma.<sup>7</sup> So, patients diagnosed with verrucous hyperplasia need to be closely followed up. Differential diagnosis can be made histologically, but a biopsy specimen should be sufficient for correct diagnosis. Verrucous hyperplasia is generally superficial to normal epithelium, whereas verrucous carcinoma extends more deeply.<sup>8-10</sup> In verrucous carcinoma, regional lymph nodes are often tender and enlarged because of inflammatory involvement which simulates a metastatic tumor.<sup>11</sup>

Surgery is the treatment of choice. Although an optimal disease control can be achieved by surgery only, frequent revision is required due to the increased risk of second tumours.<sup>12</sup> Debate continues regarding the role for radiation therapy in management.

## CONCLUSION

Benign squamo-proliferative lesions are indistinguishable from verrucous carcinoma on biopsy from limited material. Hence a high index of pathological

suspicion and good clinical knowledge are prerequisites for early diagnosis and management. Verrucous carcinoma can also occur in younger age group and hence should not be under-evaluated in such cases.

*Funding: No funding sources*

*Conflict of interest: None declared*

*Ethical approval: Not required*

## REFERENCES

1. Moorthy R, Warfield AT. Head and neck pathology In: Stell and Maran's Textbook of Head and Neck Surgery and Oncology 5th ed. Florida: CRC Press; 2012: 83-118.
2. Koch BB, Trask DK, Hoffman HT, Karnell LH, Robinson RA, Zhen W, et al. National survey of head and neck verrucous carcinoma. *Cancer* 2001;92(1):110–20.
3. Ackerman LV. Verrucous carcinoma of the oral cavity. *Surg.* 1948;23:670–8.
4. Walvekar RR, Chaukar DA, Deshpande MS, Pai PS, Chaturvedi P, Kakade A, et al. Verrucous carcinoma of the oral Cavity: a clinical and pathological study of 101 cases. *Oral Oncol.* 2009;45(1):47–51.
5. Neville BW, Damm DD, Allen CM, Bouquot JE. Oral and maxillofacial pathology. 2nd ed. Philadelphia: WB Saunders; 2002: 388-397, 422-423.
6. Depprich RA, Handschel JG, Fritzeimer CU. Hybrid verrucous carcinoma of the oral cavity: A challenge for the clinician and the pathologist. *Oral Oncol.* 2006;42:85–90.
7. Eversole LR. Papillary lesions of the oral cavity: relationship to human papillomaviruse. *J Calif Assoc.* 2000;28:922-927.
8. Shear M, Pindborg JJ. Verrucous hyperplasia of the oral mucosa. *Cancer.* 1980;46:1855-62.
9. Murrah VA, Batsakis JG. Proliferative verrucous leukoplakia and verrucous hyperplasia. *Ann Otol Rhinol Laryngol* 1994;103:660–3.
10. McClure DL, Gullane PJ, Slinger RP, Wysocki GP. Verrucous carcinoma-changing concepts in management. *J Otolaryngol.* 1984;13:7-12.
11. Shafer WG, Hine MK, Levy BM. Benign and malign tumors of the oral cavity In: A Textbook of Oral Pathology. Philadelphia, WB Saunders Company; 1983: 127-130.
12. Liao CT, Kang CJ, Chang JT, Wang HM, Ng SH, Hsueh C, et al. Survival of second and multiple primary tumors in patients with oral cavity squamous cell carcinoma in the betel quid chewing area. *Oral Oncol.* 2007;43:811-9.

**Cite this article as:** Ravi D, Hanumanth PM, Gudikote MM, Balaji NK, Sowmya TR. Classical presentation of Ackerman's tumour of tongue: a case report. *Int J Otorhinolaryngol Head Neck Surg* 2018;4:597-9.