

## Original Research Article

DOI: <http://dx.doi.org/10.18203/issn.2454-5929.ijohns20175633>

# Present scenario of laryngeal tuberculosis

Marina Saldanha<sup>1\*</sup>, Natashya H. Sima<sup>2</sup>, Vadisha S. Bhat<sup>1</sup>,  
Shrinath D. Kamath<sup>1</sup>, Rajeshwari Aroor<sup>1</sup>

Department of Otorhinolaryngology and Head and Neck Surgery, <sup>1</sup>K.S. Hegde Medical Academy, Mangalore, <sup>2</sup>St. John's Medical College, Bangalore, Karnataka, India

**Received:** 24 October 2017

**Revised:** 25 November 2017

**Accepted:** 27 November 2017

### \*Correspondence:

Dr. Marina Saldanha,

E-mail: [saldanhamarina@gmail.com](mailto:saldanhamarina@gmail.com)

**Copyright:** © the author(s), publisher and licensee Medip Academy. This is an open-access article distributed under the terms of the Creative Commons Attribution Non-Commercial License, which permits unrestricted non-commercial use, distribution, and reproduction in any medium, provided the original work is properly cited.

## ABSTRACT

**Background:** The objectives of the study were to document the presentation of laryngeal tuberculosis, response to anti-tubercular treatment and objective evaluation of larynx during and post anti-tubercular treatment.

**Methods:** A before and after treatment study including 15 subjects with laryngeal tuberculosis treated in our tertiary health care centre during a three year study period. Clinical presentation, management, subjective self-assessment of voice and objective assessment of larynx by videostroboscopy at the beginning, at two months and at six months of anti-tubercular treatment were documented.

**Results:** Two patients had primary laryngeal tuberculosis and thirteen patients had laryngeal tuberculosis associated with pulmonary tuberculosis. Only one patient was immuno-compromised. Most common presenting symptom was hoarseness (93%). Ulcerative lesions were the most common clinical finding (87%) with the vocal cords being the commonest site involved (80%). All patients responded well to anti-tubercular treatment. Videostroboscopy showed an improvement in vocal cord lesions during treatment. Subjective assessment of voice after two months of anti-tubercular treatment showed marked improvement in voice. At completion of treatment, voice was better but all patients had complaints of residual hoarseness.

**Conclusions:** Primary laryngeal tuberculosis is less common in comparison to laryngeal tuberculosis secondary to pulmonary tuberculosis. With early diagnosis, the response to treatment is satisfactory. Videostroboscopy can be used as an effective tool in monitoring vocal cord changes during the follow-up period.

**Keywords:** Laryngeal tuberculosis, Hoarseness, Videostroboscopy

## INTRODUCTION

Tuberculosis of the larynx is a rare form of tuberculosis and accounts for less than 1% of the cases of extrapulmonary tuberculosis.<sup>1</sup> It has almost always been associated with pulmonary tuberculosis.<sup>2</sup> It is theorized that in cases of laryngeal tuberculosis of primary origin, the laryngeal disease is the result of direct invasion by inhaled tubercle bacilli.<sup>3,4</sup> The pathogenesis in cases secondary to pulmonary tuberculosis may be due to direct contact of the larynx with sputum laden bacilli which get deposited locally. Other modes of spread are

haematogenous or lymphatic.<sup>3</sup> Nowadays, the presentation of laryngeal tuberculosis without pulmonary tuberculosis is on the rise.<sup>5</sup> The presentation is usually with hoarseness, dysphagia and odynophagia.<sup>6,7</sup>

In tuberculosis, the lesions heal by fibrosis. In the larynx, during the healing process the fibrotic changes in the layers of lamina propria can affect the vibrations of the vocal cords and cause a change in quality of voice.<sup>6</sup>

Our study highlights the present scenario of laryngeal tuberculosis, the response to anti-tubercular treatment and

the subjective evaluation of voice and videostroboscopic findings of larynx before, after two months and at completion of anti-tubercular therapy.

## METHODS

### Patient selection

Ethical clearance was obtained from the Institutional ethics committee and informed consent was taken from all the participants. Participants included in the study were treated or referred to the Department of Otorhinolaryngology at K.S. Hegde Medical Academy, Mangalore between 2012 and 2015. Fifteen confirmed cases of Laryngeal tuberculosis based on clinical presentation, sputum acid-fast bacillus (AFB) and/or histopathology examination were included in the study.

### Data collection

Data collection included a detailed history, ENT examination and video laryngoscopy. Investigations like complete blood count, erythrocyte sedimentation rate (ESR), sputum AFB, chest x-ray were documented in all the participants. Laryngeal biopsy was taken in cases where laryngeal malignancy was suspected.

### Treatment

All patients were treated with Anti-tubercular treatment (ATT) according to Revised National Tuberculosis Control program (RNTCP) guidelines for six months.<sup>9</sup>

### Voice evaluation

15 subjects were included in the study out of which only six patients came for regular follow up after two months of intensive phase of anti-tubercular therapy and at six months at completion of treatment. Subjective evaluation of voice was done by asking the patient questions related to improvement in voice. Objective evaluation was done by videostroboscopy. Stroboscopic examination was done using a 90° rigid endoscope with ATMOS stroboscopic unit. The parameters included were fundamental frequency (fo), vibration, mucosal wave pattern, and closure pattern.

### Statistics

The data collected was entered into Microsoft excel spreadsheet and analyzed using IBM SPSS Statistics Version 22 (Armonk, NY:IBM Corp). Descriptive data was presented in the form of frequency and percentage. Repeated measures one way Anova was applied for the fundamental frequency by videostroboscopy.

## RESULTS

Fifteen patients with laryngeal tuberculosis were included in our study.

All patients were males. Age group ranging from 28 to 85 years with maximum number between 41-50 years (40%) (Table 1).

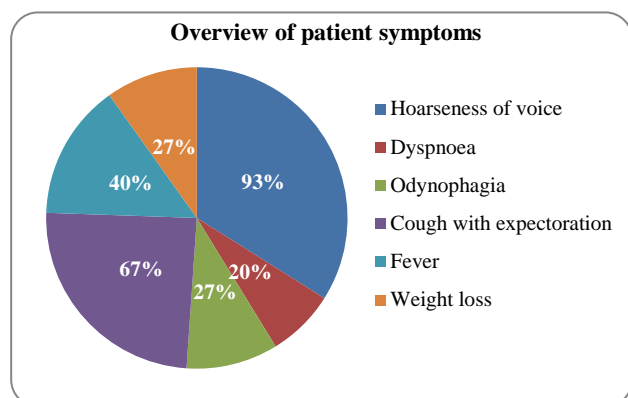
**Table 1: Overview of investigations.**

No.	Age	ESR	Sputum AFB	Chest X-ray	Histopathology
1.	49	86	+	Bilateral upper lobe lesion	Chronic granulomatous lesion
2.	45	130	+	Normal	Chronic granulomatous lesion
3.	51	25	-	Normal	Chronic granulomatous lesion
4.	43	80	+	Cavitary lesion in Rt upper lobe	
5.	85	45	+	Lt upper lobe infiltrates	
6.	57	20	+	Lt upper and lower lobe infiltrates	
7.	43	100	+	Rt middle and lower lobe infiltrates	Chronic granulomatous lesion
8.	36	60	+	Fibrocavitary lesion Rt upper lobe	
9.	44	22	+	Fibrocavitary lesion Rt upper lobe	
10.	60	95	+	Lt upper lobe consolidation	
11.	28*	50	+	Miliary tuberculosis	Chronic granulomatous lesion
12.	55	60	+	Bilateral upper lobe infiltrates	
13.	48	80	+	Bilateral upper lobe lesion	
14.	62	48	+	Cavitary lesion right upper lobe	
15.	42	22	-	Normal	Chronic granulomatous lesion

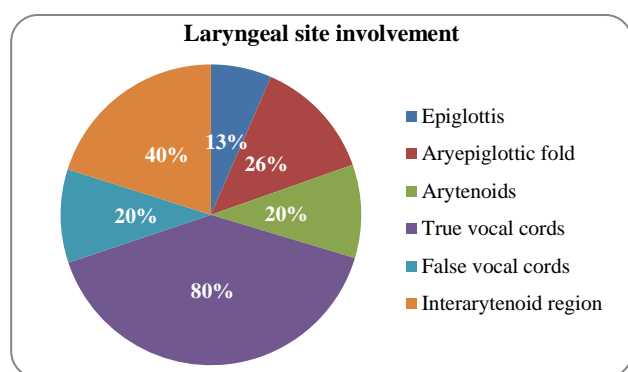
The most common symptom was hoarseness (93%). The other laryngeal symptom was odynophagia (27%) and dyspnoea (20%). The systemic features were cough with expectoration (67%), fever (40%) and weight loss (27%). The overview of patient's symptoms is shown in Figure 1.

The most common site of involvement was the true vocal cords (80%) followed by inter arytenoid area (40%). The distribution of laryngeal site involvement is shown in Figure 2. Based on macroscopic appearance, single lesion was noted in six patients: ulceration (n=4) and hyperaemia with oedema (n=2). Nine patients had

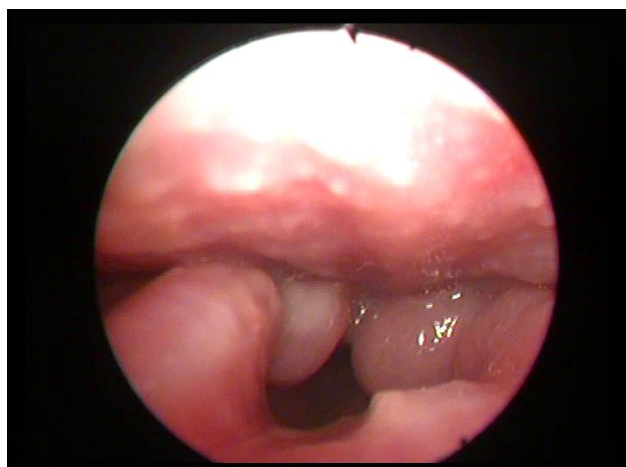
multiple macroscopic findings- ulceration, nodular lesions, hyperaemia and oedema (Figure 3 and 4).



**Figure 1: Pie chart depicting an overview of patient's symptoms.**



**Figure 2: Pie diagram showing overall laryngeal site involvement.**

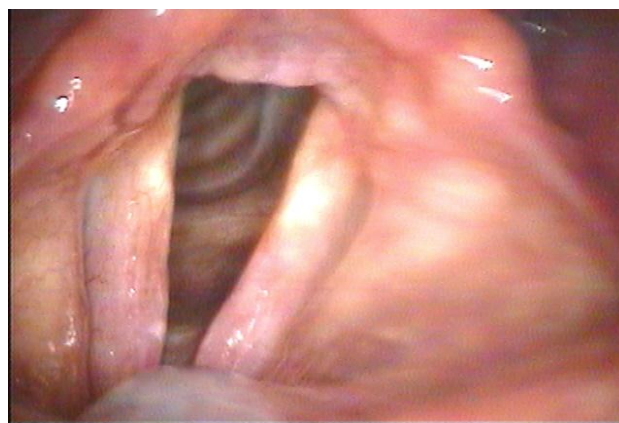


**Figure 3: Pseudoedema of glottis and arytenoids.**

Table 1 shows the details of the investigations done to confirm the diagnosis.

ESR was elevated in all cases. Sputum examination for acid-fast bacilli was found to be positive in 13 cases. The two cases which were diagnosed to be sputum negative

underwent laryngeal biopsy and were diagnosed to have primary laryngeal tuberculosis. Thirteen patients showed signs of pulmonary tuberculosis on chest X-ray. One patient had signs of pulmonary tuberculosis and association with human immunodeficiency virus. Four patients who had lesions suspicious of malignancy had undergone direct laryngoscopy and biopsy. Histopathology in all cases showed features consistent with tuberculosis.



**Figure 4: Congestion and irregular lesions on vocal cords and interarytenoid region.**

All patients took anti-tubercular treatment as per RNTCP. Sputum AFB was negative in all patients after six months of ATT. All patients showed improvement of symptoms after two months of intensive phase of ATT.

Objective evaluation of voice - only six patients had come for follow up at the stipulated time of two months and six months. Hence our analysis of the parameters of videostroboscopy was carried out on the basis of details of six patients.

1. *Fundamental frequency*: Repeated measures one way Anova was applied for the fundamental frequency and was found to show a significant improvement during the period of six months ( $p < 0.001$ ).
2. *Glottal closure*: Three patients had irregular glottal closure at presentation and the remaining three had normal glottal closure. At 2 months two patients had spindle glottal closure and at six months all six patients had normal glottal closure.
3. *Mucosal wave*: Before treatment three patients had mucosal wave absent in right vocal cord and present in left vocal cord, two patients had bilateral absent mucosal wave and only in one patient mucosal wave was present. After two months of treatment three patients showed improvement and normal mucosal wave pattern and at completion of treatment only one patient had left absent mucosal wave.
4. *Vibration*: Before treatment three patients had decreased right vocal cord vibrations and left vocal cord vibrations was normal. Two patients had left vocal cord decreased vibration and one patient had

absent vibration in both vocal cords. After two months of ATT reduced vibration was noticed in five cases. At completion of treatment three patients vocal cord vibration was normal and three cases still had reduced vibration.

All patients noted an improvement in voice after two months of intensive phase of ATT. At six months after completion of treatment they still gave history of persistence of hoarseness.

## DISCUSSION

Tuberculosis is a treatable communicable disease. It is one of the common granulomatous infections of the head and neck region caused by *Mycobacterium tuberculi* and is a leading cause of death due to a single infective agent.<sup>10</sup> Although the incidence of tuberculosis has been on the decline due to the introduction of effective chemotherapeutic agents there has been an increase in the incidence of extra pulmonary tuberculosis in the head and neck region due to the rise in the incidence of HIV infection.<sup>6,7,10</sup>

In laryngeal tuberculosis initially there is exudation and hyperaemia in the subepithelial layers following which mononuclear round cells infiltrate the subepithelial layers causing pseudoedema. It goes through stages of granuloma formation, caseation necrosis, formation of shallow ulcers and these ulcers heal by fibrosis. At the time of presentation the laryngeal findings may vary from vocal cord congestion to ulcer formation to granuloma formation.

In our study, two patients were diagnosed with primary laryngeal tuberculosis. They presented with hoarseness and odynophagia. On videolaryngoscopy both patients had signs of chronic laryngitis. Persistence of hoarseness prompted the clinician to perform direct laryngoscopy and biopsy and the report came as tuberculosis. Response to anti-tubercular treatment was satisfactory. On reviewing literature on primary laryngeal tuberculosis limited articles have been published because it is rare.<sup>4,7</sup>

Maximum patients were in the age group 41-50 years. These finding are similar to other studies which documented ages ranging in the fourth and fifth decade of life.<sup>5,8</sup>

Hoarseness of voice was found to be the most common symptom which was found in fourteen (93%) cases. This finding is similar to that of other studies.<sup>8,10</sup>

Various studies in the past had stated that mycobacterium tuberculosis usually involves the posterior part of the larynx with lesions usually found to involve the inter-arytenoid region, the arytenoids and the posterior glottis and was believed to be due to pooling of infected sputum in the recumbent position.<sup>5,8,10</sup> In our study however we found the vocal cords (diffuse) to be the most common

site of involvement which was similar to the findings of Shin et al and Clery et al.<sup>8,12</sup> Based on macroscopic appearance, Shin et al classified their fibreoptic findings into ulcerofungative mass lesion, whitish ulcerative lesion, nonspecific inflammatory lesion and polypoid lesion and found that ulcerative lesions were the commonest (40.9%) in their study. In our study we observed that both in single and multiple lesions in the larynx, ulcerative lesions was the most common finding.<sup>8</sup>

Sputum AFB, ESR, chest X-ray and direct laryngoscopy all contribute to the confirmation of diagnosis. Direct laryngoscopy and biopsy was done in four cases which had findings suspicious of malignancy. Considering the videolaryngoscopy and chest X-ray findings, we observed that in two cases with fibrocavitary lesion on right lung, there was ulceration only on the right vocal cord; and in three patients with active bilateral lung lesions, there was diffuse involvement. This may be because of increased quantities of acid-fast bacilli being coughed up in sputum into that half of the larynx. To substantiate this it has to be validated in more studies. Response to ATT was satisfactory in all the cases.

Videostroboscopy was done in six patients and the results show that the fundamental frequency (fo) has improved with treatment in all the cases. The glottal closure, vibration and mucosal wave parameters have all improved with treatment. The findings are similar to Ozudogru in his case report which showed an improvement in all parameters by stroboscopy. Ling et al in his article mentions the videostroboscopic findings in cases of laryngeal tuberculosis show a reduced mucosal wave and vibrations at the start of treatment. Videostroboscopy can be used as an adjunct to diagnosis in cases of diseases of the larynx but it cannot substitute biopsy to confirm the cause of the lesion.<sup>13</sup> In our case series we have documented that there has been an improvement in all parameters with ATT.

Tuberculosis of larynx can cause irreversible fibrotic changes in lamina propria of the vocal cord involved. It may cause a breathy voice due to the scarring process which can have a negative impact on vocal cord vibrations and compromise voice quality.<sup>6</sup> On subjective evaluation of voice after two months all patients said that their voice improved. At completion of treatment they said that the voice had not come back to their original status although there was resolution of laryngeal lesions on videolaryngoscopy. In patients whom voice plays a major role in their occupation they can be advised for speech- language therapy.

The limitation of our study is that we have not done acoustic analysis of voice.

## CONCLUSION

Laryngeal tuberculosis has varied clinical presentations. Primary laryngeal tuberculosis is less common in



comparison to laryngeal tuberculosis secondary to pulmonary tuberculosis. With early diagnosis, the response to treatment is satisfactory; however hoarseness of voice may persist even after completion of anti-tubercular treatment. Videostroboscopy can be used as an effective tool in monitoring vocal cord changes during the follow-up period.

*Funding: No funding sources*

*Conflict of interest: None declared*

*Ethical approval: The study was approved by the Institutional Ethics Committee*

## REFERENCES

1. Alvarez S, McCabe WR. Extrapulmonary tuberculosis revisited. A review of experience at Boston city and other hospitals. *Medicine*. 1984;63(1):25-55.
2. Lee KC, Schecter G. Tuberculosis infections of the head and neck. *Ear Nose Throat J*. 1995;74:395-9.
3. Mehndiratta A, Bhat P, D'Costa L, Mesquita AM, Nadkarni N. Primary Tuberculosis of larynx. *Indian J Tuberc*. 1997;44:211-2.
4. Kiakojuri K, Roushan M. Laryngeal tuberculosis without pulmonary involvement. *Caspian J Internal Med*. 2012;3(1):397-9.
5. Nishiike S, Irifune M, Sawada T, Doi K, Kubo T. Laryngeal tuberculosis: A report 15 cases. *Annals of Otol Rhinol Laryngol*. 2002;111(10):916-8.
6. Ozudogru E, Çakli H, Altuntas EE, Gurbuz MK. Effects of laryngeal tuberculosis on vocal fold functions: case report. *Acta Otorhinolaryngologica Italica*. 2005;25(6):374-7.
7. Verma SK, Verma SK, Sanjay. Laryngeal tuberculosis clinically similar to laryngeal cancer. *Lung India*. 2007;24:87-9.
8. Shin JE, Nam SY, Yoo SJ, Kim SY. Changing trends in clinical manifestations of laryngeal tuberculosis. *Laryngoscope*. 2000;110:1950-3.
9. Sandhu GK. Tuberculosis: Current Situation Challenges and Overview of its control program in India. *J Global Infect Dis*. 2011;3:143-50.
10. Michael RC, Michael JS. Tuberculosis in Otorhinolaryngology: clinical presentation and diagnostic challenges. *Int J Otolaryngol*. 2011;2011:686894.
11. Kandilors DC, Nikolopoulos TP, Ferekidis EA, Tsangaroulakis A, Yiotakis JE, Davilis D, et al. Laryngeal tuberculosis at the end of the 20th century. *J Laryngol Otol*. 1997;111(7):619-21.
12. Cleary KR, Batsakis JG. Mycobacterial disease of the head and neck: current perspective. *Annals of Otolaryngology, Rhinol Laryngol*. 1995;104:830-3.
13. Ling L, Zhou S-H, Wang SQ. Changing trends in the clinical features of laryngeal tuberculosis: a report of 19 cases. *Int. J Infect Dis*. 2010;14(3):23-35.

**Cite this article as:** Saldanha M, Sima NH, Bhat VS, Kamath SD, Aroor R. Present scenario of laryngeal tuberculosis. *Int J Otorhinolaryngol Head Neck Surg* 2018;4:242-6.