

Case Report

Chondroid syringoma of face (nasomaxillary groove): case report

Chandra Shekar Reddy, Gowri Sankar Marimuthu*, Sivaraman Ganesan, Arun Alexander

Department of ENT, Jawaharlal Institute of Post-Graduation Medical Education and Research (JIPMER), Pondicherry, India

Received: 24 September 2017

Accepted: 30 October 2017

***Correspondence:**

Dr. Gowri Sankar Marimuthu,

E-mail: drent5555@gmail.com

Copyright: © the author(s), publisher and licensee Medip Academy. This is an open-access article distributed under the terms of the Creative Commons Attribution Non-Commercial License, which permits unrestricted non-commercial use, distribution, and reproduction in any medium, provided the original work is properly cited.

ABSTRACT

Chondroid syringoma, is a benign neoplasm of sweat gland origin with an overall reported incidence of 0.01-0.098 percent. These tumours being rare can easily be misdiagnosed and should be included in the differential diagnosis of any slowly growing nodule in the skin of the face. The diagnosis is confirmed after histopathologic examination of tissue obtained by excisional biopsy. Treatment of choice is local surgical excision with a cuff of normal tissue, in order to prevent recurrence. We present a case of chondroid syringoma of the face (nasomaxillary groove), highlighting the rarity of the tumour and the surgical incision resulting in excellent cosmetic result.

Keywords: Chondroid syringoma, Benign tumors face

INTRODUCTION

Chondroid syringoma, also known as mixed tumor of the skin, is a benign neoplasm of sweat gland origin. The incidence of chondroid syringoma is low, and has been reported at 0.01-0.098 percent, being a rare clinical entity.¹ The most common sites of occurrence are the nose, cheek, upper lip, scalp, forehead, and chin.² The lesion commonly seen between the age of 20 and 60 years with a distinct male predominance.¹ Chondroid syringoma appears clinically as a slowly growing, painless or subcutaneous nodule. Lesions are firm and adherent to overlying skin but distinct from underlying structures.

We report a very rare case of chondroid syringoma located in face-left nasomaxillary groove. This location has not been mentioned in the literature for the last twenty years.

CASE REPORT

A 60-year-old female patient consulted us for a slow growing exophytic lesion in the left nasomaxillary groove

for 30 yrs, obscuring her lower field of vision for the past 6months.

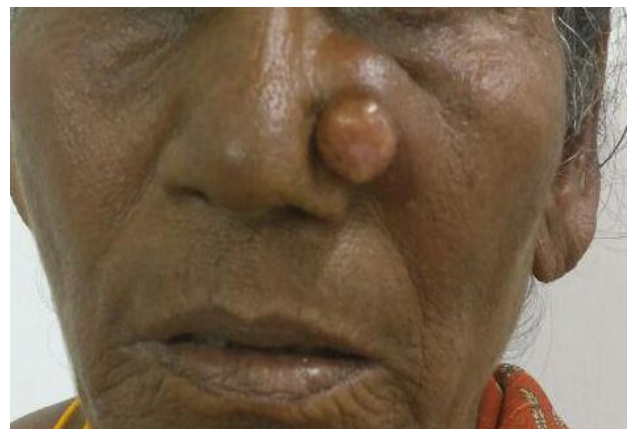

Figure 1: Lesion in left nasomaxillary groove.

On examination the lesion appeared to be dumb-bell shaped with an exophytic and endophytic component. The exophytic component was 1.5×1.5 cms with firm adherent skin, the endophytic component being 3×3 cms,

buried under the free soft tissue and skin. Contrast enhanced CT scan showed a well-defined smooth margined non enhancing exophytic soft tissue lesion involving skin and subcutaneous plane of left cheek with no infiltration into adjacent structures suggestive of benign lesion of the skin. FNAC of the swelling showed chondroid syringoma.

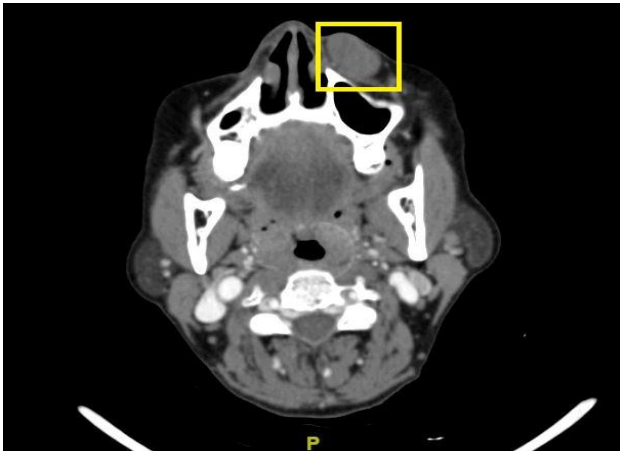


Figure 2: Contrast enhanced CT view of lesion.

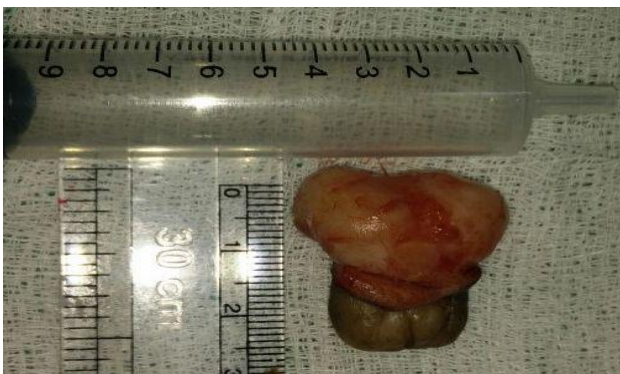

Figure 3: Excised specimen.

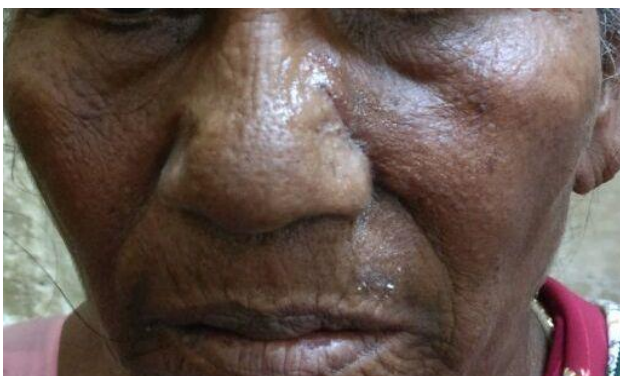


Figure 4: post op-cosmetically acceptable scar buried in nasomaxillary groove.

Under local infiltration anesthesia the lesion was excised intoto (exophytic portion with adherent skin and endophytic portion free of skin). The incision-an elliptical type-was planned so that the scar developing would be

buried in the nasomaxillary groove. Skin was closed with 5-0 prolene. Post op period was uneventful. The excised specimen was dumbbell shaped measuring 4.5×2.5 cms.

DISCUSSION

In 1859, Theodor Billroth first described chondroid syringoma as “an entity having the same histopathologic properties of mixed tumors of the salivary glands.”³ Hirsch and Helwig coined the term “chondroid syringoma,” because of the histologic appearance of sweat gland features in a cartilage-like stroma.² Chondroid syringoma is derived from epithelial and mesenchymal cells and comprises glandular elements of eccrine or apocrine type.¹ Hirsch and Helwig defined the following histologic criteria for the characterization of chondroid syringoma: (1) nests of cuboidal or polygonal cells; (2) intercommunicating tubuloalveolar structures lined with 2 or more rows of cuboidal cells; (3) ductal structures composed of 1 or 2 rows of cuboidal cells; (4) occasional keratinous cysts; and (5) a matrix of varying composition. Chondroid syringoma may exhibit all 5 characteristics or manifest only some, with the most common feature being the nests of cuboidal or polygonal cells.

The gross appearance typically being described as a slow-growing, solitary, non-ulcerating mass ranging in size from 0.5 to 3.0 cm, while lesions larger than 3.0 cm are associated with a greater likelihood of malignancy.⁴ Malignant chondroid syringoma typically arise de novo and not from a preexisting benign chondroid syringoma.⁴ A clinical differential diagnosis may include implantation dermoid, sebaceous cyst, compound naevus, clear cell hidradenoma, cystic basal cell carcinoma, neurofibroma, and dermatofibroma. The deep variant of this tumour could be confused with a pleomorphic adenoma of major or minor salivary gland origin.⁵

The diagnosis of chondroid syringoma is confirmed after histologic examination of tissue obtained by excisional biopsy. However, if presentation is questionable, a fine-needle aspiration may be of value since chondroid syringoma has been distinguished using this technique.⁶ Fine-needle aspiration has its limitations, such as sampling errors for histologic analysis that will require an experienced cytologist.⁶ Treatment of choice is local surgical excision with a cuff of normal tissue, in order to prevent recurrence. If the tumor has been completely excised and is benign, long-term follow up is not indicated. Follow up is indicated only if the excision is incomplete or if there is indication of malignant change, which is rare but has been reported in the literature.⁷

CONCLUSION

Chondroid syringoma is an uncommon mixed tumor of the skin, usually encountered on the face. These tumours being rare can easily be misdiagnosed and should be included in the differential diagnosis of any slowly

growing nodule on the face in a patient attending the otorhinolaryngology clinic. The treatment of choice is local excision. Recurrence is attributed to incomplete excision or malignant transformation which although being rare has been reported.

Clinical significance

Chondroid syringoma, is a benign neoplasm of sweat gland origin with an overall reported incidence of 0.01-0.098 percent. These tumours being rare can easily be misdiagnosed and should be included in the differential diagnosis of any slowly growing nodule in the skin of the face.

Funding: No funding sources

Conflict of interest: None declared

Ethical approval: Not required

REFERENCES

1. Yavuzer R, Bařterzi Y, Sari A, Bir F, Sezer C. Chondroid syringoma: a diagnosis more frequent than expected. *Dermatol Surg*. 2003;29(2):179–81.
2. Hirsch P, Helwig EB. Chondroid syringoma. Mixed tumor of skin, salivary gland type. *Arch Dermatology*. 1961;84:835–47.
3. Di Mare G, Vassallo L, Voglino C, Bettarini F, Mariani F, De Stefano A, et al. Chondroid syringoma: report of a case with uncommon location. *J Med Diagn Methods*. 2014;3(1):153.
4. Sungur N, Uysal A, Gumus M, Kocer U. An unusual chondroid syringoma. *Dermatol Surg*. 2003;29(9):977–9.
5. Gottschalk-Sabag S, Glick T. Chondroid syringoma diagnosed by fine-needle aspiration: a case report. *Diagnostic Cytopathol*. 1994;10(2):152–5.
6. Skoro M, Ostovic KT, Cikara I, Muller D, Novak NP, Virag M. Fine needle aspiration cytology of chondroid syringoma. *Coll Antropol*. 2010;34(2):687–90.
7. Vasileiadis I, Kapetanakis S, Petousis A, Karakostas E, Simantirakis C. Rapidly growing chondroid syringoma of the external auditory canal: report of a rare case. *Case Rep Med Vol*. 2011 2011:589680.

Cite this article as: Reddy CS, Marimuthu GS, Ganesan S, Alexander A. Chondroid syringoma of face (nasomaxillary groove): case report. *Int J Otorhinolaryngol Head Neck Surg* 2018;4:289-91.