

## Case Report

# Optic nerve decompression - role in preventing traumatic ischaemic optic neuropathy: case report

Manish Munjal<sup>1\*</sup>, Japneet Kaur<sup>1</sup>, Porshia Rishi<sup>1</sup>, Nitika Tuli<sup>1</sup>,  
Iti Bharadwaj<sup>1</sup>, Shubham Munjal<sup>2</sup>

<sup>1</sup>Department of Otorhinolaryngology, Head and Neck Surgery, <sup>2</sup>Department of Anatomy, Dayanand Medical College, Ludhiana, Punjab, India

**Received:** 04 February 2020

**Accepted:** 15 June 2020

### \*Correspondence:

Dr. Manish Munjal,

E-mail: [manishmunjaldr@yahoo.com](mailto:manishmunjaldr@yahoo.com)

**Copyright:** © the author(s), publisher and licensee Medip Academy. This is an open-access article distributed under the terms of the Creative Commons Attribution Non-Commercial License, which permits unrestricted non-commercial use, distribution, and reproduction in any medium, provided the original work is properly cited.

## ABSTRACT

Traumatic optic neuropathy is a complication that arises due to head injury, high velocity road traffic accidents causing maxillofacial trauma. Due to involvement of optic nerve which endangers vision, there is a race against to save the vision. Endoscopic optic nerve decompression is a useful procedure for optic nerve decompression. We report a case of ischaemic optic neuropathy following road traffic accident, who underwent endoscopic optic nerve decompression within 6 hours of injury.

**Keywords:** Traumatic optic neuropathy, Optic nerve decompression, Endoscopic transnasal transsphenoid approach

## INTRODUCTION

Traumatic optic neuropathy (TON) is a devastating potential complication of closed head injury. The hallmark of an optic neuropathy, traumatic or otherwise, is a loss of visual function, which can manifest by subnormal visual acuity, visual field loss, or color vision dysfunction,

Vision loss associated with TON can be partial or complete and temporary or permanent.<sup>1</sup>

Historically, the 3 treatment paradigms advocated for TON are observation, medical corticosteroid therapy, or optic canal decompression.<sup>2</sup>

Recent advances in endoscopic nasal surgery and availability of advanced instruments have redefined endoscopic surgical approaches for TON. Currently, endoscopic optic nerve decompression via an intranasal

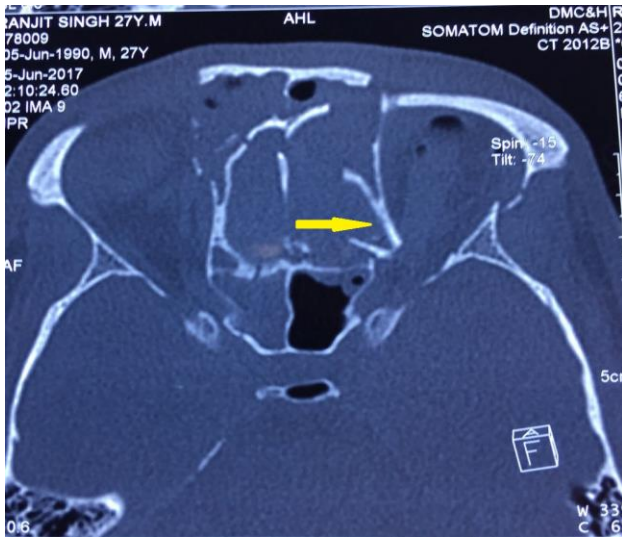
transethmoidal or transsphenoidal approach has gained popular support.

We report a case of 24 year old male with one sided visual loss who presented in the ENT emergency with maxillofacial trauma following high velocity road traffic accident.

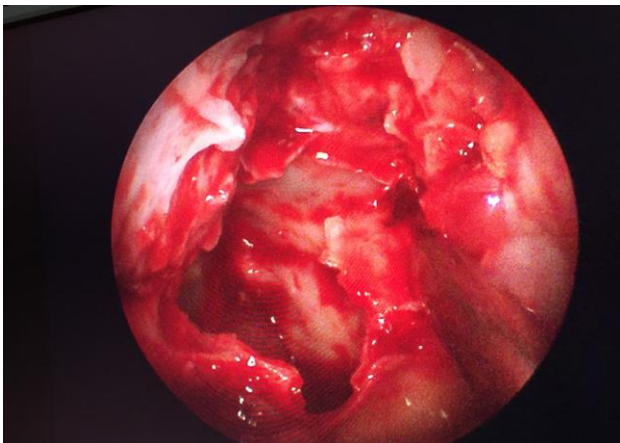
## CASE REPORT

24 year old male patient presented to the casualty department after 6 hours with complex maxillofacial trauma following high impact road traffic accident. Patient complained of blurring in vision of the left side. At the time of examination patient had perception of fingers at 1 metre distance. Radiological investigations were ordered and within 1 hour the vision deteriorated to light perception on left side. Computed tomography scan of orbit with paranasal sinus showed multiple comminuted fractures and fracture of the medial and lateral orbital

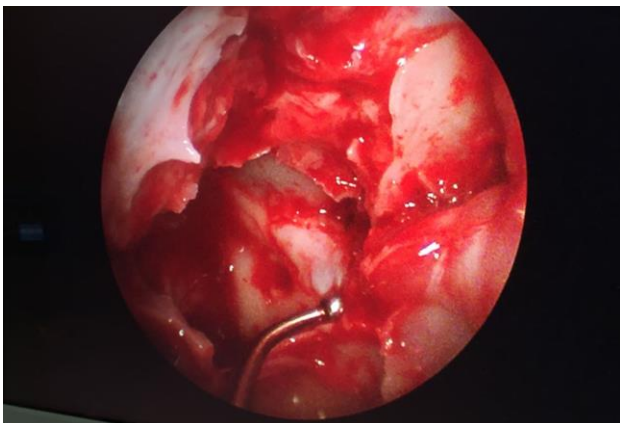
walls causing impingement of the fracture fragments on the optic nerve (Figure 1).



**Figure 1: Bone fragment entering orbit impinging on the optic nerve (yellow arrow).**



**Figure 2: The periosteum being removed from the optic nerve.**



**Figure 3: Probe below the intracanalicular segment, intraorbital part (green arrow), intracanalicular part (blue), intracranial part (black).**

Patient was immediately shifted to the operating room. Urgent surgical intervention was undertaken under general anaesthesia. Intraoperatively (Figure 2 and 3). The shattered septae of anterior and posterior ethmoid cells were extracted. Clotted blood was cleared. Medial orbital wall, the lamina papyracea was lifted off the orbital periosteum with a blunt elevator. The optic tubercle bone elevated with a curette followed by exposure of the sphenoid segment of the optic nerve. The annulus of Zinn was cut, thus exposing the oedemous and engorged portion of the intra canalicular and intracranial regions. Haemostasis attained by adrenaline soaked atraumatic cotton patties. Postoperative period was uneventful and patient attained ability to count fingers in the evening. Anti-inflammatory intravenous medications were continued for a week, followed by oral medications.

## DISCUSSION

Length of optic nerve varies 35-55 mm from the eyeball to the chiasma (intraocular part 1 mm, intraorbital part 25 mm, intracanalicular part 4-10 mm and intracranial part 10 mm).<sup>3</sup> TON occurs due to injury to optic nerve following complex maxillofacial trauma. Mode of injury may be direct i.e. penetrating trauma resulting in physical disruption of optic nerve, or indirect i.e. when traumatic /compressive forces are transmitted to the optic nerve with minimal disruption of the physical continuity of the nerve. TON can also be classified depending on the location of the injury for e.g. head of optic nerve, intraorbital segment, intracanalicular segment or intracranial segments.

The most common sites of indirect TON are the intracanalicular segment (optic nerve sheath is adherent to the periosteum) and intracranial segment (in close proximity to the dural rings).<sup>4</sup>

Medical research council corticosteroid randomisation after significant head injury study has shown potentially harmful effects of steroids in craniofacial trauma patient. Thereby the use of steroids for TON has become more limited, since the majority of patients with TON have some form of concomitant intracranial injury.<sup>5</sup>

A Cochrane review by Yu-Wai-Man et al compared 31 eligible double-blinded placebo controlled, randomised trials of high-dose intravenous steroids in patients with indirect TON. The study concluded that there is a high rate of spontaneous visual recovery and that there is no convincing suggesting any added benefit of steroids over observation alone. Nevertheless, many practitioners still use steroids as conservative management of the TON, but the decision must be made on a case-by-case basis.<sup>6</sup>

Optic nerve decompression should be considered as a primary treatment modality when the pathology of injury is due to compression and amenable to surgical correction. Various approaches have been described for surgical optic nerve decompression for example,

transfacial approaches using a microscope, neurosurgical craniotomy approaches, and the transnasal endoscopic approach. visual loss can be restored if the endoscopic optic nerve decompression is performed before the start of irreversible optic neuropathy.<sup>7</sup>

TON decompression the surgical management of choice with minimal morbidity as compared to external approaches to optic nerve.<sup>8</sup>

## CONCLUSION

Endoscopic optic nerve decompression is a safe and effective treatment in selected cases of TON provided it is done before irreversible loss of vision occurs. In selected cases where the bony fragment is impinging on the optic nerve without causing transection of the nerve fibres, surgical decompression should be considered as early as possible to prevent optic neuropathy. Steroids have limited role and should be given patient to patient basis.

*Funding: No funding sources*

*Conflict of interest: None declared*

*Ethical approval: Not required*

## REFERENCES

1. Yu-Wai-Man P. Traumatic optic neuropathy-clinical features and management issues. Taiwan J Ophthalmol. 2015;5(1):3-8.
2. Wu N, Yin ZQ, Wang Y. Traumatic optic neuropathy therapy: an update of clinical and experimental studies. J Int Med Res. 2008;36(5):883-9.
3. Duke-Elder S, Wybar KC. System of ophthalmology, The anatomy of the visual system, vol. 2. London: Kimpton; 1961: 277.
4. Boštjan L, Ravnik J. Endoscopic Transnasal Optic Nerve Decompression. Open Access Atlas Of Otolaryngology, Head & Neck Operative Surgery. Available at: <https://vula.uct.ac.za/access/content/group/ba5fb1bd-be95-48e5-81be-586fbaeba29d/Endoscopic%20transnasal%20optic%20nerve%20decompression.pdf>. Accessed on 3 February 2020.
5. Wasserberg J. The MRC CRASH trial - a large, simple randomised trial of steroids in head injury. Acta Neurochir Suppl. 2004;89:109-12.
6. Yu-Wai-Man P, Griffiths PG. Steroids for traumatic optic neuropathy. Cochrane Database Syst Rev. 2013;6:CD006032.
7. Cook MW, Levin LA, Joseph MP, Pinczower EF. Traumatic optic neuropathy. A meta-analysis. Arch Otolaryngol Head Neck Surg. 1996;122:389-92.
8. Hathiram BT, Khattar V. Traumatic optic neuropathy. Otorhinolaryngol Clin. 2011;3(3):188-96.

**Cite this article as:** Munjal M, Kaur J, Rishi P, Tuli N, Bharadwaj I, Munjal S. Optic nerve decompression - role in preventing traumatic ischaemic optic neuropathy: case report. Int J Otorhinolaryngol Head Neck Surg 2020;6:1367-9.