

Original Research Article

Versatility of the submental island flap in head and reconstruction

Mahendra I. Katre^{1*}, Prashant Keche¹, Arvind Gaikwad², Sunil Deshmukh¹

¹Department of ENT and Head Neck Oncology, Government Cancer Hospital, Aurangabad, India

²Government Cancer Hospital, Aurangabad, India

Received: 24 June 2017

Accepted: 03 August 2017

*Correspondence:

Dr. Mahendra I. Katre,

E-mail: drmahendrakatre@gmail.com

Copyright: © the author(s), publisher and licensee Medip Academy. This is an open-access article distributed under the terms of the Creative Commons Attribution Non-Commercial License, which permits unrestricted non-commercial use, distribution, and reproduction in any medium, provided the original work is properly cited.

ABSTRACT

Background: Head neck cancer is major cause of morbidity and mortality worldwide. India has one of the highest incidences of oral cancer and accounts for about 30% of all new cases annually. Ablative surgery is main stay of treatment which is followed by reconstructive surgery. Microvascular surgery revolutionized onco-reconstruction which requires great expertise even in tertiary cancer centre and it is not possible many times due to long waiting list for it or patient condition. Here there is role locoregional pedicled flap which mitigate this problem to great extent to achieve acceptable functional and aesthetic outcome. One such flap worth to keep in surgeon armamentarium is submental island flap. Submental artery island flap (SIF) is an axial fasciocutaneous flap that includes skin, subcutaneous tissue, platysma, and fat and is pedicled on the submental artery and veins.

Methods: This study conducted in our institute a tertiary level cancer hospital. This is retrospective study. Data extracted from department database between periods February 2015 to May 2017. It includes 12 patients diagnosed with different sub site oral cancer, operated in department of head neck oncology for oral cancer and reconstruction following ablative surgery done by submental island flap by ablative surgeon.

Results: Submental island flaps are comparable in their outcome with radial forearm free flap. They carry a good color match with facial tissue. It is thin and has a reliable vascular morphology.

Conclusions: When combined with the reported experience of other surgeons, our preliminary experience shows that the SIF is an excellent alternative in the reconstruction of head and neck defects because of its reliability, versatility, and relative ease of application. Neck dissection can plan as an adjunctive procedure to the SIF with certain limitation.

Keywords: Head neck cancer, Reconstruction, Locoregional pedicled flap, Submental flap

INTRODUCTION

Oral cancer is eleventh most occurred cancer globally.¹ There is wide geographical variation in the incidence of oral cancer, with approximately two-thirds of patients in the developing countries of southeast Asia, Eastern Europe and Latin America.² In India oral malignancy account for 35% of total malignancy.³ Limited access to cancer care, relative lack of health care provider and financial resource are some of challenges to the management of oral cancer in India despite improvement

in diagnostic technique and management strategies. A high prevalence of tobacco consumption either in form of smoking or smokeless tobacco and related product made this problem worst in India responsible for oral cancer (various subsite), oropharynx, hypopharynx, larynx and sinonasal cancer. Surgical excision of tumor and neck dissection forms the mainstay of treatment which followed by adjuvant chemotherapy and radiotherapy. The resulting anatomical defect, functional loss, cosmetic disfigurement and accompanying psychosocial effect jeopardize quality of life to patients. Reconstructive

surgery plays crucial role in improving quality of life by restoring anatomical deficit achieving functional rehabilitation and aesthetic outcome.

Submental flap

The submental flap is submental artery island flap(SIF) is an axial fasciocutaneous flap that includes skin, subcutaneous tissue, platysma, and fat and is pedicled on the submental artery and veins Martin et al has described the qualities of ideal flap. They are thin, reliable and have a good color match.⁴ They should be easy to dissect, carry a long arc of rotation with minimum donor site morbidity.^{5,6} While Radial forearm free flap fulfils most of these qualities, submental flaps have also been found to have thin skin paddle and have a good color match.⁷ In female patient submental flap serves very good option for intraoral reconstruction being absence hair follicle whereas male patient with thick beard problem arise when there is excessive hair growth in reconstructed oral cavity. This problem decreases with radiation and as flap get accustomed to oral cavity environment as per our experience. The submental island flap had introduced by martin et al 1993.⁴ SIF can used for skin defect of lower 2/3 of face(excellent texture and color match), buccal, cheek, lateral floor of mouth and tongue resection. It can also use in case of oro and hypopharyngeal resection, esophageal augmentation in post-laryngectomy stenosis.

METHODS

This study includes operated patient in department of ENT and Head neck oncology in tertiary level cancer hospital between period from February 2015 to May 2017 for oral cancer.

Study participant

12 diagnosed cases of oral cancer with different sub site belonging to different age and sex group in whom SIF used for oral reconstruction following ablative surgery.

Study design

Retrospective analysis of data extracted from departmental database where SIF used as reconstruction option following ablative surgery.

Inclusion criteria

Considering SIF flap as reconstruction option, patients of different age group and sex with diagnosis of oral cancer with different sub site selected.

Exclusion criteria

Those patients having gross 1a and 1b nodal neck metastasis excluded from offering SIF as reconstruction option.

Surgical technique

After measuring the defect marking of the spindle-shaped flap with a marking pen in the submental region in a horizontal fashion. Place the anterior border of the skin paddle at least 1 cm behind the anterior rim mandible to hide the scar as much as possible. The length of the short axis of the skin paddle allows primary closure of the donor site defect, and this can easily be determined by pinching the skin of the submental area between two fingers before outlining the flap. We prefer starting the flap elevation from the opposite side of the pedicle in the subplatysmal plane and proceeding toward the midline (Figure 1). When the midline is reached, the dissection is carried out carefully to identify the submental artery and the vein at the medial border of medial border of anterior belly of digastric muscle on pedicle side.

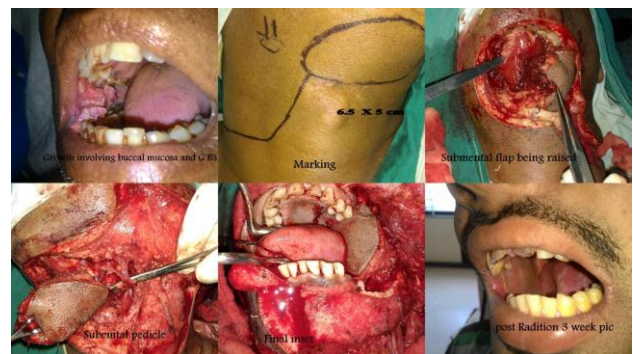


Figure 1: Submental island flap harvesting technique.

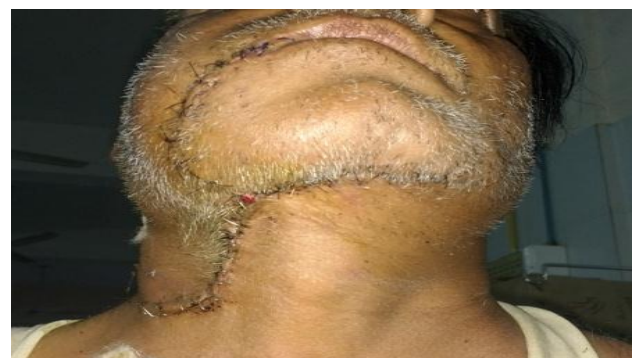

Figure 2: Primary closure of donor site.

Use of a Doppler probe can be helpful at this point. After identifying the submental vessels, the anterior belly of the digastric muscle is released from its attachments and elevated with the flap because the vascular pedicle passes deep to this muscle in most cases (Figure 1).⁸ Harvesting the flap is continued by carefully releasing the submental artery and the vein from the surrounding tissues during their course between the submandibular gland and the mandible. The surgeon should take special care not to separate the skin paddle from the submental vessels and not to injure the marginal mandibular nerve at this point. The dissection should be discontinued when sufficient length of vascular pedicle is obtained or the junction of the submental and facial vessels is reached. The flap is

then transferred and attached to the recipient site (Figure 1), and donor site closed primarily in layers (Figure 2). In Figure 3 submental Island flap used for retro molar area and tongue reconstruction submental island flap in contraindicated in gross level 1a and 1b nodal metastasis, low volume disease can be meticulously removed preserving pedicle.

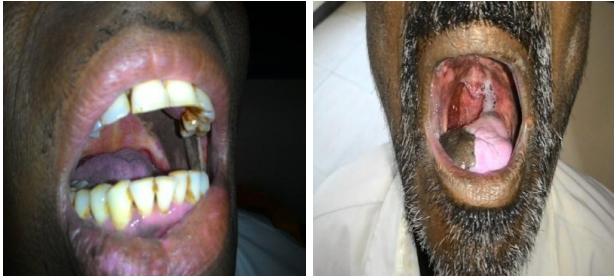

Figure 3: Submental island flap for retro molar area and tongue reconstruction.

Submental flap can harvested with other some modification like hybrid flap, reverse flow flap; submental island flap with bone (osteomyocutaneous SIF) can be used to reconstruct small composite defects of the mandible, maxilla and orbit. A small rim of bone from the inferior part of the mandible in the symphysis and parasymphysis area is sectioned and kept attached to the flap.

RESULTS

Table 1: Age wise distribution

Age	No of patients
<25 age	0
25-40	4
41-55	6
>56	1

Table 2: Sub sitewise distribution.

Sub site	No. of patients
Tongue	3
GBS+BM	9

All of our patients were proven malignant cases squamous cell carcinoma. Three out of twelve patients were tongue cancer and SIF used for reconstruction rest patient were having buccal mucosal growth. Mean age of participant in study was 44 years (Table 1) and male to female ratio was 9:3 (Figure 4). In our series all patient underwent neck dissection except in one patient where there was recurrent growth on buccal mucosa followed by maxillectomy and radiation. Salvage resection done with submental flap reconstruction and skin defect closed by V-Y fashion, flap got failed. We didn't use submental island flap where bulky nodes in level Ia or Ib. Nine out eleven patient had T3 growth, marginal mandibulectomy done in para-mandibular disease in buccal mucosal growth and gingivobuccal sulcus complex growth for clear negative margin. Average flap size 6.3x5 cms (Table 3).

All primary patients underwent adjuvant or concurrent radiotherapy. No flap failure occurs after radiotherapy with good mouth opening. All patients had Ryles tube feeding for 5-7 days and resume oral feeding on 7-8 post-operative day. As 3 patients were female hair growth inside oral cavity was not a problem but in male patient in initial postoperative day hair growth was observed. As flap get accustomed with oral environment and post radiation this problem diminished. In all male patients post-radiation 2 month follow up had no hair inside oral cavity. Submental flaps are comparable in their outcome with radial forearm free flap. They carry a good color match with facial tissue. It is thin and has a reliable vascular morphology.

Table 3: Patient information table.

S. no	Sex	Site of lesion	Stage	Size of flap (cms)	Procedure
1	Female	GBS+Bm	T3N0M0	6x5	wle+MM
2	Female	GBS+Bm	T4N1M0	7.5x6	wle+MM
3	Male	GBS+Bm	T3N2M0	6x5	wle
4	Male	GBS+Bm	T3N2M1	6x5	wle+MM
5	Male	Tongue	T3N0M0	5x4	wle
6	Male	Tongue	T3N0M0	6x5	hemiglossectomy
7	Male	GBS+Bm	T4N1M0	7x5	wle+MM
8	Male	GBS+Bm	T3N1M0	8x6	wle+MM+alvelectomy
9	Male	GBS+Bm	Post Rt	6x5	wle
10	Male	GBS+Bm	T3N1M0	7x6	wle+MM
11	Female	GBS+Bm	T3N0M0	6x5	wle+MM
12	Male	Tongue	T3N1M0	6x5	Ant subtotal glossectomy with tongue floor excision

wle: wide local excision, MM: Marginal mandibulectomy, GBS: Gingivobuccal sulcus, Bm: Buccal mucosa.

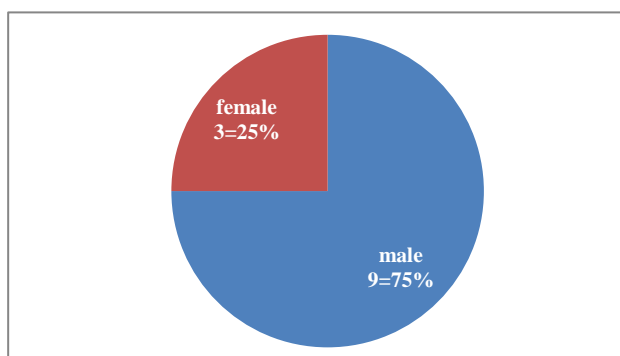


Figure 4: Sex wise distribution.

DISCUSSION

Head and neck area has many functional as well as aesthetic unit hence cancer of these area have impact on both so head and neck reconstruction is challenging job for reconstructive surgeon. Reconstruction option should be tailored preoperatively as well intra-operatively for each case. It depends on size of defect, requirement for type of tissue function appearance, associated physical condition patient and availability of resources. Martin et al has described the qualities of ideal flap. They are thin, reliable and have a good color match. They should be easy to dissect carry a long arc of rotation with minimum donor site morbidity in addition to it they should have consistent result, technically not very demanding and have short operative time in set up where microvascular reconstruction facility is not available or having long waiting list for it in tertiary cancer hospital. Life expectancy after cancer is good if it diagnosed early.

The SIF has several advantages. Its donor site defect can be closed primarily most of the time because of the laxity of the submental skin, especially in elderly patients. Its donor site scar is acceptable and not visible in most cases. The SIF has a long and reliable vascular pedicle, which provides a pedicle length up to 8 cm, with an average of 2-mm arterial diameter. If a longer pedicle is needed, it can be used as a reverse-flow flap by dividing the facial artery and vein proximal to the junction of the submental vessels. SIF can refashion into bipaddle flap. Ramkumar et al described a bi-paddled submental flap, where they used one paddle for providing the lining of the oral cavity and the other for covering the full thickness defect.⁹ A rich vascular network between the ipsilateral and contralateral facial arteries and veins allows the SIF to survive in such use, although there is reported flap failure because of the presence of venous valves in the facial vessels.¹⁰ Although the largest skin paddle used was 14×7 cms according to the English literature, it has been proposed that a skin paddle up to 18×7 cms is possible, depending on the laxity of the submental skin. Most of the cases reported in the literature, including all of our cases that underwent reconstruction with the SIF constitute patients with malignant neoplasm of the oral cavity and the lower third of the face. One of the debated

aspects of submental flap is its oncological safety. A cohort of 55 patients with squamous cell carcinoma of oral cavity in which submental flap was used for reconstruction was studied retrospectively by Howard et al.¹¹ No recurrence was found intra-orally at the site of reconstruction, even though 10% of the cases had occult metastasis found at level 1. Use of the SIF may be complicated if the neck dissection is planned in addition to the surgical resection of the primary site. Because first echelon lymphatic drainage of these anatomic regions is toward the submental (level Ia) and submandibular (level Ib) lymph nodes, isolation of the flap pedicle with a thick surrounding fibro fatty tissue may compromise the continuity of the neck dissection specimen if special attention is not paid. Therefore if reconstruction with the SIF is considered in such cases, neck dissection should be performed meticulously and the vascular pedicle should be thinned as much as possible to prevent incomplete removal of the lymph nodes. But excessive thinning can leads to insults to pedicle and cause flap failure. If the resection is performed for treating a benign disease or a low-grade malignancy such as basal cell carcinoma, where the neck dissection is not a concern, the vascular pedicle can be isolated with a thick surrounding tissue to prevent a possible flap failure as a result of kinking or compression of the relatively small diameter vessels. Controversy in the literature exists about harvesting the anterior belly of the digastric muscle with the SIF. Faltaous and Yetman proposed that the anterior belly of the digastric muscle should be included in the flap on the basis of their anatomic study, which showed the submental artery ran deep to this muscle in 70% of cadaveric dissections, whereas it ran superficial to the muscle in the remaining 30% dissections.¹² On the other hand, Yilmaz et al reported that the inclusion of the anterior belly of the digastric muscle was not necessary because they did not experience any flap loss despite exclusion of the muscle in most of their cases.¹³ They proposed that the muscle can be included in the flap if a bulky flap is desired. In our series we include anterior belly of digastric muscle in harvesting flap in all cases to prevent possible flap loss.

CONCLUSION

When combined with the reported experience of other surgeons, our preliminary experience shows that the SIF is an excellent alternative in the reconstruction of head and neck defects because of its reliability, versatility, and relative ease of application. Although donor site defects can be closed primarily in most cases, closure may be incomplete because of skin changes in patients with a history of previous radiation treatment, and the surgeon should be prepared to perform an alternative closure in such cases. Our experience shows that the SIF can be used in the reconstruction of tongue in case of partial or hemiglossectomy and reconstruction of defect of gingivobuccal complex lesion after ablative surgery very easily. However excessive hair growth of the flap in initial postoperative days but that problem tends to

decrease with time and post radiotherapy what we found in all our cases as all of our patients were oral cancer and received post op radiation. If a neck dissection is planned as an adjunctive procedure to the SIF, the neck dissection should be performed meticulously and the pedicle should be thinned as much as possible to prevent incomplete removal of the lymph nodes. However SIF should avoid in cases of gross level Ia and Ib levels nodal disease as it can compromise comprehensive neck dissection.

ACKNOWLEDGMENTS

Department of Radiation Oncology Government Cancer Hospital Aurangabad for their support.

Funding: No funding sources

Conflict of interest: None declared

Ethical approval: The study was approved by the Institutional Ethics Committee

REFERENCES

1. Ferlay J, Shin HR, Bray F, Forman D, Mathers C, Parkin DM. GLOBOCAN 2008 v2.0, Cancer incidence and mortality worldwide: IARC Cancer Base No. 10. Lyon, France: International Agency for Research on Cancer; 2010. Available at <http://globocan.iarc.fr>. Accessed on 1 March 2013.
2. Curado MP, Edwards B, Shin HR, Ferlay J, Heanue M, et al. (eds). Cancer incidence in five continents: Vol. 9, IARC Scientific Publication No. 160. Lyon, France: International Agency for Research on Cancer, 2009. Available at <http://www.iarc.fr/en/publications/pdfs-online/epi/sp160/CI5vol9.pdf>. Accessed on 1 March 2013.
3. Lason DL. Tumour of lip, oral cavity, oropharynx. In: Masthes SJ, ed. Plastic Surgery. 2nd edition Volume 1. Philadelphia: Saunders Elsevier; 2006: 159-187.
4. Martin D, Baudet J, Mondie JM, Peri G. A prosp du lambeau cutane sous-mental en ilot. Protocole operatoire perspectives D'utililisation Ann Chir Plat Esthet. 1990;35:480-4.
5. Brue E, Bey E, Cariou JL, Faciale L. Rappel embryologique, anatomie descriptive et fonctionnelle apres une revue de la litterature. Ann Chir Plast Esthet. 2000;45:461-84.
6. Hurwitz DJ, Rabson JA, Futrell JW. The anatomic basis for the platysma skin flap. Plast Reconstr Surg. 1983;72:302-14.
7. Merten SL, Jiang RP, Caminer D. The submental artery island flap for head and neck reconstruction. ANZ J Surg. 2002;72:121-4.
8. Magden O, Edizer M, Tayfur V, Atabey A. Anatomic study of the vasculature of the submental artery flap. Plast Reconstr Surg. 2004;114(7):1719-23
9. Ramkumar A, Francis NJ, Senthil Kumar R, Dinesh Kumar S. Bipaddled submental artery flap. Int J Oral Maxillofac Surg. 2012;41(4):458-60.
10. Sterne GD, Januszkiewicz JS, Hall PN, Bardsley AF. The submental island flap. Br J Plast Surg. 1996;49:85-9.
11. Howard BE, Nagel TH, Donald CB, Hinni ML, Hayden RE. Oncological safety of the submental flap for reconstruction in oral cavity malignancies. Otolaryngol Head Neck Surg. 2014;150(4):558-62.
12. Faltaous AA, Yetman RJ. The submental artery flap: an anatomic study. Plast Reconstr Surg. 1996;97:56-60.
13. Yilmaz M, Menders A, Barutcu A. Submental artery island flap for reconstruction of the lower and mid face. Ann Plast Surg. 1997;39:30-5.

Cite this article as: Katre MI, Keche P, Gaikwad A, Deshmukh S. Versatility of the submental island flap in head and reconstruction. Int J Otorhinolaryngol Head Neck Surg 2017;3:1072-6.