

Original Research Article

Comparison of anterior nasal packing and absence of packing after rhinoplasty

Vinnakota Sriprakash*

Department of ENT, Head and Neck, Mallareddy Medical College for Women, Hyderabad, Telangana, India

Received: 12 July 2017

Accepted: 31 July 2017

***Correspondence:**

Dr. Vinnakota Sriprakash,

E-mail: drsriprakash@gmail.com

Copyright: © the author(s), publisher and licensee Medip Academy. This is an open-access article distributed under the terms of the Creative Commons Attribution Non-Commercial License, which permits unrestricted non-commercial use, distribution, and reproduction in any medium, provided the original work is properly cited.

ABSTRACT

Background: Increased safety in the anesthesia and its techniques as well as the improved newer techniques, better outcome of this surgery have prompted many to undergo cosmetic surgeries such as rhinoplasty. The side effects observed are nasal obstruction, edema of the face, periorbital swelling and ecchymosis, which are of a great concern, and said to be aggravated with the anterior nasal packing.

Methods: 100 patients between 18-45 years of age, with nasal trauma were included in the study. Bilateral lateral osteotomies was performed in all patients, with anterior nasal packing done for control group and only external immobilization was done for the study group.

Results: No statistical difference was found between the two groups with regards to age and sex. However, there was a significant difference in severity and duration of periorbital ecchymosis in the different groups. On the 3rd day after the operation, more than one half of the unpacked study group (58.0%) showed ecchymosis of grade 1 or less compared with only 14.0% in the control group. On the 7th post-operative day however, both sides showed improvement to grade 1 or less in 98.0% and 40.0% of unpacked and packed sides, respectively.

Conclusions: Anterior nasal packing post rhinoplasty with lateral osteotomies plays a significant role in the resultant ecchymosis and it should be only used when necessary.

Keywords: Anterior nasal packing, Periorbital ecchymosis, Periorbital edema, Rhinoplasty, Osteotomies

INTRODUCTION

Cosmetic surgery of late, is steadily on the rise, with many people opting for it. The reason could be the increased safety in the anaesthesia and its techniques as well as the improved newer techniques and better outcome of this surgery. Rhinoplasty is one of the most common plastic surgical procedures both for functional as well as cosmetic purposes. According to the American Society of plastic surgery, rhinoplasty is the sixth most common procedure or plastic surgery.¹

However, as with many other surgical procedures, this one too has many complications.² Osteotomies are a form of trauma, in which there is disruption of many blood vessels in the facial region. Some of the others are nasal obstruction, edema of the face, periorbital swelling and ecchymosis, which are of a great concern even to the most experienced surgeon. This may even at times lead to vision blockade. This mainly results in a dissatisfied patient as it can cause social as well as work related inconvenience, the rate of which is estimated to be 10-25% especially in the early post op period.³⁻⁵

There have been a few studies to address this problem of edema of the eyelid and periorbital ecchymosis, by using anti-inflammatory drugs such as steroids, modified surgical techniques and cold compression techniques.^{6,7}

The most common mode of treatment of rhinoplasty is with the use of the nasal packing and external immobilization with splint as hemostasis may occur as well as this is required for the fixation of the operated bones and cartillages.⁸⁻¹⁰ Nasal packing is also useful in the prevention of mucosal adhesions. For this, many types of material are used especially paraffin gauze.¹¹⁻¹⁴

It was reported in a few surgeries that anterior nasal packing, when used unnecessarily following lateral osteotomies in rhinoplasty, contributed significantly to the postoperative eye lid edema and ecchymosis.¹⁵

The present study was conducted to assess if the anterior nasal packing has an effect on periorbital edema and ecchymosis following rhinoplasty with lateral osteotomy.

METHODS

This prospective study was conducted in Mallareddy Medical College for Women and Microcare ENT Hospital and research centre, Hyderabad, India during the period between June, 2014 and May, 2016, by the Department of Ear, Nose and Throat. 100 patients between 18-45 years of age, with nasal trauma were included in the study.

Patients who underwent other procedures like concomitant endoscopic sinus surgery and other facial surgeries were excluded from the study.

All the patients who were included into the study were divided into 2 groups of 50 each based on the random table- group I was study group and group II was control group. The nature of the study was explained to all the patients in detail and informed consent was obtained from all of them.

In all cases, bilateral lateral osteotomies were performed externally using a sharp 2 mm micro osteotome five to ten minutes after infiltrating the lateral osteotomy site with 0.5 ml of lignocaine 2% with adrenaline 1:100,000. Periosteal elevation was not performed prior to the lateral osteotomy in any of the cases. Anterior nasal packing was not done in the study group while it same was performed in the control group. Merocele sponge size 8 was used as the anterior nasal pack and was removed after 24 hours post-operatively. It was followed by nasal taping and dorsal splint application with POP.

All surgeries were performed under hypotensive sevoflurane general anesthesia which involved the use of fentanyl 2 mcg/kg, propofol 2 mg/kg IV and cisatracurium 0.15 mg/kg during induction. Patients were placed supine with head elevation to 15° during the

procedure. Mean arterial pressure (MAP) was maintained between 60 and 80 mmHg by the anesthetist. Immediately after the induction of anesthesia, 8 mg of dexamethasone was administered intravenously in all patients. Post-operatively all patients were kept in head end elevation of 30° for most of the first post-operative day. Cold saline soaked gauze compression was applied over the eyes intermittently for 24 hours following rhinoplasty.

Table: 1: Grades of periorbital ecchymosis and edema.

Grades	Extent of periorbital ecchymosis	Eyelid edema
0	No ecchymosis	No edema
1	Up to medial one-third of the lower and/or upper eyelid (to the medial canthus)	No coverage of iris with eyelids
2	Medial half of the upper and/or lower eyelid (to the pupil)	Slight coverage of iris with swollen eyelids
3	Past the pupil	Full coverage of iris with swollen eyelids
4	Up to the full length of the lower and/or upper eyelid (to the lateral canthus)	Full closure of eyes

Postoperative eye lid edema and periorbital ecchymosis was evaluated and graded by the operating surgeon and another surgeon who is unaware of the anterior nasal packing separately on 24 hours and third, fifth and seventh day post-operatively. The grades of eye lid edema and ecchymosis reported on 24 hours, 3rd, 5th and 7th day post-operatively. The grading was as per Table 1.

Chi square test for the difference in the grades and Mann-Whitney test for the difference in the packed and the unpacked cases were performed.

RESULTS

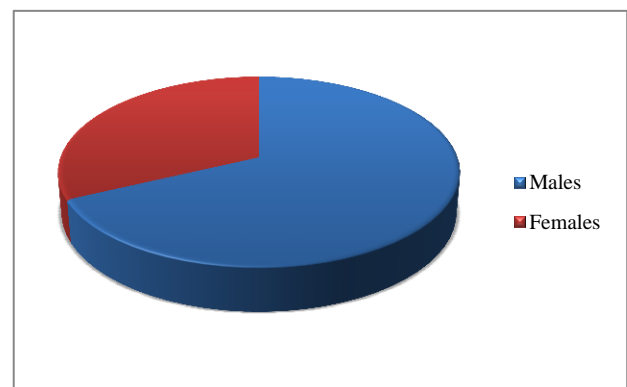


Figure 1: Gender wise distribution of the patients.

Out of the 100 patients included in the study, 68 (68%) were males and 32 (32%) were females.

No statistical difference was found between the two groups with regards to age and sex.

However, there was a significant difference in severity and duration of periorbital ecchymosis in the different groups. On day 1 there was no statistical difference in the different grades between the packed and unpacked cases ($p=0.744$). The statistical difference between the two groups was observed from day 3 onwards ($p<0.05$).

The different grades of periorbital ecchymosis in different groups are presented in Table 2.

On the 3rd day after the operation, more than one half of the unpacked study group (58.0%) showed ecchymosis of grade 1 or less compared with only 14.0% in the control group. On the 5th post-operative day, 80.0% of the study group showed improvement to grade 1 or less while it was 46.0% of the packed side control group. On the 7th postoperative day however, both sides showed improvement to grade 1 or less in 98.0% and 40.0% of unpacked and packed sides, respectively (Table 2).

Table 2: A comparison of different grades of periorbital ecchymosis seen at day 1, day 3, day 5 and day 7 post rhinoplasty.

Time postop	Side	Grade 0 (%)	Grade 1 (%)	Grade 2 (%)	Grade 3 (%)	Grade 4 (%)	Mean Score	Standard deviation	P value
Day 1	Packed	6 (12.0)	8 (16.0)	27 (54.0)	6 (12.0)	3 (6.0)	1.62	1.012	0.744
	Not packed	8 (16.0)	7 (14.0)	32 (64.0)	2 (4.0)	1 (2.0)	1.58	0.912	
Day 3	Packed	3 (6.0)	4 (8.0)	22 (44.0)	15 (30.0)	6 (12.0)	2.14	0.846	0.034
	Not packed	18 (36.0)	11 (22.0)	17 (34.0)	3 (6.0)	1 (2.0)	1.14	0.866	
Day 5	Packed	11 (22.0)	12 (24.0)	14 (28.0)	11 (22.0)	2 (4.0)	2.24	0.946	0.024
	Not packed	18 (36.0)	22 (44.0)	7 (14.0)	2 (4.0)	1 (2.0)	1.12	0.896	
Day 7	Packed	8 (16.0)	12 (24.0)	26 (52.0)	3 (6.0)	1 (2.0)	1.12	0.916	0.022
	Not packed	26 (52.0)	23 (46.0)	1 (2.0)	0	0	0.56	0.598	

DISCUSSION

Postoperative eye lid edema and periorbital ecchymosis can adversely influence the patient satisfaction after rhinoplasty as it may cause the discomfort and anxiety apart from socially disturbing and frightening to patients and may result in increased pigmentation.^{4,5} Although not visible immediately, it becomes apparent after a few hours of surgery.^{3,16} Complete resolution of this post-operative morbidity may take up to 2 to 3 weeks.

Though there are many factors responsible for periorbital ecchymosis, osteotomies performed as part of rhinoplasty is considered to be the main culprit in the postoperative ecchymosis. Especially, the lateral osteotomy, which causes injury to the angular vessels crossing the osteotomy site and leads to bleeding fractured bone edges. Blood then trickles into the eye lid and periorbital area and is collected under the thin, lax skin of eyelids instead of being drained into the nasal cavity.^{17,18} Factors that may contribute to eye lid edema and ecchymosis include vigorous rasping of nasal bones, high osteotomy placement and using excessively large or blunt osteotomes.¹⁸

Many surgical techniques had been introduced to lessen the postoperative edema and ecchymosis. Continuous compression with cold saline-soaked gauze during the operation and during the post-operative period for 24 hours is one such method proven to have significant impact on decreasing the edema.^{6,7} The use of sharp small osteotomes, preservation of the periosteal attachment, use

of a looped drainage tube, administration of perioperative steroids and remifentanyl with controlled sevoflurane hypotensive anaesthesia may further contribute to lessen periorbital edema and ecchymosis.¹⁷⁻²² Other methods which are ineffective although extensively used are infiltration with lignocaine-adrenaline combination.^{7,16,19}

Removal of the nasal packing is another area of concern as it is very painful and uncomfortable. Use of anesthesia during this period is generally suggested.²³⁻²⁵

The present study clearly shows that anterior nasal packing is significantly contributing to the postoperative periorbital ecchymosis. About 30% of the patients had grade III postoperative periorbital ecchymosis on day 3 which was reduced to 22% on day 5. In the same time period, only 6% in the study group had Grade III, which reduced to 4% in day 5. This was corroborated by other studies, where it was found that there were more cases of postoperative periorbital ecchymosis as well as periorbital edema after packing was done. In a study by Kara et al, subconjunctival ecchymosis was observed in around 20% of the patients who were packed bilaterally for 2 days. This ecchymosis was resolved in 11.2 days in their study.²⁶ In some cases, with a packed nose, the patients had more number of hospital days, with pain, headache, dysphagia and disturbed sleep. Poor hygiene leads to malodor of the tamponades.²⁷

It was suggested by Stucker and Ansel in 1978 for the disuse of tamponades for the rhinoplasty due to the many complications.²⁸ Similar to the present study, Guyuron et

al have observed lesser morbidity when no packing was done to the patients.²⁹ In yet another study by Camirand et al, septoplasty was suggested to avoid even the external immobilization of the nose.^{30,31}

CONCLUSION

In the present study it was observed that after rhinoplasty, there was less morbidity among the patients who did not have packing done and anterior nasal packing post rhinoplasty with lateral osteotomies plays a significant role in the resultant ecchymosis and it should be only used when necessary. This provides a reason to limit the use of anterior nasal packing post rhinoplasty unless they are absolutely necessary in cases where associated procedures like turbinectomy are done.

However, despite being unnecessary for most cases, nearly one third of rhinoplasty surgeons continue to regularly employ packing following rhinoplasty.

Funding: No funding sources

Conflict of interest: None declared

Ethical approval: The study was approved by the Institutional Ethics Committee

REFERENCES

- Rabie AN, Aalb ARMA, Askoura A, Hashem MH, Lin SJ. Effect of osteotomies during rhinoplasty on intraocular pressure. *Egyptian J Ear Nose Throat Allied Sci.* 2016;17:53–6.
- Holt G, ET G, McLarey D. Postoperative sequelae and complications of rhinoplasty. *Otolaryngol Clin North Am.* 1987;20(4):853–76.
- Biggs T, Fraser L, Ward M, Sunkaraneni V, Harries P, Salib R. Patient reported outcome measures in septorhinoplasty surgery. *Ann R Coll Surg Engl.* 2015;97(1):63–5.
- Balikci HH, Gurdal MM. Satisfaction outcomes in open functional Septorhinoplasty: prospective analysis. *J Craniofac Surg.* 2014;25(2):377–9.
- Günel C, Omurlu IK. The effect of rhinoplasty on psychosocial distress level and quality of life. *Eur Arch Otorhinolaryngol.* 2015;272(8):1931-5.
- Giacomarra V, Russolo M, Arnez ZM, Tirelli G. External osteotomy in rhinoplasty. *Laryngoscope.* 2001;111(3):433-8.
- Gun R, Yorgancılar E, Yıldırım M, Bakır S, Topcu I, Akkus Z. Effects of lidocaine and adrenaline combination on postoperative edema and ecchymosis in rhinoplasty. *Int J Oral Maxillofacial Surg.* 2011;40(7):722–9.
- Christophel JJ, Park SS. Complications in rhinoplasty. *Facial Plast Surg Clin North Am.* 2009;17(4):145-56.
- Holt GR, Garner ET, McLarey D. Postoperative sequelae and complications of rhinoplasty. *Otolaryngol Clin North Am.* 1987;20(4):853-76.
- Donald PJ. Postoperative care of the rhinoplasty patient. *Otolaryngol Clin North Am.* 1975;8(3):797-806.
- Cochran CS, Ducic Y, DeFatta RJ. Current concepts in the postoperative care of the rhinoplasty patient. *South Med J.* 2008;101(2):935-9.
- Kamer FM, Parkes ML. An absorbent, non-adherent nasal pack. *Laryngoscope.* 1975;85(2):384-8.
- Fernbach JC. Nasal packing after surgery. *JAMA.* 1982;248(19):2452.
- Bernal-Sprekelsen M. The postoperative nasal dressing. A new intranasal splint. *Rhinology.* 1990;28(3):197-203.
- Shadfar S, Deal AM, Jarchow AM, Yang H, Shockley WW. Practice patterns in the perioperative treatment of patients undergoing septorhinoplasty: a survey of facial plastic surgeons. *JAMA Facial Plast Surg.* 2014;16(2):113–9.
- Hettige R, Mansell N. Limiting oedema, ecchymosis and haemorrhage in septorhinoplasty with ice cooled swabs. *Ann R CollSurg Engl.* 2014;96(5):395–6.
- Tardy MA, Denny JC. Micro-osteotomies in rhinoplasty. *Facial Plast Surg.* 1984;1:137.
- Becker DG, McLaughlin RB, Jr Loevner LA, Mang A. The lateral osteotomy in rhinoplasty: clinical and radiographic rationale for osteotome selection. *Plast Reconstr Surg.* 2000;105(5):1806–16.
- Al-Arfaj A, Al-Qattan M, Al-Harethy S, Al-Zahrani K. Effect of periosteum elevation on periorbital ecchymosis in rhinoplasty. *J Plast Reconstr Aesthet Surg.* 2009;62(11):e538–9.
- Erişir F, Tahamiler R. Lateral osteotomies in rhinoplasty: a safer and less traumatic method. *Aesthet Surg J.* 2008;28(5):518–20.
- Cil Y. Loop drainage tube for reduction of edema and ecchymosis after rhinoplasty. *Aesthet Plast Surg.* 2008;32(6):937–8.
- Kelley BP, Koshy J, Hatef D, Hollier LH, Stal S. Packing and postoperative rhinoplasty management: a survey report. *Aesthet Surg J.* 2011;31(2):184–9.
- Lachanas VA, Karatzias GT, Pinakas VG. The use of tetracaine 0.25% solution in nasal packing removal. *Am J Rhinol.* 2006;20:483-4.
- Karaasian K, Yilmaz F, Gulcu N. The effect of prilocaine and prilocaine plus meperidine infiltration on the pain during nasal packing removal. *Rhinology.* 2007;45(5):321-4.
- Yilmazer C, Sener M, Yilmaz I. Pre-emptive analgesia for removal of nasal packing: A double-blind placebo controlled study. *Auris Nasus Larynx.* 2007;34(6):471-5.
- Kara CO, Kara IG, Yaylali V. Subconjunctival ecchymosis due to rhinoplasty. *Rhinology.* 2001;39(3):166–8.
- Lubianca-Neto JF, Sant'anna GD, Mauri M, Arrarte JL, Brinckmann CA. Evaluation of time of nasal packing after nasal surgery: a randomized trial. *Otolaryngol Head Neck Surg.* 2000;122(6):899-901.

28. Stucker FJ, Ansel DG. A case against nasal packing. *Laryngoscope*. 1978;88(8):1314-7.
29. Guyuron B. Is packing after septorhinoplasty necessary? A randomized study. *Plast Reconstr Surg*. 1989;84(1):41-4.
30. Camirand A, Doucet J, Harris J. Nose surgery (rhinoplasty) without external immobilization and without internal packing: a review of 812 cases. *Aesthetic Plast Surg*. 1998;22(4):245-52.
31. Camirand A. Nasal packing in rhinoplasty and septorhinoplasty: it is wiser to avoid. *Plast Reconstr Surg*. 1999;104(4):1198.

Cite this article as: Sriprakash V. Comparison of anterior nasal packing and absence of packing after rhinoplasty. *Int J Otorhinolaryngol Head Neck Surg* 2017;3:943-7.