International Journal of Otorhinolaryngology and Head and Neck Surgery
Jha S et al. Int J Otorhinolaryngol Head Neck Surg. 2026 Dec;12(6):1073-1074
https://www.ijorl.com
pISSN 2454-5929 | eISSN 2454-5937

Case Report

DOI: https://dx.doi.org/10.18203/issn.2454-5929.ijohns20264299

Human otoacariasis: a unique clinical report

Shruti Jha*, Abhishek Narayan Parbat, M. Mohan Raj

Department of ENT, All India Institute of Medical Sciences, Patna, India

Received: 19 October 2026
Revised: 17 November 2026
Accepted: 18 November 2026

***Correspondence:**
Dr. Shruti Jha,
E-mail: shrutijha123@gmail.com

Copyright: © the author(s), publisher and licensee Medip Academy. This is an open-access article distributed under the terms of the Creative Commons Attribution Non-Commercial License, which permits unrestricted non-commercial use, distribution, and reproduction in any medium, provided the original work is properly cited.

ABSTRACT

Otoacariasis is an uncommon tick and mite manifestation of the external auditory canal and can cause a plethora of ear infections and complications . We present the case of a 22-year old man who presented to us with the symptoms of unilateral incessant ear itching for one week .Oto endoscopy revealed the presence of mite like organism .The patient was treated with gentle suctioning and permethrin cream application with supportive medications and subsequently achieved full cure .

Keywords: Otoacariasis, Ticks, Mites, Ear canal

INTRODUCTION

Otoacariasis is an uncommon infestation of the ear canal by ticks and mites, affecting mainly the rural population. These ticks and mites are often vectors of disease and may affect poultry workers, domestic and wild animals.[1] The propensity of these infestation increases in tropics and subtropics, especially in a country like India where other factors like overcrowded living spaces, poor hygiene and scabies mite infestation are in abundance. Patients can present with itching, ear irritation edema of the ear canal and mild serous discharge after severe itching This can cause complications like otitis externa, otitis media and facial palsy.[2]

Clinical diagnosis is achieved by otoendoscopy and treatment usually involves the complete clearance of the tick or mite manifestation and relief of the symptoms. Multiple treatment options have been tried in the past like saline irrigation, ear toileting, glycerine application, ethanol irrigation and permethrin cream application.

This condition can be particularly perplexing for the patient as it can often be underdiagnosed. The complaints can be neglected; this often requires treatment of the physical contacts of the affected patient and requires awareness and outreach regarding the same.

CASE REPORT

We present the case of a 22-year-old male patient who had presented with complaints of left ear fullness and pruritus to our tertiary care centre. He was a medical student by occupation and had a history in living in an overcrowded dwelling arrangement but with no animal contact. He had no hearing loss.

Oto-endoscopy was done, bilateral tympanic membrane was found to be intact, on the left side there were several hundred mites and their eggs attached to the External Auditory Canal (EAC) wall and the tympanic membrane .Some of these mites were constantly in motion. Initially gentle suctioning and ear toileting was attempted but complete clearance of the mite wasn't achieved. Subsequently permethrin solution was then applied to the EAC and the tympanic membrane.

He was also given anti-histaminic, anti-inflammatory drugs and analgesics. Repeat endoscopy was performed after 3 and 7 days later revealing complete clearance of

the infestation. No aural or systemic symptoms were reported afterwards. Unfortunately, the mites were unable to find for microscopic examination. Informed consent was obtained from the patient. The video was reproduced with the written consent of the patient.

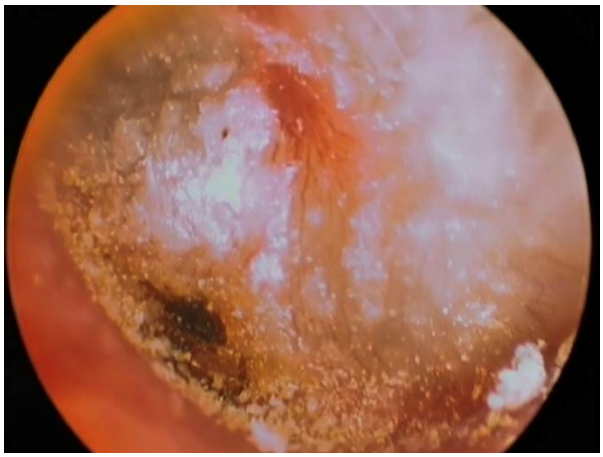

Figure 1 : The external auditory canal and tympanic membrane covered by mite like organism and its eggs.

DISCUSSION

Mite infestation especially due to storage and house dust mites found have been reported in multiple sources across medical literature. Ticks although are a far more frequent occurrence than mites. Mites belonging to subclass *Acari*, genus *Otodectus* cause otoacariasis commonly in dogs and cats.[3]

These often damage the epithelial barrier of the EAC and can lead to edema, excoriation, serous discharge and otitis externa.[4,5] Once examined by endoscopes or microscopes, these should be sent to the microbiology department for identification. Mite removal by irrigation by saline, ethanol, glycerin or gentle suction can be attempted.[6] Turpentine oil although use has severe ototoxic side effects and should best be avoided.

This case highlights the importance of considering parasitic infestations as a differential of pruritus. Wherever possible, identification and complete removal of the mites should be achieved and is the core of effective treatment. This case highlights the need for awareness about parasitic infestations of the ear canal and establishes it as an important differential of pruritus in the ear.

CONCLUSION

The extremely unusual presentation of otoacariasis was successfully treated with topical permethrin cream application and was also given anti-histaminics with adequate analgesia. Follow up revealed complete resolution of the disease and clinical symptoms. It is imperative for the condition to be identified and treated along with any family or friends of the patients to stop the further propagation of the disease. This clinical report will be helpful in identifying other cases of otoacariasis, especially in developing countries which can often be mistaken as a simple insect infestation. This is also unique since the patient resided in an urban area quelling perception that otoacariasis tend to occur mostly in rural belts.

Funding: No funding sources
Conflict of interest: None declared
Ethical approval: Not required

REFERENCES

1. Krishnan A, Salaria N, Saheewala S, Kataria U. Otoacariasis: a parasitic infestation of rarity among humans. Indian J Otol. 2025;31(1):57-9.
2. Cakabay T, Gokdogan O, Kocyigit M. Human otoacariasis: demographic and clinical outcomes in patients with ear-canal ticks and a review of literature. J Otol. 2016;11(3):111-7.
3. Kasaragod SK, Kshithi K, Parvathareddy N, Sriperumbudur S, Shenoy SV. Unusual presentation of otoacariasis: a prospective study at referral teaching hospital. Indian J Otolaryngol Head Neck Surg. 2022;74(Suppl 3):4345-9.
4. Bhandari R, Aryal B, Bajracharya R, Kandel D, Darnal C, Gurung LB. Otoacariasis: clinical characteristics and outcome: a study in central part of Nepal. J Coll Med Sci Nepal. 2025;21(2):109-13.
5. Ramasamy K, MS V, Karunakaran V, Shankar V, Surendran AK. Ear mites as an overlooked source of ear itching and tinnitus - a case series. Indian J Otolaryngol Head Neck Surg. 2024;76(1):1279-83.
6. Abi-Akl P, Haddad G, Zaytoun G. Otoacariasis: an infestation of mites in the ear. Ann Clin Case Rep. 2017;2:1329.

Cite this article as: Jha S, Parbat AN, Raj MM. Human otoacariasis: a unique clinical report. Int J Otorhinolaryngol Head Neck Surg 2026;12:1073-4.