International Journal of Otorhinolaryngology and Head and Neck Surgery
Mathews S et al. Int J Otorhinolaryngol Head Neck Surg. 2026 Dec;12(6):1066-1069
https://www.ijorl.com
pISSN 2454-5929 | eISSN 2454-5937

DOI: https://dx.doi.org/10.18203/issn.2454-5929.ijohns20264297

Case Report

Adenoid cystic carcinoma of the external auditory canal: a case report

Sunil Mathews[1]*, Praveen Vijayan[1], Seerat Pal[2], Asha Treesa Jose[3]

[1]Department of ENT, Command Hospital (Air Force), Bangalore, Karnataka, India
[2]Department of Pathology, Command Hospital (Air Force), Bangalore, Karnataka, India
[3]Department of Dermatology, Venereology, and Leprosy, MVJ Medical College and Research Hospital, Hoskote, Bangalore, Karnataka, India

Received: 06 October 2026
Revised: 12 November 2026
Accepted: 16 November 2026

***Correspondence:**
Dr. Sunil Mathews,
E-mail: drsunilmathews@gmail.com

Copyright: © the author(s), publisher and licensee Medip Academy. This is an open-access article distributed under the terms of the Creative Commons Attribution Non-Commercial License, which permits unrestricted non-commercial use, distribution, and reproduction in any medium, provided the original work is properly cited.

ABSTRACT

Adenoid cystic carcinoma (ACC) of the external auditory canal (EAC) is a rare malignant tumour account for less than 3-10%, characterized by slow growth, perineural invasion, and a high propensity for local recurrence. ACC is found more often in the smaller salivary glands; however, it may also appear in lacrimal glands, tracheobronchial tree, breast, oesophagus, EAC, oral cavity, palate, nasal cavity and nasopharynx. The treatment goal includes complete surgical excision due to the high risk of repeat local recurrence. Distant metastasis is not uncommon to occur over the course of many years, mainly to the lungs. We report a case of an 80-year-old male who presented with a progressively enlarging mass with normal skin over it in the left EAC, causing him hearing loss and aural fullness. The patient underwent excision biopsy of this benign-looking mass obstructing the left EAC, and histopathological examination revealed cribriform variant of ACC. This case brings out the importance of having a high index of suspicion even in a benign looking mass in EAC, histopathological confirmation, and appropriate surgical management of this rare clinical entity.

Keywords: Adenoid cystic carcinoma, External auditory canal, Conductive hearing loss, Excision biopsy

INTRODUCTION

Adenoid cystic carcinoma (ACC) of the external auditory canal (EAC) is a rare tumour with an aggressive clinical behaviour.[1] Its occurrence in the EAC is rare. ACC is known for indolent growth, perineural spread, and late recurrences, necessitating long-term follow-up. Due to its rarity and slow growth, diagnosis is often delayed.[1,2]

The clinical manifestations of ACC in the EAC commonly include otalgia, hearing loss, otorrhoea and aural fullness. It can also present with intermittent ear pain in the early stage and can be progressed to persistent severe pain in the late stage and spread to the periauricular area.[3] Tumour penetration into the EAC can cause mass effect in the EAC and consequently results in conductive hearing loss. The course of the disease is longer and can be accompanied by secondary infection and otorrhea, where it is easily misdiagnosed as otitis externa or malignant otitis externa, and the diagnosis may be delayed.[4] We report a rare case of ACC, which was presented as a smooth benign looking mass in the left EAC causing conductive hearing loss in an elderly male.

CASE REPORT

An 80-year-old male, known case of hypertension, presented with complaints of left aural fullness and hearing loss of six months duration. His complaints were insidious in onset, persistent and gradually progressive. There was no complaint of otorrhoea, otalgia, facial weakness, tinnitus, fever, headache, nasal obstruction, neck swellings or other ENT complaints.

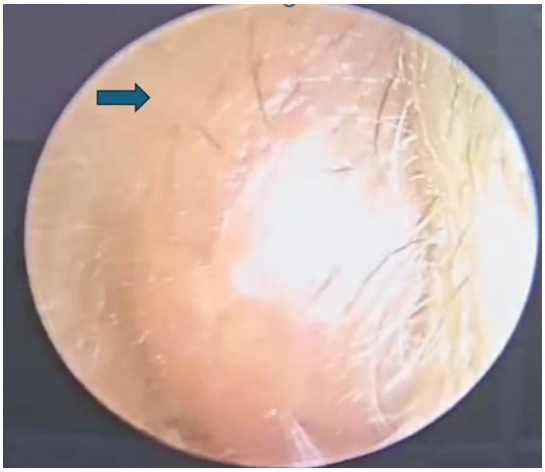

Figure 1: Benign-looking mass attached to antero-superior wall of left EAC.

Clinical examination

Otoscopic examination revealed oval shaped, firm benign-looking mass in the left EAC, which was arising from antero-superior part of cartilaginous EAC. The skin over the mass was normal with no change in colour, erosions, irregularities or with any dilated vessels. The mass lesion was obstructing the visualisation of left tympanic membrane (Figure 1). Tuning fork tests showed Rinne's test negative for 256 Hz and 512 Hz, and positive for 1024 Hz on left side. Weber's test was lateralized to left. Absolute bone conduction was not reduced bilaterally. Facial nerve examination was normal. Examination of the nose, oral cavity and oropharynx were unremarkable. There were no lymph nodes palpable on the neck and there was no parotid swelling.

High resolution computed tomography (HRCT) of the temporal bone has shown soft tissue lesion in left cartilagenous EAC, with no evidence of bony erosion. Air was seen in the medial EAC between tympanic membrane and the mass (Figure 2). Under local anaesthesia, an excision biopsy of the EAC mass was performed. The mass lesion was excised in toto with a rim of normal skin approximately 0.5 cm around it. Histopathological examination revealed the biopsy specimen lined with stratified squamous epithelium with sub-epithelium showing stroma with tumour arranged in predominantly cribriform pattern of nests and chords of cells around pseudocystic spaces filled with granular basophilic material. Intra-tumoral perineural invasion was seen. There were no features of extra-tumoral perineural invasion (Figure 3). IHC was positive for p63, CD117 and CK7, while CK20 was negative. The reports were consistent with ACC. Margins were negative for tumour involvement. The case was subsequently discussed in a multidisciplinary tumour board meeting for further management.

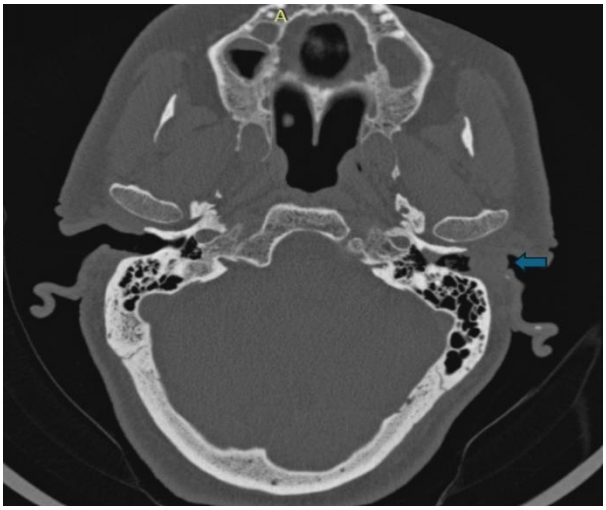

Figure 2: HRCT temporal bone (blue arrow is showing the soft tissue lesion in left cartilaginous EAC).

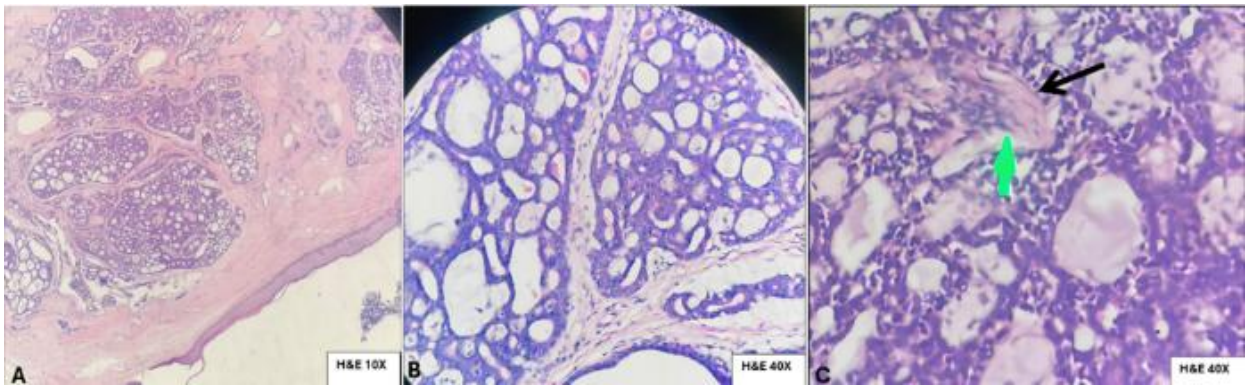

Figure 3: (A) H&E 10 X: Tumour cells in cribriform pattern in the dermis; (B) H&E 40X: Biphasic tumour in cribriform pattern composed of epithelial and myoepithelial cells and (C) adenoid cystic carcinoma showing intratumoral perineural invasion (black and green arrows).

In this case, the tumour board of the institute considered the age of the patient, clinical stage of T1N0M0 (according to Pittsburgh staging criteria), no features of extra-tumoural spread of the disease, negative margins of the biopsy specimen, morbidity at this age due to adjuvant radiotherapy, and the local availability of patient

for regular follow up. It was decided in the tumour board to go for scar revision with one centimeter margin all around the scar, and if the revision specimen biopsy proves negative for malignancy, to keep the patient under regular follow up. It was also decided in the tumour board to go in for en-bloc resection of the lateral EAC along with the adjoining parotid gland, followed by adjuvant radiotherapy, if the revision excision specimen proved to be positive for any tumour. Based on tumour board recommendations, the patient underwent revision of scar at the antero-superior wall of left EAC under local anesthesia. Excision of scar tissue with 1 cm margin all around was done and sent for histopathological examination. Histopathological examination revealed, the scar tissue negative for malignancy.

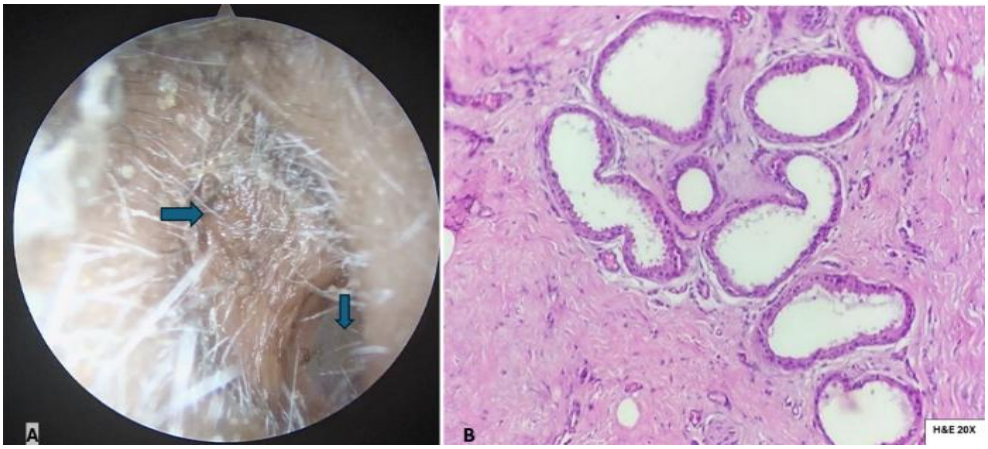

Figure 4: (A) The scar at antero-superior wall of left EAC (horizontal blue arrow) with normal tympanic membrane (vertical blue arrow) and (B) scar revision histopathology showing no evidence of malignancy.

Post-operative period was uneventful. The patient remained stable with no fresh complaints. Long-term follow-up was advised due to the known risk of local recurrence associated with ACC. In the first year of follow up, the patient was reviewed every month for any loco-regional recurrence. At one year of follow up, the patient had no evidence of loco-regional recurrence and no evidence of any distant metastasis as noted on Positron Emission Tomography-Computed Tomography (PET-CT) scan (Figure 5). Presently he is kept under three-monthly regular follow up. He is planned for six-monthly follow up in third year and yearly follow up thereafter.

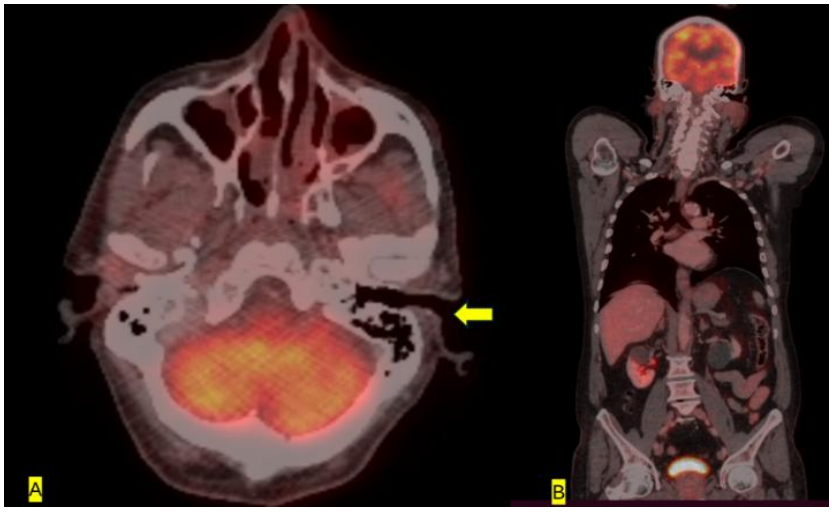

Figure 5: (A) PET-CT showing no evidence of loco-regional recurrence in left EAC (yellow arrow) and (B) PET-CT showing no evidence of distant metastasis.

DISCUSSION

EAC tumours are rare, and among them, only 20% are of glandular origin and remaining majority are squamous cell carcinomas. ACC is the most prevalent one among the glandular tumours. Silent growth, local recurrence and late distant metastasis are characteristic features of ACC of EAC.[1] The origin of ACC in EAC still remains controversial, however, it is suggested to be arising from eccrine sweat glands, ceruminous glands or ectopic salivary glands.[3] The usual clinical course of ACC in EAC is indolent and it leads to a late diagnosis. It is rare

and usually presents with symptoms such as ear canal mass or hearing loss. Pain and facial nerve involvement may occur due to perineural invasion.[5] A high index of suspicion is required for early diagnosis. The tumour may occur at any age, but peak incidence is in the 5th and 6th decades. Patients require high resolution CT scan of temporal bones to see the extend of bony erosion.[4] Differential diagnosis of EAC mass includes papilloma, adenoma, tuberculosis, squamous cell carcinoma, basal cell carcinoma, mucoepidermoid carcinoma and adenocarcinoma. Histopathological confirmation and appropriate surgical management are crucial.

Diagnosis is done by tissue biopsy and histopathological examination. There is a role for fine needle aspiration cytology in the pre operative diagnosis in some cases.[1] For ACC of EAC, surgical excision with adequate clear margins remains the mainstay of treatment, in view of high risk of local recurrence. Depending on the stage of disease, the extend of surgical excision differs. Wide local resection, en-bloc EAC resection and lateral temporal bone resection are done for patients with early-stage disease. Sub-total, extended sub-total or total temporal bone resection are the surgical options for patients with advanced disease. Superficial or total parotidectomy is required in case of involvement of parotid gland or there is advanced invasion of anterior wall of EAC.

Mandibular condylar excision is required in case of involvement of the condyle. A neck dissection is necessary if neck nodes are involved.[3,5] There are three histological patterns for ACC of EAC: tubular, cribriform and solid, among which tubular pattern has the best prognosis, cribriform pattern is the most prevalent and solid pattern is associated with the worst prognosis.[2,6] The present case had cribriform pattern on histopathology. Given the tumour's tendency for recurrence, long-term surveillance is essential. The possibility of distant metastasis of ACC to organs such as kidneys, lungs, brain and bones especially to vertebrae should be kept in mind and hence the patient should be under long-term follow up.[3]

Poor prognosis is encountered when there is local relapses, when there is bone, parotid or perineural involvement, and in cases of positive margins and the tumour is of the solid histopathological type.[1] Most post-operative recurrences have been reported within two years, but this interval may extend to upto15 years.[2] In case of doubtful negative margins, postoperative radiotherapy (RT) and chemotherapy may be considered to reduce the rate of recurrence and to improve long-term survival.[3] However, ACC is not very sensitive to RT and chemotherapy and the effect of them on ACC is controversial. For patients with early T-stage tumours with negative surgical margins, as in this present case, adjuvant RT is not necessary.[2,4] Literature reveals treatment of advanced ACC with lung metastasis using molecular targeted drugs such as levnatinib and anlotinib.[5] Perineural invasion (PNI) is strikingly common even in early tumours. The high rate of PNI, coupled with perineural tumour spread and a propensity for hematogenous dissemination, make distant metastasis the most common pattern of treatment failure in ACC, often occurring in the absence of locoregional recurrence.[7]

CONCLUSION

This case highlights the importance of early diagnosis and vigilant follow-up to rule out loco-regional, nodal and distant metastasis, especially to lungs, in managing this rare EAC malignancy.

ACKNOWLEDGEMENTS

The authors acknowledge the Department of pathology for the accurate diagnosis of this rare clinical entity.

Funding: No funding sources
Conflict of interest: None declared
Ethical approval: Not required

REFERENCES

1. Carvalho CP, Barcellos AN, Teixeira DC, de Oliveira Sales J, da Silva Neto R. Adenoid cystic carcinoma of the external auditory canal. Braz J Otorhinolaryngol. 2008;74(5):794-796.
2. Liu SC, Kang BH, Nieh S, Chang JL, Wang CH. Adenoid cystic carcinoma of the external auditory canal. J Chin Med Assoc. 2012;75(6):296-300.
3. Jiang X, Jia L, Zhang X, Zhong C, Tang F, Chen X, et al. Clinical experience of 23 cases of adenoid cystic carcinoma of the external auditory canal. Oncol Lett. 2020;20(5):144.
4. Wang Y, Xu L, Guan B, Tian T, Chang L. The study on prognosis in patients with adenoid cystic carcinoma of the external auditory canal. J Int Adv Otol. 2023;19(2):149-154.
5. Yang X, Liu R, Yin C, Zhang F, Li S, Liu Y, et al. Adenoid cystic carcinoma of the external auditory canal with pulmonary metastasis: a case report and literature review. Acta Oto-Laryngol Case Rep. 2024;9(1):102-8.
6. Nayak SP, Walke VA, Helwatkar SB, Bobhate SK. Adenoid cystic carcinoma of the external auditory canal: report of two cases. Indian J Pathol Microbiol. 2009;52(4):540-542.
7. Lee RH, Wai KC, Chan JW, Ha PK, Kang H. Approaches to the management of metastatic adenoid cystic carcinoma. Cancers (Basel). 2022;14(22):5698.

Cite this article as: Mathews S, Vijayan P, Pal S, Jose AT. Adenoid cystic carcinoma of the external auditory canal: a case report. Int J Otorhinolaryngol Head Neck Surg 2026;12:1066-9.