International Journal of Otorhinolaryngology and Head and Neck Surgery
Sahoo S et al. Int J Otorhinolaryngol Head Neck Surg. 2026 Dec;12(6):1062-1065
https://www.ijorl.com
pISSN 2454-5929 | eISSN 2454-5937
DOI: https://dx.doi.org/10.18203/issn.2454-5929.ijohns20264296

Case Report

External jugular vein venous malformation: an unusual presentation of a cervical vascular anomaly

Satyanjaya Sahoo[1], Avinav Sarmaik[2], Sneha[1]*, Nishant Panda[1], Sangram Keshari Das[1]

[1]Department of ENT, Kalinga Institute of Medical Sciences and Pradyumna Bal Memorial Hospital, Bhubaneswar, Odisha, India
[2]Department of ENT, Dr. Yashwant Singh Parmar Government Medical College Hospital, Nahan, Himachal Pradesh, India

Received: 05 October 2026
Accepted: 03 November 2026

***Correspondence:**
Dr. Sneha,
E-mail: sneha.rims11@gmail.com

Copyright: © the author(s), publisher and licensee Medip Academy. This is an open-access article distributed under the terms of the Creative Commons Attribution Non-Commercial License, which permits unrestricted non-commercial use, distribution, and reproduction in any medium, provided the original work is properly cited.

ABSTRACT

External jugular vein (EJV) venous malformations are rare vascular anomalies that may present as an intermittent neck swelling and pose a diagnostic challenge. We report a 46-year-old woman, presented with a left-sided neck swelling from 6-8 months, appearing on straining. The swelling became prominent on Valsalva manoeuvre and was initially suspected to be a laryngocele. Computed tomography revealed a lobulated vascular mass adjacent to the sternocleidomastoid muscle, while Doppler ultrasonography demonstrated a low-flow vascular malformation. Surgical exploration revealed a vascular lesion arising from the EJV. The lesion was excised following ligation of its tributary and the parent vein was preserved. HPE confirmed venous malformation. The postoperative course was uneventful, and no recurrence was observed during more than one year of follow-up. EJV venous malformation should be considered in the differential diagnosis of a neck swelling that becomes apparent with Valsalva manoeuvre. Appropriate imaging is essential before aspiration or biopsy, and surgical excision can provide satisfactory outcomes in selected cases.

Keywords: EJV, Venous malformation, Vein malformation, Neck swelling

INTRODUCTION

Venous malformations (VMs) can present as neck mass in adult and children. These are extremely rare in EJV with less than 10 cases described till date.[1,2] Most of the time patient is anxious regarding the swelling and due to its varied presentation it becomes a diagnosis of exclusion. Once diagnosis is confirmed patient is counselled for modalities of treatment. If asymptomatic it may be left like that.

Active intervention is considered in case of symptoms like pain, breathing difficulty, compression complaints, and progressive size or for cosmetic purposes. The options of sclerotherapy and surgical excision are available. We present a case where surgical excision was performed.

CASE REPORT

A 46 years old female with no known co-morbidities, presented to outpatient department with left sided neck swelling from 6-8 months. The swelling was insidious in onset and the patient started noticing the same during activities that involved forcefully blowing air through mouth/ nose or exerting pressure and disappeared in normal relaxed state. There was no history of pain, trauma to neck, difficulty breathing, difficulty swallowing, change in voice, fever or pressure symptoms or other ENT related complaints. The patient was asked to perform Valsalva manoeuvre which made a single swelling appear over left side of neck-about 3×3 cm in size, globular, without overlying skin changes or fluctuation and settled as soon as the pressure was released (Figure 1). The swelling was non tender, without

local rise in temperature, soft, compressible, reducible and partially transilluminant.



Figure 1 (A and B): A-Normal neck in resting position. B-Swelling evident on Valsalva manoeuvre.

Based on the history and examination a diagnosis of Laryngocele was made at the initial outset. A computed tomography scan of neck was requested which revealed a lobulated vascular mass over left side adjacent to the left sternocleidomastoid. (Figure 2). These findings challenged the diagnosis of laryngocele and pointed towards vascular anamoly. Doppler Ultrasonography examination of the neck while asking patient to perform Valsalva manoeuvre showed low flow vascular malformation.



Figure 2: Vascular swelling over left side arising from EJV (white arrow).

Patient was counselled and informed regarding options of sclerotherapy and surgery. After obtaining consent for surgery, routine investigations were performed for pre-anaesthestic evaluation. A transverse cervicofascial incision was made and blunt dissection utilised to delineate the vascular swelling from surrounding tissues. The swelling was found arising from EJV and resting superficial to left Sternocleidomastoid muscle with transverse cervical nerve traversing its superior portion (Figure 3). The mass tributary from vein was ligated and cut to deliver out specimen which was sent for Histopathological examination. The wound was closed in layers with corrugated drain in situ which was removed next day.



Figure 3: (A) Vascular malformation arising from left EJV, (B) vein preserved with mass excised.

Post operative hospital stay was uneventful. The patient was discharged and later followed up after a week for suture removal. Biopsy result was consistent with venous malformation. The patient has had a recurrence free period of over a year till date and is doing well.

DISCUSSION

The vascular anomalies are classified according to International Society for the Study of Vascular Anomalies (ISSVA) as following.[3]

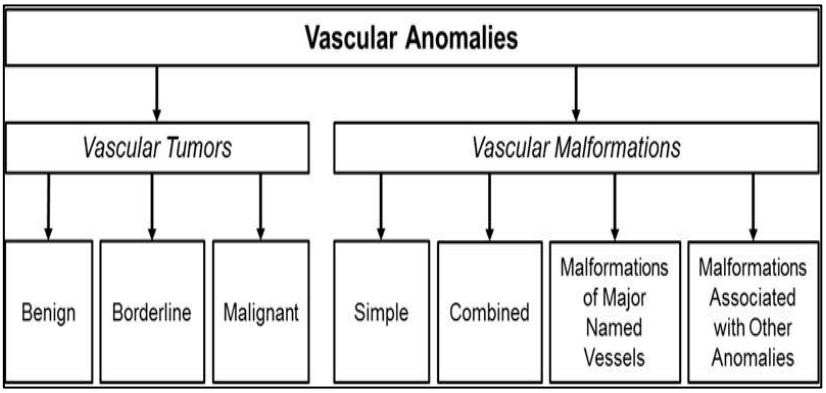

Figure 4: Vascular anomalies.

This classification is inspired from Mulliken and Glowacki who took into consideration the endothelial characteristics.[4]

Vascular malformations are the non-proliferative group of disorders of vascular anomalies. With no gender preponderance they can be identified at birth in up to 90 percent cases. These malformations grow insidiously and histopathology suggests mature non proliferating endothelium. It can be arterial, venous, lymphatic, capillary or mixed. Maximum prevalence is of venous malformation. This histological analysis has helped in diagnosis and management of these VMs.[5,6]

Vascular malformations are considered to have occurred due to errors in vascular genesis. Malformations are known to grow slowly, contrast to tumours. Genetic discoveries have shown post zygotic genetic variants result in activation of growth pathways.[3]

Conventionally vascular malformations can be divided based on flow type (not part of ISSVA classification)-high flow (arterial predominant) or low flow (rest like venous, capillaryetc. non arterial).[3,7]

VMs can occur anywhere in the body commonly involving skin, bones, joint spaces or viscera, however, most commonly seen in head and neck. They may present as neck mass in adults. Hence, before aspirating and before taking biopsy imaging must be done.[8] For the naked eye it may look like a bruise on the skin, and can have bluish colour if near the skin. However, it's not mandatory as its appearance varies according to the depth of the lesion also the skin colour of the patient. In our case we mistook it initially as laryngocele which was deferred by radiologic investigation.

Less than 10 cases of head and neck region VMs arising from the EJV have been reported in literature.[1,2] An incidence of one to two/ 10,000 births, prevalence of 1%, are present at birth and grow equitably with age having varied presentations.

If asymptomatic, patient may be observed however if patient is symptomatic or wants cosmetic result various modalities are explained. Sclerotherapy is one of the popular treatments in last decade for venous malformation in head and neck region. It is the sclerosant concentration and the dwell time that is the most important variable in sclerotherapy. Its known complications are skin necrosis, skin darkening, incomplete or residual lesion, peripheral nerve palsies, as well as fatalities such as cardiac arrest and pulmonary emboli.[1,2] Also they can be surgically explored, dissected and excised. Most of the literature reports good results and for cosmetic appeal it is also a preferred modality.

CONCLUSION

Venous malformation of head and neck region is being managed by otolaryngologists, vascular surgeons and plastic surgeons. During evaluation of any mass in neck region vascular anomalies should be kept in mind, aspiration and biopsy to be avoided before imaging. Surgical exploration provides a good result with minimal to no comorbidities.

Funding: No funding sources
Conflict of interest: None declared
Ethical approval: Not required

REFERENCES

1. Legiehn GM, Manraj KS. Venous malformations: classification, development, diagnosis, and interventional radiologic management. Radiol Clin North Am. 2008;46:545-97.
2. Sanjana VN, Chetana SN, Priyajeet P, Haris Q. External jugular vein vascular malformation: a case report. Online J Otolaryngol. 2015;5(4):126.
3. Steiner JE, Drolet BA. Classification of vascular anomalies: an update. Semin Intervent Radiol. 2017;34:225-32.
4. Mulliken JB, Glowacki J. Hemangiomas and vascular malformations in infants and children: a classification based on endothelial characteristics. Plast Reconstr Surg. 1982;69:412-22.

5. Meyers MA. Hemangioma of the external jugular vein. Radiology. 1967;89:483-5.
6. Sarteschi LM, Bonanomi G, Mosca F, Ferrari M. External jugular vein hemangioma occurring as a lateral neck mass. J Ultrasound Med. 1999;18(10):719-21.
7. Jackson IT, Carreño R, Potparic Z, Hussain K. Hemangiomas, vascular malformations, and lymphovenous malformations: classification and methods of treatment. Plast Reconstr Surg. 1993;91(7):1216-23.
8. Bartholomew JR, Smolock CJ, Kirksey L, Singh C, Chatterjee D, Gorsi U. Jugular venous aneurysm. Ann Vasc Surg. 2020;68(5):567.e5-e9.

Cite this article as: Sahoo S, Sarmaik A, Sneha, Panda N, Das SK. External jugular vein venous malformation: an unusual presentation of a cervical vascular anomaly. Int J Otorhinolaryngol Head Neck Surg 2026;12:1062-5.