International Journal of Otorhinolaryngology and Head and Neck Surgery
Reddy NK et al. Int J Otorhinolaryngol Head Neck Surg. 2026 Dec;12(6):975-978
https://www.ijorl.com
pISSN 2454-5929 | eISSN 2454-5937

DOI: https://dx.doi.org/10.18203/issn.2454-5929.ijohns20264280

Original Research Article

Congenital anomalies in otorhinolaryngology: a tertiary care approach

Nandini Kanupuru Reddy, Birudavolu Vikyath Reddy, Prateek Prasoon*

Department of ENT, VIMS & RC, Bangalore, India

Received: 26 September 2026
Revised: 02 November 2026
Accepted: 05 November 2026

***Correspondence:**
Dr. Prateek Prasoon,
E-mail: prasoon.prateek1@gmail.com

Copyright: © the author(s), publisher and licensee Medip Academy. This is an open-access article distributed under the terms of the Creative Commons Attribution Non-Commercial License, which permits unrestricted non-commercial use, distribution, and reproduction in any medium, provided the original work is properly cited.

ABSTRACT

Background: Congenital anomalies involving the ear, nose, throat and head-and-neck region may present as isolated structural defects or as part of multisystem disorders. Early recognition and appropriate management are important to reduce functional impairment and associated morbidity.
Methods: This retrospective observational study included 64 patients with congenital otorhinolaryngological anomalies who presented to the outpatient department of a tertiary-care hospital between January 2023 and January 2025. All eligible cases during the study period were included using a consecutive sampling approach. Patients underwent detailed history-taking, clinical examination and relevant investigations. Data were analysed using Microsoft Excel and categorical variables were summarised as frequencies and percentages.
Results: Males accounted for 71.8% of the study population and females for 28.2%. Forty-six patients presented in the second decade of life and 18 in the first decade. Ankyloglossia was the most frequently recorded anomaly (17; 26.6%), followed by thyroglossal duct cyst (14; 21.9%), branchial cleft anomalies (10; 15.6%) and preauricular sinus (10; 15.6%). Congenital sensorineural hearing loss was identified in one patient (1.6%).
Conclusions: Congenital otorhinolaryngological anomalies encompass a varied clinical spectrum. A systematic examination, appropriate investigations and timely management are important, together with assessment for associated abnormalities and counselling of parents or caregivers.

Keywords: Branchial apparatus, Congenital anomalies, Childhood, Head and neck, Otorhinolaryngology

INTRODUCTION

Congenital anomalies are structural or functional abnormalities that arise during intrauterine development and may be identified antenatally, at birth or later in infancy and childhood. They may affect a single organ system or occur as part of a multisystem disorder. Congenital anomalies involving the ear, nose, throat and head-and-neck region are clinically important because they may cause functional impairment, cosmetic concerns and, in some cases, significant morbidity. The clinical spectrum of these conditions encountered in otorhinolaryngological practice has been described in earlier hospital-based studies.[1,2] The development of the head and neck involves a complex sequence of embryological events. The pharyngeal (branchial) apparatus contributes to the formation of several structures of the face, neck and pharynx. Disturbances in the development or involution of the pharyngeal arches, clefts and pouches may result in congenital lesions such as branchial cleft cysts, sinuses and fistulae. These anomalies may present as a neck mass, a cutaneous opening or recurrent local infection.[3] Congenital neck masses comprise a range of developmental lesions, including thyroglossal duct cysts, branchial cleft anomalies, dermoid cysts and vascular malformations. Their presentation depends on the site, size and presence of secondary infection. Careful clinical assessment and appropriate imaging are important for diagnosis and treatment planning.[4] Ankyloglossia, commonly known as tongue-tie, is a congenital oral anomaly characterised by a short or restrictive lingual frenulum that may limit tongue mobility. Its reported prevalence varies according to the population studied and the diagnostic criteria

applied. In selected infants, it may be associated with breastfeeding difficulties; in older children, restricted tongue movement may be relevant to articulation or oral function.[5]

Other congenital anomalies encountered in otorhinolaryngological practice include preauricular sinus and congenital hearing impairment. A preauricular sinus may remain asymptomatic or present with recurrent infection and discharge. Congenital hearing impairment may adversely affect speech, language development, communication and educational attainment if it is not identified and managed early. The assessment of a child with a congenital head-and-neck anomaly should therefore include a comprehensive examination and further evaluation for associated abnormalities when clinically indicated.

Management depends on the type and severity of the anomaly and may include observation, medical treatment, surgical correction, hearing rehabilitation or multidisciplinary care. A better understanding of the clinical pattern of these anomalies in a tertiary-care setting may help describe the burden encountered in routine otorhinolaryngological practice and inform diagnostic and management pathways.

Aim and objectives

The objective of this study was to examine the occurrence and clinical manifestations of congenital anomalies encountered in childhood during otorhinolaryngological practice. The study also aimed to assess associated systemic involvement and describe the available treatment options, including surgical and conservative management.

METHODS

This was a hospital-based retrospective observational study conducted in the Department of Otorhinolaryngology at a tertiary-care hospital over a period of two years, from January 2023 to January 2025. The study was conducted after approval by the Institutional Ethics Committee. A total of 64 patients with congenital otorhinolaryngological anomalies who presented to the outpatient department during the study period and fulfilled the eligibility criteria were included. All eligible cases identified during the study period were included using a consecutive sampling approach.

Inclusion criteria

Patients of either sex, aged 0–50 years, who presented with congenital otorhinolaryngological anomalies were included.

Exclusion criteria

Patients with cleft lip and palate were excluded.

Data were obtained from the available clinical records. Patients had undergone detailed history-taking and comprehensive otorhinolaryngological examination. Relevant investigations, including radiological, audiological and histopathological assessments, were performed wherever indicated. Following clinical evaluation and investigations, patients were managed either surgically or conservatively, depending on the nature of the anomaly and the clinical indication.

Data were entered and analysed using Microsoft Excel. Descriptive statistical methods were used and categorical variables were expressed as frequencies and percentages.

RESULTS

A total of 64 patients with congenital otorhinolaryngological anomalies were included. Males constituted 71.8% of the study population, while females constituted 28.2%. Forty-six patients presented in the second decade of life and 18 in the first decade.

The frequency distribution of the anomalies recorded in the study population is presented in Table 1.

Congenital deafness

Congenital inner-ear-related abnormality presenting as congenital sensorineural hearing loss was identified in one patient (1.6%). The patient had a normal otorhinolaryngological examination; however, otoacoustic emission testing and brainstem evoked response audiometry revealed profound hearing loss associated with delayed speech development. Cochlear implantation was performed.

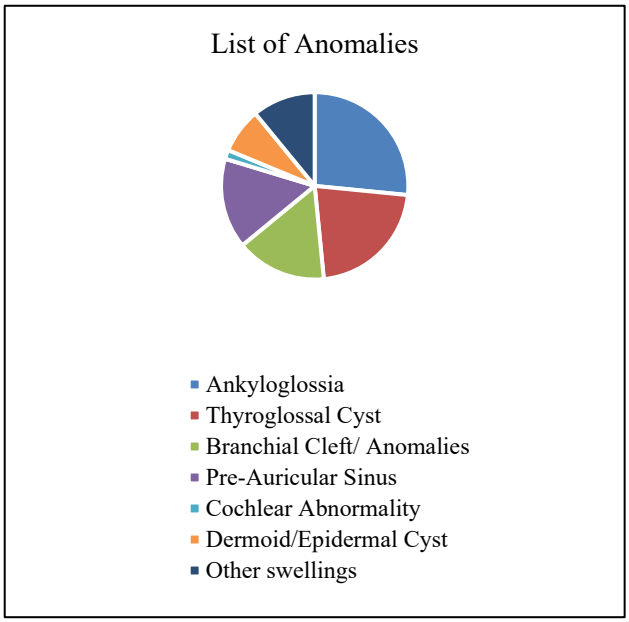

Figure 1: Distribution of congenital otorhinolaryngological anomalies among the study population.

Ankyloglossia (tongue-tie)

Seventeen patients (26.6%) with ankyloglossia were recorded; all were male. Four cases were classified as Grade 1, two as Grade 2 and 11 as Grade 3. Following evaluation, release of the tongue-tie was performed in each case, with repair using Vicryl sutures. In one patient, ankyloglossia was present along with a left vocal cord polyp. Direct laryngoscopy and biopsy were performed during the same setting and histopathological examination was suggestive of squamous papilloma.

Cystic swellings of the neck

In this study, 14 cases of thyroglossal duct cyst, 10 cases of branchial cleft cyst and two cases of lymphoepithelial cyst were recorded. Together, these 26 cases accounted for 40.6% of the study population. All 14 patients with thyroglossal duct cyst underwent Sistrunk surgery. The 10 patients with branchial cleft cyst underwent complete excision followed by histopathological examination. Correlation of clinical diagnosis with ultrasonography and histopathological findings is shown in Table 2.

Preauricular sinus

Ten patients (15.6%) presented with preauricular sinus. All underwent surgical management in the department and the postoperative recovery was uneventful.

Other clinical presentations

Seven miscellaneous clinical presentations were described: four cases of reactive lymphadenitis, one case suggestive of ranula and two neck swellings that were identified as arising from the submandibular gland following excision and biopsy.

Table 1: Frequency distribution of congenital otorhinolaryngological anomalies.

Anomaly	N (%)
Ankyloglossia	17 (26.6)
Thyroglossal cyst	14 (21.9)
Branchial cleft anomalies	10 (15.6)
Preauricular sinus	10 (15.6)
Cochlear abnormality	1 (1.6)
Dermoid/epidermal cyst	5 (7.8)
Other swellings	7 (10.9)
Total	64 (100)

Table 2: Correlation of clinical diagnosis with ultrasonography and histopathology.

Clinical diagnosis	Total cases	USG correlated with clinical diagnosis	Histopathology consistent with clinical diagnosis
Thyroglossal cyst	14	14	14
Branchial cleft cyst	10	10	10
Other cystic swellings (lymphoepithelial cysts)	2	0	0

DISCUSSION

Congenital anomalies involving the ear, nose, throat and head-and-neck region represent a varied group of conditions encountered in otorhinolaryngological practice. In the present study, males constituted 71.8% of the study population and females 28.2%. Forty-six patients presented in the second decade of life, while 18 presented in the first decade. The clinical spectrum observed in our study is comparable in broad terms with previously published hospital-based descriptions of congenital otorhinolaryngological anomalies.[2,12] Cystic swellings of the neck accounted for 40.6% of the cases in our study. The 26 cases comprised 14 thyroglossal duct cysts, 10 branchial cleft cysts and two lymphoepithelial cysts. Congenital neck masses include developmental lesions such as thyroglossal duct cysts, branchial cleft anomalies and dermoid cysts, as well as vascular and lymphatic malformations. The location of a lesion and its relationship to adjacent structures can provide useful diagnostic clues. Ultrasonography is commonly used as an initial imaging modality for evaluating a palpable neck mass.[4,6,7] All 14 patients with thyroglossal duct cyst in our study underwent Sistrunk surgery, while all 10 patients with branchial cleft cyst underwent complete excision. Accurate identification of the anatomical extent of a congenital neck lesion is important for planning definitive management. Clinical assessment, imaging and histopathological examination contribute to diagnosis and confirmation.[4,6,7] Ankyloglossia was recorded in 17 patients (26.6%) in our study and all were male. Ankyloglossia is characterised by a restrictive lingual frenulum that may limit tongue movement. Reported prevalence varies with the diagnostic definition and assessment method. Messner et al, reported a male-to-female ratio of 2.6:1 in a newborn cohort.[5] The present study also showed a male predominance, although the study populations and age distributions differ.

Management options described in clinical practice include observation, speech or feeding support when indicated and frenotomy or frenectomy in selected symptomatic patients. Preauricular sinus accounted for 10 cases (15.6%) in our study. Preauricular sinus is a congenital malformation that may remain asymptomatic or present with recurrent infection. Previous reports have described the clinical outcomes of patients undergoing surgery for preauricular sinus, while congenital ear anomalies have also been discussed in the context of embryological development and reconstructive management.[8-11] Congenital sensorineural hearing loss was identified in one patient (1.6%) in our study. Early identification of hearing impairment is important because hearing contributes to speech and language acquisition, communication and social development. The World Health Organization's World Report on Hearing highlights the importance of early identification, access to hearing care and rehabilitation, including hearing aids and cochlear implants when indicated.[12,13]

The findings of this study underline the range of congenital conditions that may present to an otorhinolaryngology service. A systematic clinical examination, appropriate use of investigations and timely intervention are important. Assessment for associated abnormalities and counselling of parents or caregivers should form part of comprehensive care.

Limitations

The present study has certain limitations. It was conducted at a single tertiary-care centre and included a relatively small sample of 64 patients, which may limit the generalizability of the findings. As a retrospective study, it was dependent on the completeness and accuracy of the available clinical records. The distribution of anomalies may also have been influenced by referral patterns and patient attendance at the tertiary-care hospital. Larger multi-centre studies involving broader populations would provide a more comprehensive understanding of the epidemiological profile and clinical spectrum of congenital otorhinolaryngological anomalies.

CONCLUSION

Congenital anomalies are an important component of paediatric otorhinolaryngological practice and may lead to long-term functional impairment if not recognised and managed appropriately. The present study demonstrates a varied clinical spectrum, with ankyloglossia and congenital cystic swellings of the neck among the commonly recorded presentations. A comprehensive otorhinolaryngological examination, appropriate investigations and timely medical or surgical management are essential. Evaluation for associated abnormalities and clear communication with parents or caregivers, including counselling and guidance regarding follow-up, are important to optimize patient care.

Funding: No funding sources
Conflict of interest: None declared
Ethical approval: The study was approved by the Institutional Ethics Committee

REFERENCES

1. Marsh JL, Vannier MW, editors. Comprehensive care of craniofacial deformities. St Louis: Mosby. 1985: 335–789.
2. Sinha V, Johri S, George A. Congenital anomalies in E.N.T. Indian J Otolaryngol Head Neck Surg. 2001;53(4):326–7.
3. Adams A, Mankad K, Offiah C, Childs L. Branchial cleft anomalies: a pictorial review of embryological development and spectrum of imaging findings. Insights Imaging. 2016;7(1):69–76.
4. Ryu J, Igawa T, Mohole J, Coward M. Congenital neck masses. NeoReviews. 2023;24(10):642–9.
5. Messner AH, Lalakea ML, Aby J, Macmahon J, Bair E. Ankyloglossia: incidence and associated feeding difficulties. Arch Otolaryngol Head Neck Surg. 2000;126(1):36–9.
6. Connolly AA, MacKenzie K. Paediatric neck masses—a diagnostic dilemma. J Laryngol Otol. 1997;111(6):541–5.
7. Puthen VP, Buruju J. Thyroglossal cysts in a pediatric population: apparent differences from adult thyroglossal cysts. Ann Saudi Med. 2013;33(1):45–8.
8. Tang IP, Shashinder S, Kuljit S, Gopala KG. Outcome of patients presenting with preauricular sinus in a tertiary centre—a five year experience. Med J Malaysia. 2007;62(1):53–5.
9. Thorn L. Entwicklung des Ohres (einschließlich Entstehung von Missbildungen, experimentelle Embryologie und In-vitro-Studien). In: Helms J, editor. Oto-Rhino-Laryngologie in Klinik und Praxis. Vol 1. Stuttgart: Thieme. 1994: 1122.
10. Brent B. The pediatrician's role in caring for patients with congenital microtia and atresia. Pediatr Ann. 1999;28:374–83.
11. Conway H, Wagner K. Congenital anomalies of the head and neck. Plast Reconstr Surg. 1965;36:711–9.
12. Goswami A, Sharma K, Biswas AK. Congenital anomalies in childhood encountered during clinical practice by an otorhinolaryngologist. Int J Otorhinolaryngol Head Neck Surg. 2020;6(7):1282.
13. World Health Organization. World report on hearing. Geneva: World Health Organization. 2021.

Cite this article as: Kanupuru Reddy NK, Reddy BV, Prasoon P. Congenital anomalies in otorhinolaryngology: a tertiary care approach. Int J Otorhinolaryngol Head Neck Surg 2026;12:975-8.