International Journal of Otorhinolaryngology and Head and Neck Surgery
Behera SK et al. Int J Otorhinolaryngol Head Neck Surg. 2026 Dec;12(6):1060-1061
https://www.ijorl.com
pISSN 2454-5929 | eISSN 2454-5937

DOI: https://dx.doi.org/10.18203/issn.2454-5929.ijohns20264295

Case Report

Traumatic injury to neck and internal jugular vein: management at a district head hospital

Sanjaya K. Behera[1]*, Anita M. Jena[1], Ananya Aparoopa[2], Bikramjit Sahu[3], Saroj K. Behera[4]

[1]Department of ENT and HNS, DHH Keonjhar, Odisha, India
[2]Department of Dentistry, DDMCH, Keonjhar, Odisha, India
[3]Department of Radiology, Aster DM Health care, Doha, Quatar
[4]Department of Public Health Dentistry, SCB Dental College and Hospital, Cuttack, Odisha, India

Received: 24 September 2026
Revised: 04 November 2026
Accepted: 12 November 2026

***Correspondence:**
Dr. Sanjaya K. Behera,
E-mail: sanjayakumarbehera824@gmail.com

Copyright: © the author(s), publisher and licensee Medip Academy. This is an open-access article distributed under the terms of the Creative Commons Attribution Non-Commercial License, which permits unrestricted non-commercial use, distribution, and reproduction in any medium, provided the original work is properly cited.

ABSTRACT

The internal jugular vein is one of the major vessels of the neck. The vein is deeply situated, an injury to the vein nearly always associated with additional injuries to other important structures such as injury to the sternocleidomastoid muscle, carotid artery, the vagus nerve, oesophagus, trachea, larynx. The (internal jugular vein) IJV injury leads to profuse hemorrhage and is very difficult to control. The ideal way of controlling the bleeding is by neck compression at the site of injury, a quick exploration of the neck for the course of injury and securing both the end of injury. Air embolism or embolism due to clot may occur due course of management of IJV injury. Hence early assessment and management of the injury are critical to save the life of an affected individual. We present a case of a homicidal cut throat injury with profuse bleeding who was referred to us in a tight neck bandage. The patient was shifted immediately to operation theatre (OT) with close monitoring of all vitals and securing the airway and circulation. A severed sternocleidomastoid muscle was seen with injury to the internal jugular vein after exploration. The cut lateral end of IJV sutured with proline (3,0). The neck wound sutured in layers and a drain was placed. Then the patient was shifted to the intensive care unit (ICU) from where the patient was shifted to ward in post op day 5 and discharged uneventfully after drain removal. We did in our small setup with no proper vascular surgery backup and referring the patient was not a preferable option.

Keywords: Penetrating neck injury, Internal jugular vein injury, Neck exploration, Sternocleidomastoid muscle, IJV

INTRODUCTION

Penetrating neck injuries represent approximately 5-10% of all trauma cases that present to the emergency department and result in significant mortality.[1-3] Injury to internal jugular vein is accompanied by common carotid artery anteromedially and vagus nerve posteriorly in carotid sheath in neck. It lies just lateral and anterior to the internal carotid artery. Injuries to the jugular veins can be caused by penetrating trauma, blunt trauma or iatrogenic causes following a medical intervention. Internal jugular vein (IJV) injury always associated with additional injuries to other important structures of neck such as injury to the sternocleidomastoid muscle, carotid artery, the vagus nerve, oesophagus, trachea, larynx. The IJV injury leads to profuse hemorrhage and is very difficult to control. We want to report a case of homicidal cut throat referred to our cauality outpatient department (OPD) from a primary health care institution. We managed the case in operation theatre (OT) by suturing the IJV cut ends under general anesthesia.

CASE REPORT

A 45 years male was referred to our casuality OPD from a primary health care with a tight neck bandaged and soaked with blood with a history of a homicidal cut wound of neck. On general examination the patient was conscious

and well oriented to time, place and person. He had tachycardia with hypotension. The patient was rushed to OT with immediate intervention to maintain the circulation and breathing securing airway. Under general anaesthesia the neck wound was opened. On opening there was gush of blood coming from the neck. By compressing the lower end of neck, the blood flow was reduced. There was a lacerated injury of the anterolateral aspect of the right side of mid of neck of size 7 cm length 3 cm breadth and 3 cm deep. The sternocleidomastoid muscle was severed and the internal jugular vein was seen cut open at its medial margin of wound approximately 1 cm length along IJV. The cut lateral end sutured carefully with available proline (3,0). The cut sternocleidomastoid muscle was sutured with vicryl (3,0) (Figure 1) and skin was sutured in layers with mersilk (3,0). The drain was secured and the dressing done. Following the repair the patient was a bit disoriented post recovery for which he was shifted to ICU where close monitoring of drain and vitals done. The patient was shifted to the ward on post op day 5. The drain was removed and he was discharged on postoperative day 7 uneventfully.

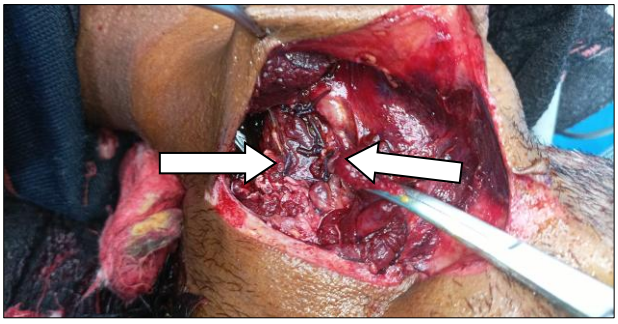

Figure 1: The cut ends of the sternocleidomastoid muscle were held in artery forceps, the IJV medial cut end was sutured with proline (3,0) (arrow heads).

DISCUSSION

Injury to the IJV can result from different aetiologies. It can be due to high velocity penetrating trauma of neck like homicidal stab wound or gunshot wound, can be due to blunt trauma of neck as in a motor vehicle accident, can be due to iatrogenic cause like central line placement or in a neck dissection.[1,4] The injury is always associated with severe blood loss leading to hypotension, tachycardia, venous congestion leading to facial edema. The diagnosis requires proper physical examination, haematocrit and sometimes in case of blunt trauma and gunshot injuries to know the extent of damage and access collaterals computed tomography (CT) angiography and ultrasound of neck is required.[1,4-6] The outcome of Internal jugular vein injuries depend on severity of injury, and quick management. Managing the airway, breathing and circulation is paramount importance in a case of a penetrating neck injury.[2,3,7]

In our case because of hypovolemic shock we plan to do explore the neck immediately after anesthesia with blood transfusion without going for CT angiography.[7] We sutured the cut ends of the IJV followed by suturing of the muscle and skin. We did in our small setup with no proper vascular surgery backup and referring the patient was not a preferable option.

CONCLUSION

A laceration of the internal jugular vein is an acute emergency and should be managed promptly without delay. To manage the blood loss, it is mandatory to send the patient with proper pressure dressing from a primary set up to a higher center. The management is surgical exploration with suturing of the cut ends with available proper sutures with maintenance of airway, breathing and circulation.

Funding: No funding sources
Conflict of interest: None declared
Ethical approval: Not required

REFERENCES

1. Babar SMA. Internal Jugular Vein Injuries. Neck Injuries. 2000;67-70.
2. Gupta B, Gulati A, Gupta D. A rare presentation of pellet injury in the neck. ISRN Surg. 2011;2011:306126.
3. Luntz M, Nusem S, Kronenberg J. Management of penetrating wounds of the neck. Eur Arch Otorhinolaryngol. 1993;250(7):369-74.
4. Dogar MR, Khanani SF, Farooq S, Saleem S. Penetrating Injury to the Internal Jugular Vein -Case Report. Medical Reorts 2023;2:100024.
5. Sperry JL, Moore EE, Coimbra R, Croce M, Davis JW, Karmy-Jones R, et al. Western Trauma Association critical decisions in trauma: penetrating neck trauma. J Trauma Acute Care Surg. 2013;75(6):936-40.
6. Burgess CA, Dale OT, Almeyda R, Corbridge RJ. An evidence based review of the assessment and management of penetrating neck trauma. Clin Otolaryngol. 2012;37(1):44-52.
7. Coleman KC, Hudnall A, Grabo DJ, Pillai L, Borgstrom DC, Wilson A, et al. Penetrating trauma to the neck: Using your vascular toolkit. J Trauma Acute Care Surg. 2021;91(2):e51-4.

Cite this article as: Behera SK, Jena AM, Aparoopa A, Sahu B, Behera SK. Traumatic injury to neck and internal jugular vein: management at a district head hospital. Int J Otorhinolaryngol Head Neck Surg 2026;12:1060-1.