International Journal of Otorhinolaryngology and Head and Neck Surgery
Shetty SS et al. Int J Otorhinolaryngol Head Neck Surg. 2026 Dec;12(6):1057-1059
https://www.ijorl.com
pISSN 2454-5929 | eISSN 2454-5937
DOI: https://dx.doi.org/10.18203/issn.2454-5929.ijohns20264294

Case Report

Papillary thyroid carcinoma arising from the pyramidal lobe with occult intratracheal extension: a rare case report

Shravan S. Shetty[1]*, Sachender Pal Singh[2], Saiyyad Altapali Gulabnabi[1], Deepak Parikh[1]

[1]ACI Cumballa Hill Hospital, Mumbai, Maharashtra, India
[2]Ranchi Cancer Hospital and Research Centre, Ranchi, Jharkhand, India

Received: 24 September 2026
Accepted: 02 November 2026

***Correspondence:**
Dr. Shravan S. Shetty,
E-mail: drshravanshetty@gmail.com

Copyright: © the author(s), publisher and licensee Medip Academy. This is an open-access article distributed under the terms of the Creative Commons Attribution Non-Commercial License, which permits unrestricted non-commercial use, distribution, and reproduction in any medium, provided the original work is properly cited.

ABSTRACT

Papillary thyroid carcinoma (PTC) originating in the pyramidal lobe is rare, often linked to aggressive features like extrathyroidal extension. A 62-year-old gentleman presented with a recent onset of breathlessness and a large asymptomatic midline neck mass. Additional staging workup and final histopathology report showed a locally invasive, tall cell variant of papillary carcinoma arising from the pyramidal lobe of the thyroid gland with regional and systemic metastases. Total thyroidectomy with central compartment and bilateral neck dissection, along with microlaryngoscopic (ML) scopy excision of intratracheal mass, was performed, followed by radioiodine therapy. Progression to anaplastic carcinoma occurred at 18 months. Pyramidal lobe PTC warrants inclusion in differentials for midline neck masses due to its prognostic implications. This case highlights the potential for significant intratracheal extension despite the absence of radiological evidence, emphasizing the importance of endoscopic evaluation in suspected aggressive thyroid malignancies.

Keywords: Pyramidal lobe, Tall cell variant, Extrathyroidal extension, Papillary thyroid carcinoma, Intratracheal invasion

INTRODUCTION

The thyroid gland consists of two lobes and an isthmus. The pyramidal lobe is a variable anatomical structure arising from the distal part of the thyroglossal duct and has many anatomical variants.[1] It most commonly arises from the isthmus of the left lobe and seldom from the right and ends at the hyoid bone. Pyramidal lobe malignancies are extremely uncommon, with only five case series reported in the literature.[2-6] PTC is the most common thyroid malignancy. Although most PTCs are well differentiated, a small group of tumours showing heterogeneity and aggressive behaviour has been identified. These include tall cell variant, diffuse sclerosing variant, columnar cell variant, solid variant and hobnail variant. The tall cell variant of PTC (TCVPTC) was first reported by Hawk and Hazard in 1976.[7] TCVPTC is the most common aggressive variant of PTC, accounting for 4-19% of all PTCs.[8] This case highlights clinically significant intratracheal extension that was more clearly appreciated on endoscopic evaluation than on initial imaging assessment, emphasizing the importance of adjunctive airway endoscopy in suspected aggressive thyroid malignancies.

CASE REPORT

A 62-year-old male, an ex-smoker with no known comorbidities, presented with a recent onset of breathlessness. He reported a prior episode of hoarseness that had resolved at presentation. There was no dysphagia. On examination, he had a 6x6 cm hard midline neck mass that moved with deglutition with no palpable neck nodes (Figure 1).

CECT showed a heterogeneously enhancing thyroid mass with central necrosis arising from the left lobe and

isthmus, extending into the left thyroid cartilage lamina and anterior strap muscles, with subtle intratracheal extension on imaging (Figure 2), which was more clearly delineated on subsequent endoscopic evaluation revealing a significant intraluminal tracheal mass. PET-CT showed a heterogeneously enhancing metabolically active neck mass (SUVmax 24.1) with bilateral supraclavicular nodal involvement, metabolically active osteolytic lesions in the manubrium sterni and right scapula, and bilateral lung nodules.

Flexible laryngoscopy revealed a large subglottic intratracheal lumen mass occupying more than 80% of the lumen arising from the anterior tracheal wall (Figure 3).

Upper GI Endoscopy was normal. Biopsy revealed the follicular variant of papillary carcinoma. Serum thyroglobulin was 1770 ng/ml, anti-thyroglobulin antibody was 8.36 IU/ml and TSH was 0.0867 µIU/ml. A tracheostomy was performed before induction due to anticipated difficult airway, followed by total thyroidectomy with central and bilateral level II-IV neck dissection, ML excision of the intratracheal mass, and PMMC flap reconstruction of the anterior neck skin defect. Intraoperatively, both thyroid lobes were normal, while the primary tumor arose from the pyramidal lobe extending to the skin edge, with enlarged bilateral level III and IV nodes.

Histopathology confirmed invasive tall cell variant papillary carcinoma (6.5×5×4.5 cm) arising from the isthmus and pyramidal lobe, with no malignancy in either thyroid lobe. It demonstrated extracapsular extension up to the cutaneous margin without epidermal involvement. Lymphatic emboli were present. The subglottic tumour showed non-encapsulated papillary carcinoma.

There was no central compartment node metastasis. Metastatic involvement of papillary carcinoma was noted in 2/30 right-sided and 10/25 left-sided cervical lymph nodes. IHC studies showed CK19 and thyroglobulin were strongly positive with a low proliferative index. BRAF mutation analysis revealed the presence of the V600E mutation. 4 weeks post-surgery, a whole-body scan with 3 mCi of I-131 was done.

It showed evidence of residual active disease in the tracheal wall at the C5-C7 level and the submental region, with no evidence of tracer accumulation in the lung nodules. Radioiodine treatment: 195 mCi of I-131 was administered orally. Post-therapy scan showed intense uptake in the tracheal region and level I node, favouring adequate radioablative effect. The patient remained stable for 18 months before developing sudden breathlessness and hemoptysis.

Chest X-ray revealed right pleural effusion, managed with ICD insertion. Pleural fluid cytology and IHC confirmed anaplastic thyroid carcinoma, following which the patient was transitioned to best supportive care.



Figure 1: Preoperative clinical photograph showing a large midline neck swelling (anterior and lateral views).

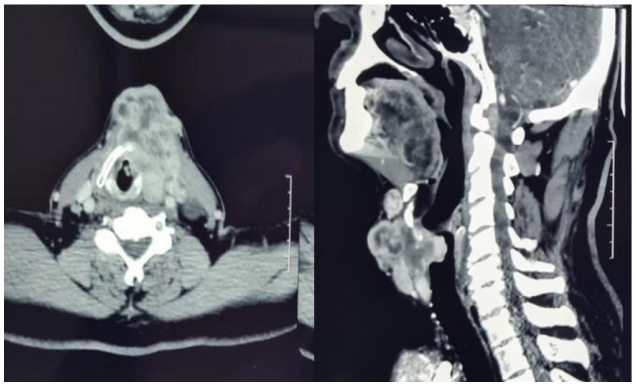

Figure 2: Preoperative CECT neck (axial and sagittal sections) showing a heterogeneously enhancing mass arising from the pyramidal lobe with locoregional extension and subtle intratracheal extension.

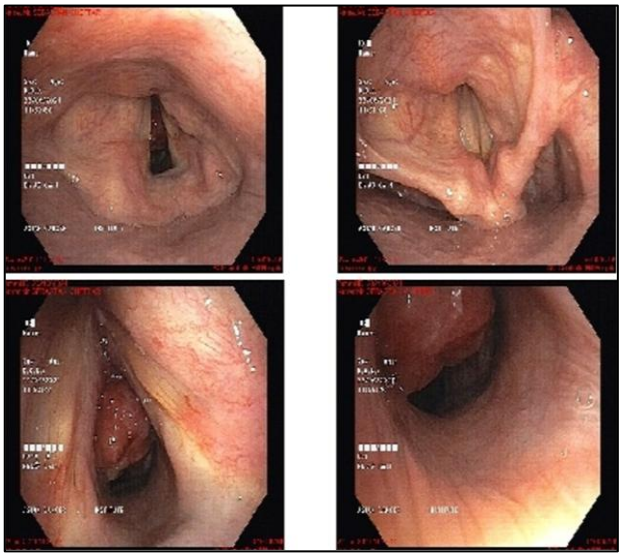

Figure 3: Flexible laryngoscopic images showing a large subglottic intratracheal mass causing >80% luminal compromise.

DISCUSSION

The pyramidal lobe is present in approximately 15-75% of the population and is most commonly connected to the isthmus.[1] Conversely, PTC of the pyramidal lobe is scarce; thus, the clinical and pathological traits of these PTCs are not well understood.[1,5] In contrast with PTC of other locations, Pyramidal lobe PTC has been reported to present later in life (mean of 58 vs. 43 years old), smaller nodule dimension but more frequent extrathyroidal extension, lymphatic invasion, advanced AJCC staging and multifocal location.[9] This patient exhibited nearly all known unfavorable features, consistent with aggressive disease and direct tracheal infiltration. Well-differentiated thyroid carcinomas rarely arise from the pyramidal lobe. The tall cell variant of PTC is characterized by ≥30% tall cells with abundant eosinophilic cytoplasm and classic nuclear features, with recent WHO criteria emphasizing a ≥3:1 height-to-width ratio. BRAFV600E is the most common mutation in PTC and is mainly associated with papillary or mixed papillary-follicular growth patterns.[10] Few studies have described notable connections between BRAF-positive thyroid tumors and poor prognostic indicators, including male gender, older age, lymph node metastasis, extrathyroidal extension, distant metastasis, advanced stage, larger tumor size, and recurrence.[10] Our patient exhibited these adverse features along with BRAF mutation and tracheal invasion. Pyramidal lobe tumors can mimic thyroglossal duct cysts or Delphian node metastasis because of their midline location. Airway symptoms or rapid progression should raise suspicion for aggressive variants such as tall cell PTC. Given the diagnostic and management challenges, Zizic et al proposed grouping these lesions as a distinct entity termed upper neck papillary thyroid cancer (UPTC).

An important learning point from this case is the discordance between imaging and endoscopic findings. Although intratracheal extension was subtle on initial CECT assessment, endoscopy clearly demonstrated significant airway compromise, highlighting the limitations of imaging alone and the importance of routine endoscopic assessment in patients with airway symptoms or aggressive disease features.

CONCLUSION

In conclusion, tall cell variant PTC arising from the pyramidal lobe is a rare and aggressive entity. This case highlights that intratracheal extension in aggressive thyroid malignancies may be underestimated on initial imaging and more clearly defined on endoscopic evaluation, emphasizing the importance of comprehensive airway assessment and early aggressive management.

Funding: No funding sources
Conflict of interest: None declared
Ethical approval: Not required

REFERENCES

1. Braun EM, Windisch G, Wolf G, Hausleitner L, Anderhuber F. The pyramidal lobe: clinical anatomy and its importance in thyroid surgery. Surg Radiol Anat. 2007;29(1):21-7.
2. Ogawa C, Kammori M, Onose H, Yamada E, Shimizu K, Yamada T. Follicular carcinoma arising from the pyramidal lobe of the thyroid. J Nippon Med Sch. 2009;76:169-72.
3. Lee YS, Kim KJ, Kim BW, Chang HS, Park CS. Recurrence of papillary thyroid carcinoma in a remnant pyramidal lobe. ANZ J Surg. 2011;81:304.
4. Ha TK, Kim DW, Park HK, Jung SJ. Papillary thyroid microcarcinoma in a thyroid pyramidal lobe. Ultrasonography. 2014;33:303-6.
5. Santrac N, Besic N, Buta M, Oruci M, Djurisic I, Pupic G, et al. Lymphatic drainage, regional metastases and surgical management of papillary thyroid carcinoma arising in the pyramidal lobe: a single institution experience. Endocr J. 2014;61:55-9.
6. Zizic M, Faquin W, Stephen AE, Kamani D, Nehme R, Slough CM, et al. Upper neck papillary thyroid cancer (UPTC): a new proposed term for the composite of thyroglossal duct cyst-associated papillary thyroid cancer, pyramidal lobe papillary thyroid cancer, and Delphian node papillary thyroid cancer metastasis. Laryngoscope. 2016;126(7):1709-14.
7. Hawk WA, Hazard JB. The many appearances of papillary carcinoma of the thyroid. Cleve Clin Q. 1976;43(4):207-15.
8. Silver CE, Owen RP, Rodrigo JP, Alessandra R, Kenneth OD, Alfio F. Aggressive variants of papillary thyroid carcinoma. Head Neck. 2011;33(7):1052-9.
9. Yoon SG, Yi JW, Seong CY. Clinical characteristics of papillary thyroid carcinoma arising from the pyramidal lobe. Ann. Surg Treat Res. 2017;92:123-8.
10. Erler P, Keutgen XM, Crowley MJ, Zetoune T. Dicer expression and microRNA dysregulation associate with aggressive features in thyroid cancer. Surgery. 2014;156:1342-50.

Cite this article as: Shetty SS, Singh SP, Gulabnabi SA, Parikh D. Papillary thyroid carcinoma arising from the pyramidal lobe with occult intratracheal extension: a rare case report. Int J Otorhinolaryngol Head Neck Surg 2026;12:1057-9.