International Journal of Otorhinolaryngology and Head and Neck Surgery
Gosrani NM et al. Int J Otorhinolaryngol Head Neck Surg. 2026 Dec;12(6):1054-1056
https://www.ijorl.com
pISSN 2454-5929 | eISSN 2454-5937

DOI: https://dx.doi.org/10.18203/issn.2454-5929.ijohns20264293

Case Report

Esophageal denture impaction presenting with stridor: a rare airway emergency

Nikesh M. Gosrani[1]*, Shrekha K. Padmakshan, Vineet Vijay Choudhary

[1]Department of ENT, VIMS Dahanu, Maharashtra, India
[2]Department of ENT, Fortis Hospital Kalyan, Maharashtra, India
[3]Department of Gastroenterology, Fortis Hospital Kalyan, Maharashtra, India

Received: 20 September 2026
Revised: 17 October 2026
Accepted: 20 October 2026

***Correspondence:**
Dr. Nikesh M. Gosrani,
E-mail: gosraninikesh@gmail.com

Copyright: © the author(s), publisher and licensee Medip Academy. This is an open-access article distributed under the terms of the Creative Commons Attribution Non-Commercial License, which permits unrestricted non-commercial use, distribution, and reproduction in any medium, provided the original work is properly cited.

ABSTRACT

Esophageal foreign bodies in adults commonly present with dysphagia; airway compromise in the form of stridor is rare and potentially life-threatening. We report a case of an impacted partial denture at the cricopharynx presenting with acute stridor requiring emergency tracheostomy. Imaging and endoscopic evaluation confirmed the diagnosis. Flexible endoscopic retrieval failed due to size and impaction, necessitating successful removal by rigid esophagoscopy. This case highlights the importance of early airway management, high index of suspicion, and the continued relevance of rigid esophagoscopy in managing complex esophageal foreign bodies.

Keywords: Denture, Esophageal foreign body, Stridor, Cricopharynx, Rigid esophagoscopy

INTRODUCTION

Foreign body ingestion is a common clinical emergency encountered in otolaryngology practice. In adults, denture ingestion represents a significant subset of esophageal foreign bodies due to reduced palatal sensation and impaired proprioception associated with dental prostheses.[1,2]

Dentures are particularly hazardous because of their irregular shape, sharp components, and radiolucent acrylic material, often resulting in delayed diagnosis and increased risk of complications.[3,4]

Most esophageal foreign bodies present with dysphagia, odynophagia, or retrosternal discomfort.[2,5] Presentation with stridor is rare and signifies airway compromise due to posterior laryngeal compression or inflammatory edema at the cricopharyngeal level.[5,6]

Recent guidelines emphasize early recognition and urgent management of proximally impacted foreign bodies due to the risk of airway obstruction and perforation.[7,8]

This report demonstrates a rare case of long-standing denture impaction at the cricopharynx presenting primarily with acute stridor requiring emergency airway intervention.

CASE REPORT

A 54-year-old male was presented to the emergency department with acute onset stridor hoarseness of voice and dysphagia. There was no definite history of foreign body ingestion at presentation

Airway management

Given impending airway compromise, an emergency tracheostomy was performed to secure the airway.

Imaging

A contrast-enhanced CT scan with oral contrast revealed a suspicious foreign body lodged at the cricopharyngeal region/upper esophagus whch is shown in below figure 1 a & 1b.

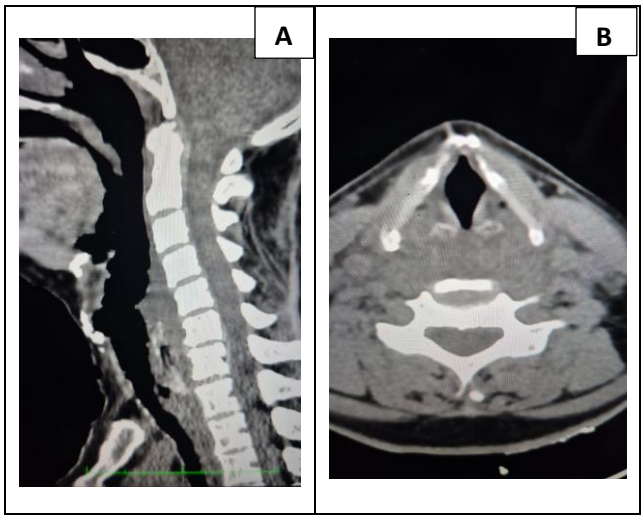

Figure 1 (A and B): CECT of oropharynx in sagittal and axial section.

Endoscopic findings

Flexible oesophagogastroduodenoscopy (OGD scopy) demonstrated:

A reddish, hard structure Creating the appearance of dual luminal passages, suggestive of a large impacted object which is shown in below figure 2

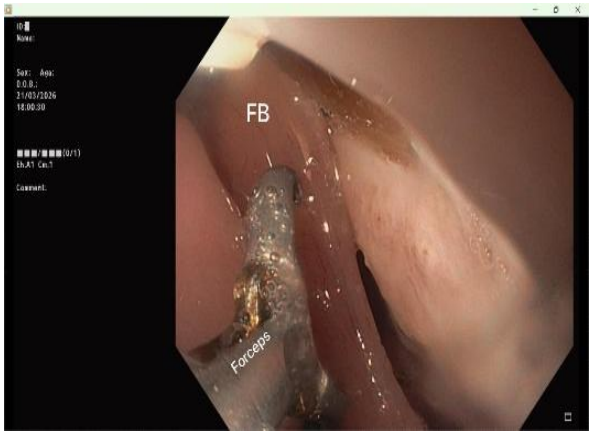

Figure 2: Endoscopic view demonstrating impacted foreign body.

Retrospective history

On further questioning, the patient reported that his partial denture had been missing for approximately one month, which had gone unnoticed.

Definitive management

A repeat attempt at removal using flexible endoscopy failed due to the large size of the foreign body, narrow esophageal lumen and firm impaction.

Subsequently, rigid esophagoscopy under general anesthesia was performed, and the foreign body—a partial acrylic denture with artificial incisors—was successfully retrieved which is shown below Figure 3.



Figure 3: Retrieved acrylic denture with two incisor teeth

Outcomes

The postoperative period was uneventful. The patient was monitored for complications such as perforation and mediastinitis. The tracheostomy was managed and later successfully decannulated.

DISCUSSION

The cricopharynx is the most common site of esophageal foreign body impaction due to its anatomical narrowing.[2,3] Dentures pose a higher risk of impaction and complications because of their size, irregular contours, and embedded clasps.[4,6]

Delayed presentation significantly increases the likelihood of pressure necrosis, ulceration, perforation, and mediastinitis.[4,9] In our patient, the denture remained impacted for approximately one month before diagnosis, highlighting the importance of detailed history-taking.

Stridor as a presenting symptom is uncommon but clinically significant. Airway compromise may occur due to posterior laryngeal wall compression, edema of the post-cricoid region, or secondary inflammatory changes.[5,6] According to recent ESGE guidelines, airway stabilization is the first priority in patients presenting with signs of respiratory distress.[7]

Plain radiographs may fail to detect acrylic dentures because of their radiolucency.[6] Computed tomography has emerged as a highly sensitive modality for detecting

radiolucent foreign bodies and assessing associated complications.[8,10]

Flexible endoscopy is commonly used as first-line management; however, large, irregular, and impacted dentures frequently require rigid esophagoscopy for safe extraction.[1,3,9] Rigid esophagoscopy provides superior control, direct visualization, and airway protection, particularly in proximally impacted foreign bodies, as demonstrated in our case.[3,5]

This case underscores the need for high clinical suspicion in patients with dentures presenting with unexplained airway symptoms. Early airway control combined with definitive endoscopic removal is essential to prevent life-threatening complications.

CONCLUSION

Esophageal denture impaction may present atypically with stridor, representing a life-threatening airway emergency. Prompt airway management, careful history-taking, and appropriate use of imaging are essential.

Rigid esophagoscopy continues to play a crucial role in the management of complex esophageal foreign bodies.

Funding: No funding sources
Conflict of interest: None declared
Ethical approval: Not required

REFERENCES

1. Webb WA. Management of foreign bodies of the upper gastrointestinal tract. Gastroenterology. 1988;94(1):204–216.\
2. Nandi P, Ong GB. Foreign body in the oesophagus: review of 2394 cases. Br J Surg. 1978;65(1):5–9.\
3. Athanassiadi K, Gerazounis M, Metaxas E, Kalantzi N. Management of esophageal foreign bodies: a retrospective review of 400 cases. Eur J Cardiothorac Surg. 2002;21(4):653–656.
4. Hong KH, Kim YJ, Kim JH. Risk factors for complications associated with upper gastrointestinal foreign bodies. World J Gastroenterol. 2015;21(26):8125-31.
5. Singh B, Kantu M, Har-El G, Lucente FE. Complications associated with 327 foreign bodies of the pharynx, larynx, and esophagus. Ann Otol Rhinol Laryngol. 1997;106(4):301-4.
6. Mughal Z, Charlton AR, Dwivedi R, Natesh B. Impacted denture in the oesophagus: review of the literature and its management. BMJ Case Rep. 2019;12(10):e229655.
7. \Birk M, Bauerfeind P, Deprez PH, et al. Removal of foreign bodies in the upper gastrointestinal tract in adults: ESGE clinical guideline. Endoscopy. 2016;48:489–496.
8. ASGE Standards of Practice Committee, Ikenberry SO, Jue TL, Anderson MA, Appalaneni V, Banerjee S, et al. Management of ingested foreign bodies and food impactions. Gastrointest Endosc. 2011;73(6):1085–1091.
9. Vizcarrondo FJ, Brady PG, Nord HJ. Foreign bodies of the upper gastrointestinal tract. Gastrointest Endosc. 1983;29:208–10.
10. Ambe P, Weber SA, Schauer M, Knoefel WT. Swallowed foreign bodies in adults. Dtsch Arztebl Int. 2012;109(50):869–75.

Cite this article as: Gosrani NM, Padmakshan SK, Choudhary VV. Esophageal denture impaction presenting with stridor: a rare airway emergency. Int J Otorhinolaryngol Head Neck Surg 2026;12:1054-6.