International Journal of Otorhinolaryngology and Head and Neck Surgery
Rudrappa M et al. Int J Otorhinolaryngol Head Neck Surg. 2026 Dec;12(6):1051-1053
https://www.ijorl.com
pISSN 2454-5929 | eISSN 2454-5937
DOI: https://dx.doi.org/10.18203/issn.2454-5929.ijohns20264292

Case Report

A decade long staghorn megalith in submandibular gland: a case report

Monisha Rudrappa*, Nitty Mathew, Prateek Nayak

Department of Otorhinolaryngology and Head and Neck Surgery, Aster CMI, Hebbal, Bengaluru, Karnataka, India

Received:10 September 2026
Revised: 14 October 2026
Accepted: 21 October 2026

***Correspondence:**
Dr. Monisha Rudrappa,
E-mail: monisha.0879@gmail.com

Copyright: © the author(s), publisher and licensee Medip Academy. This is an open-access article distributed under the terms of the Creative Commons Attribution Non-Commercial License, which permits unrestricted non-commercial use, distribution, and reproduction in any medium, provided the original work is properly cited.

ABSTRACT

Sialolithiasis is the most common salivary gland disease. Sialolith occurs mainly in submandibular gland (80-90%). Pain and swelling in the salivary glands, especially during mealtimes suggests the diagnosis. Giant sialolith or megalith present with these symptoms, by saliva accumulation in the submandibular gland by obstructing the Wharton's duct. Surgical management should be considered when the stone is inaccessible or large in size. In this paper we report an unusually large staghorn submandibular sialolith that presented as a left-sided neck mass for ten years. Surgical excision of the submandibular gland was performed as the giant sialolith of approximately 45 mm x 40 mm occupied the entire gland, leading to squamous metaplasia.

Keywords: Sialolithiasis, Submandibular sialolith, Chronic sialadenitis, Squamous metaplasia, End-stage salivary gland disease

INTRODUCTION

Sialolithiasis is a most common salivary gland disease with incidence of 12 in 1000 adult population. It usually affects the mid age group (30-60 years). This disease affects men twice more than women.[1,2] The prevalence of sialolithiasis is more than 80% in submandibular gland,4-10% in the parotid gland and 2% in the sublingual gland. Sialolithiasis is the formation of stones in the salivary gland or their ducts. sialolith means a calcified mass. It presents as swelling and pain in the affected gland by blocking the duct, the symptoms are more severe if the duct is completely blocked and during meals and can recur. Stone larger than 15mm in its greater dimension is defined as megaliths or giant sialolith, which are not common

The etiology of salivary gland stone formation is poorly understood.[2] The stone is comprised of carbonates in the form of hydroxyapatite, lesser amount of calcium phosphate, magnesium, potassium and ammonia.[3,4] The submandibular glands stone consists of 82% inorganic and 18% organic materials (carbohydrates and amino acids), the parotid gland stones consist of 49% inorganic and 51% organic materials. The anatomical location of submandibular gland and duct, alkaline PH helps in the formation of stone.[4]

CASE REPORT

A 75-year-old male patient came to our otorhinolaryngology outpatient department with chief complaint of recurrent episodes of pain, difficulty in swallowing and swelling in the left lower jaw for a duration of 10 years. During the prolonged duration, the patient had classic postprandial salivary colic, with a medical history of diabetes mellitus, hypertension, ischemic heart disease.

On extraoral examination, a diffuse swelling was seen in left submandibular region. On bimanual palpation left submandibular gland was hard and tender. Intraoral examination showed mild elevation of tongue and left submandibular duct opening was inflamed and erythematous

The ultrasound (USG) of the neck showed features of chronic left submandibular sialadenitis with significantly dilated intraglandular ductules and impacted large calculi of about 45mm. Under general anaesthesia, a left transcervical incision put and left submandibular gland with stone in situ was excised successfully (Figure 1A and 1B). The drain was placed and secured with sutures to prevent collections. The excised submandibular gland was about 55mm (Figure 2) and giant staghorn stone was about 45mm (Figure 3), which was seen impacted in the gland. The patient developed severe swelling post procedure which was medically managed. In the later follow up after 10 days, a small fistula was seen at the operative site which healed by regular dressing and medical management.

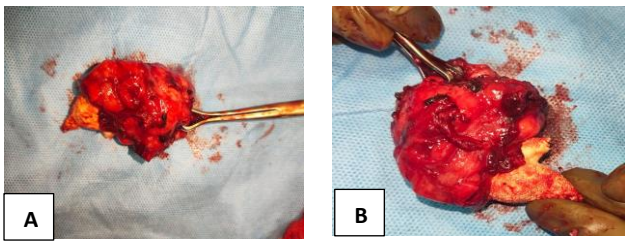

Figure 1 (A and B): Excised left submandibular gland with stone in situ.



Figure 2: Left submandibular gland measuring 55 mm.



Figure 3: Staghorn sialolith measuring 45 mm.

DISCUSSION

Stones larger than 15mm are classified as giant sialolith or megaliths. Sialoliths are usually of 5 mm in maximum diameter and all stones over 10mm should be reported as unusual size. One of the largest sialoliths of 72mm size was reported by Rai et al Our case reports a giant staghorn sialolith of about 45mm.

Aetiology

The definite aetiology of sialolith is poorly understood, sialolith is the deposition of mineral salts around an initial nidus consisting of salivary mucin, bacteria, or desquamated epithelial cells.[5] The mineralization of this debris accumulated in the lumen of the duct and form sialolith. Submandibular stones are frequently formed around a nidus of mucus. Factors like stagnation of salivary flow, dehydration, and change in salivary pH with oropharyngeal sepsis, impaired crystalloid solubility, high alkalinity, and increased calcium content predispose to calculus formation.

The sialolith is formed in two stages, the central core formation and layered periphery formation.[6] In the initial phase, mineral salts bound by certain organic substances forms the central core. Then, in the second phase, some organic and inorganic materials deposit around the central core in layers. Parotid stones are frequently formed around a nidus of inflammatory cells or foreign body and submandibular stones around nidus of mucous. A retrograde theory suggested that any substance or bacteria of the oral cavity, that had migrated into the salivary ducts, can act as a nidus for further calcification.[6] Boynton et al reported an unusual case in which a facial hair of the patient got entrapped in the Wharton's duct and acted as a nidus for the formation of a sialolith.[7]

Long standing obstruction by a sialolith can severely damage the acini of the gland, resulting in a permanent decrease or even absence of salivary secretions, and can lead to recurrent infection, atrophy of the gland with loss of secretory function and ultimately fibrosis.[8]

Diagnosis

The history and examination help in the diagnosis of sialolithiasis. Bimanual palpation of the floor of mouth, in posterior to anterior direction helps in detection of stones in submandibular gland. Pain and swelling of the involved gland especially at mealtimes are diagnostic markers in acute or subacute phases. Constant pain and swelling, with pus draining from the duct is seen in complete obstruction[8]. Long-standing obstruction causes end-stage changes in the glands. A uniformly firm and hard gland suggests a hypo-functional or non-functional fibrotic gland.[9,10]

Ultrasonography is the diagnostic tool for submandibular sialolithiasis with sensitivity and specificity between 90%

and 95% respectively, reported by Katz *et al*. and various other authors[7]. The major drawback of ultrasound is undetection of the smaller calculi (<3mm).[1]

Treatment

The stone removal depends mainly on the location of stone, size and number of stone, duration of symptoms, number of recurrent episodes[3]. Conservative management is tried when the stone is small, patient must be well hydrated and applied warm moist heat and gland massage, the sialogogues helps in saliva production and flushing the stone out.[2]

If small stones are located in the distal third of the submandibular duct, simple surgery through an incision at the floor of the mouth can be used to remove the stone, it is simple and usually not associated with complications. If the stone is located anterior, the stone can be massaged and manipulated through the duct orifice, the lacrimal probe and dilators are used to open the duct. Once open, the stone can be identified, milked out and removed. The gland is then massaged to remove other debris in the posterior part of the duct.[2,10]

Sometimes the duct may need opening to retrieve the stone, then a transoral approach is planned where the incision is made directly onto the stone location. Through this approach, a more posterior stone/stones can be removed by cutting directly on the longitudinal axis of the duct[8].Care is taken not to injure lingual nerve which lies in close association to submandibular duct posteriorly. The stone is removed and duct is left open for drainage.[2,10]

Large stones which have damaged the gland by recurrent infection and fibrosis or if stone been has formed in the salivary gland, then the whole gland to be removed[2,5] Complications that may occur are scar tissue, paraesthesia of the lingual nerve.

CONCLUSION

Giant salivary calculi of prolonged duration are rare; most cases present with the classical picture of salivary colic. In our case, patient presented with swelling and pain at the meal time when saliva production increases. The prolonged obstruction of submandibular gland by giant sialolith led to irreversible destruction. Retaining such a gland poses a high risk of recurrent deep neck space infections and metaplasia. Surgical excision of submandibular gland is the definitive management and prevents future complications.

Funding: No funding sources
Conflict of interest: None declared
Ethical approval: Not required

REFERENCES

1. Mahoorkar S, Sunder VS, Chakravarthy C, Mikkilinine R. Multiple bilateral submandibular gland sialolithiasis. Niger J Clin Pract. 2014;17(1):115–8.
2. Siddiqui SJ. Sialolithiasis: an unusually large submandibular salivary stone. Br Dent J. 2002;193:89–91.
3. Mouli C, Kumar SM, Subramanian K, Shanmugam S, Satish S. Sialolith: a case report with review of literature. Indian J Multidiscip Dent. 2011;1:377–9.
4. Grases F, Santiago C, Simonet BM, Costa-Bauzá A. Sialolithiasis: mechanism of calculi formation and etiologic factors. Clin Chim Acta. 2003;334(1–2):131–6.
5. Pachisia S, Mandal G, Sahu S, Ghosh S. Submandibular sialolithiasis: a series of three case reports with review of literature. Clin Pract. 2019;9(1):1119.
6. Marchal F, Kurt AM, Dulguerov P, Lehmann W. Retrograde theory in sialolithiasis formation. Arch Otolaryngol Head Neck Surg. 2001;127:66–8.
7. Katz P, Hart DM, Guerre A. Clinical ultrasound of the salivary glands. Otolaryngol Clin North Am. 2009;42:973–1000.
8. Pollack CV, Severance HW. Sialolithiasis: case studies and review. J Emerg Med. 1990;8(5):561–5.
9. Leung AK, Choi MC, Wagner GA. Multiple sialoliths and a sialolith of unusual size in the submandibular duct: a case report. Oral Surg Oral Med Oral Pathol Oral Radiol Endod. 1999;87(3):331–2.
10. Mathew N, Asharaf AA, Nayak PP. An interesting case of asymptomatic giant submandibular sialolithiasis: a case report. Int J Otorhinolaryngol Head Neck Surg. 2024;10:572–4.

Cite this article as: Rudrappa M, Mathew N, Nayak P. A decade-long staghorn megalith in submandibular gland: a case report. Int J Otorhinolaryngol Head Neck Surg 2026;12:1051-3.