International Journal of Otorhinolaryngology and Head and Neck Surgery
Mathew N et al. Int J Otorhinolaryngol Head Neck Surg. 2026 Dec;12(6):1047-1050
https://www.ijorl.com
pISSN 2454-5929 | eISSN 2454-5937

DOI: https://dx.doi.org/10.18203/issn.2454-5929.ijohns20264291

Case Report

The hidden threat, high stakes in the deep cranium — restoring vision in a case of sphenoid sinus mucopyocele in a diabetic patient: an interesting case report

Nitty Mathew*, Monisha Rudrappa, Prateek Nayak

Department of Otorhinolaryngology, Aster CMI Hospital, Hebbal, Bangalore, Karnataka, India

Received: 04 September 2026
Revised: 13 October 2026
Accepted: 17 October 2026

***Correspondence:**
Dr. Nitty Mathew,
E-mail: nm6588@gmail.com

Copyright: © the author(s), publisher and licensee Medip Academy. This is an open-access article distributed under the terms of the Creative Commons Attribution Non-Commercial License, which permits unrestricted non-commercial use, distribution, and reproduction in any medium, provided the original work is properly cited.

ABSTRACT

An isolated sphenoid sinus mucocele or mucopyocele is one of the very rare pathologies that an otorhinolaryngologist may encounter. Initial symptoms can be non-specific like a deep seated or vague headache, while emergence of compression symptoms like decreased vision, ophthalmoplegia or any intracranial complications warrants immediate attention. Here we present a case of 56-year-old diabetic and hypertensive patient who presented with sudden onset of reduced vision in the left eye. Ophthalmology opinion, magnetic resonance imaging (MRI) and contrast enhanced computerized tomography (CECT) of nose and paranasal sinuses were done and the diagnosis of an isolated sphenoid sinus mucopyocele causing compressive optic neuropathy on the left side was made, prompting a decompression surgery with immediate postoperative improvement in vision. A high index of suspicion, relevant cross-sectional imaging and timely surgical intervention can prevent further damage and like in the reported scenario, restore patient's vision to near normal parameters.

Keywords: Sphenoid sinus mucopyocele, Isolated sphenoid sinus mucocele, Paranasal sinus mucoceles, Compression optic neuropathy, Case report

INTRODUCTION

Paranasal sinus mucoceles are epithelium-lined, encapsulated lesions filled with mucous, which has the potential to erode bone.[1] They are found to most commonly affect the frontal, ethmoid and maxillary sinuses. Sphenoid sinus mucoceles are exceptionally rare, have <2% of incidence,[2] yet has a high-stakes localization. Due to its close proximity to neural and vascular structures, delay in diagnosis results in debilitating complications such as visual disturbances or intracranial extension.[1] The incidence of sphenoid mucopyoceles is still rare. Here we report a case of sphenoid sinus mucopyocele in a patient with diabetes mellites and hypertension causing left eye compression optic neuropathy, who had significant vision improvement post-surgical decompression.

CASE REPORT

A 56-year-old female patient, known case of type 2 diabetes mellites and hypertension, presented to the otorhinolaryngology outpatient department of our tertiary care center with history of reduced vision in the left eye since 1 week. She had been evaluated in an ophthalmology center and had an MRI report as having an expansile cystic lesion completely occupying the sphenoid sinus 3.58cm*2.7cm*2.6cm. It was T1 hyper intense and T2/FLAIR hyper intense with mild peripheral smooth enhancement seen on post contrast images.

Delano classification Type 3 course of left optic nerve with significant bony wall rarefaction, likely compression of the intracranial segment of the left optic nerve was also noted. Mild prominence of left perioptic cerebrospinal space was seen without any altered signal. No significant compression of right optic nerve was noted.

Ophthalmology opinion was sought in our hospital and vision was documented. Right pupil was reactive to light, while left eye had an afferent pupillary defect indicating left optic nerve dysfunction. Colour vision was normal in the right eye, while left eye was abnormal. Preoperative left eye vision was documented as 1/60.

Patient was admitted and relevant blood investigations done. She had Hba1c of 8.1. Contrast enhanced computerized tomography of nose and paranasal sinuses was done which showed diffuse opacification of sphenoid sinus and left posterior ethmoid air cells with mild hyperdense contents causing expansion of sinus with thinning of bony walls (Figure 1a and 1b). Pituitary gland appeared unremarkable. Expansion of sphenoid sinus could be seen causing narrowing of left optic canal and abutting the optic nerve.

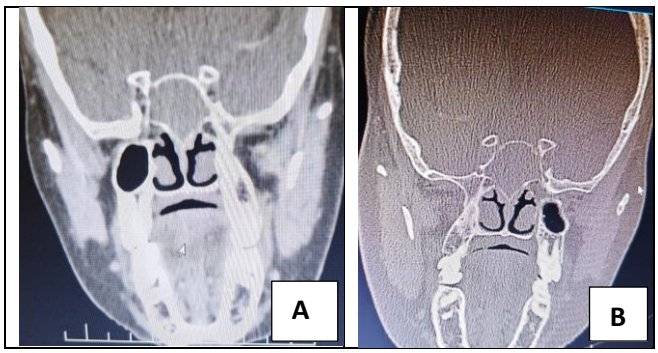

Figure 1 (A and B): Coronal view- contrast enhanced computerized tomography of nose and paranasal sinuses showing diffuse opacification of sphenoid sinus.

Preanesthetic checkup was done and patient was posted for endoscopic trans nasal sphenoidotomy with marsupialization surgery after obtaining informed consent. Under general anesthesia, bilateral nasal cavity was decongested, left sphenoid sinus ostium was identified. Left middle turbinectomy was done to expose the sphenoid sinus ostium further. The sphenoid sinus ostium was widened by doing a posterior septostomy and around 16ml of pus was collected from the sinus (Figure 2) and sent for pus culture sensitivity, KOH (potassium hydroxide) staining study, fungal culture and sensitivity and Real-time PCR (RT-PCR) for tuberculosis (TB)TB RT PCR

Biopsy was taken from the sphenoid sinus mucosa and sent for histopathology examination. Care was taken to avoid excess pressure and stripping of the sphenoid sinus mucocele blindly as to protect the optic nerve and avoid injuries. After marsupialization of the mucopyocele and widening of sphenoid sinus ostium, the cavity was washed with diluted betadine solution and bilateral nasal cavity packing was done (Figure 3 and 4).



Figure 2: Pus from sphenoid sinus collected in a sterile mucus extractor.

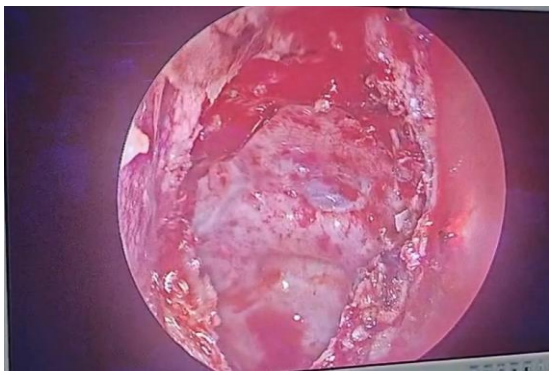

Figure 3: Endoscopic trans nasal view of marsupialised sphenoid sinus.

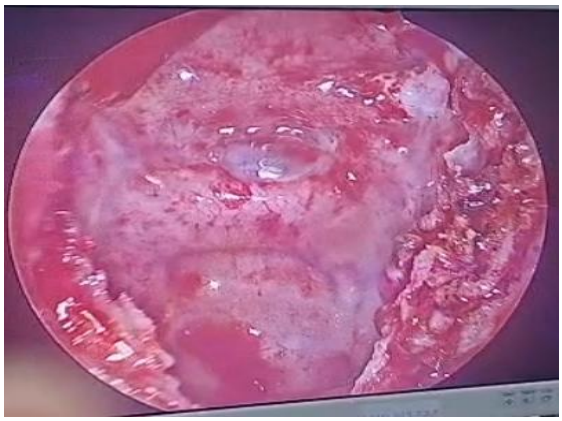

Figure 4: Endoscopic trans nasal view of marsupialised sphenoid sinus with Left optic nerve visualized.

In the peri operative period patient was administered intravenous cefotaxime1gram twice daily for 5 days and intravenous amikacin 750mg once daily for 3 days. Post operatively once gram staining was found negative, in view of the left optic neuropathy intravenous high dose corticosteroid (methylprednisolone 1gm) was also given twice daily for three days.

Internal medicine opinion was sought in view of diabetic management. Ophthalmology opinion was serially done to analyze the vision changes and serial improvement in vision was observed and documented. Immediate post-operative vision was documented in the left eye to be 6/18(from a preoperative vision of 1/60).

After 3 days of administering intravenous antibiotics and high dose corticosteroids, patient was stable and was discharged on oral antibiotics and tapering dose of oral steroids. The histopathology report showed features of acute on chronic sinusitis. The pus from sphenoid sinus sent for KOH (potassium hydroxide) staining, fungal culture and sensitivity was reported negative for any fungal growth. Tissue Real-time PCR (RT-PCR) for tuberculosis (TB) was also reported negative.

As of the day of writing the case report, patient was reviewed 2 months post op and found to have similar vision.

In this scenario, high index of suspicion, early diagnosis using cross sectional imaging modalities, timely surgical intervention and multidisciplinary management resulted in improving the vision outcome of the patient to near normal parameters

DISCUSSION

A sphenoid sinus mucocele is a benign pathology, a sterile retention cyst, but the symptoms of which are dictated entirely by the geography it is situated in. Its clinical manifestations from nonspecific headaches to permanent blindness are determined strictly by millimeter scale expansion into the adjacent neural and vascular structures. This is due to anatomical relations of the sphenoid sinus with the brain, meninges, optic nerve, internal carotid artery, cavernous sinus and cranial nerve (oculomotor, trochlear, ophthalmic and maxillary branches of the trigeminal nerve and abducens).[3]

Sphenoid sinus mucoceles develop from a sequential mechanical failure of obstruction of sphenoid sinus ostium which leads to retention of secretions. Mucoid secretions become permanently trapped within the respiratory epithelium lining the sinus and the gradual, relentless buildup of fluid creates a pressurized, encapsulated cystic lesion. Thus, the thin sinus wall expands and remodel outwards under mechanical stress. A mucocele expands gradually over years and presents with vague persistent headache. A pyocele is when a mucocele becomes secondarily infected and patient presents with rapid clinical deterioration with acute visual impairment, diplopia, ocular pain and cranial nerve palsies.[4] The mechanism of vision loss has been attributed to optic nerve ischemia and secondary to displacement and compression.[5]

Expanding sphenoid sinus mucocele may compress the optic nerve or the cavernous sinus which carries the III, IV and VI nerves. So that sphenoid sinus mucocele should be kept in mind in cases of visual disturbances or III, IV and VI nerves palsy.[6] Sphenoid sinus mucocele may present with painful ophthalmoplegia. Differential diagnosis of lesions producing painful Ophthalmoplegia includes pituitary apoplexy, ruptured intracranial berry aneurysm involving posterior communicating artery or the cavernous segment of the internal carotid artery, caroticocavernous fistula, nasopharyngeal carcinoma, metastatic carcinoma, herpes zoster Ophthalmicus, Tolosa-Hunt syndrome and Ophthalmoplegic migraine.[7] Because the sphenoid sinus is inaccessible to standard clinical examination, cross sectional imaging like Computed Tomography (CT) and Magnetic Resonance Imaging (MRI) serves as the definitive diagnostic lens. CT delineates precise anatomical limits, assesses structural bone remodeling and detects critical bony erosion or osseus dehiscence.[8] MRI assesses expansive soft tissue extension, identifies intracranial or orbital involvement and determines specific fluid composition via signal intensity.

MRI signal intensity in sphenoid mucoceles is highly variable and depends strictly on the protein and mucous concentration within the cyst.[9] Standard fluid with low protein is seen as hypointense in T1 (dark) and hyperintense in T2 (bright) while high protein content is seen as hyperintense in T1 (bright) and hyperintense in T2 (bright). Thick inspissated mucous is hyperintense in T1 (bright) and hypointense in T2 (dark). A mucopyocele typically is seen as a peripherally enhancing lesion in imaging due to acute inflammation.

In this case the imaging showed Type 3 delano (type 3**:** 6%; nerve courses through the sphenoidal sinus rather than simply running adjacent to the sinus) course of left optic nerve with significant bony wall rarefaction, thus warranting extreme caution during surgical decompression so as to avoid injury to optic nerve.[10] This underlines the need for relevant imaging and understanding of anatomical variants prior to surgical procedure.

Endoscopic surgical procedure involving decompression and wide marsupialization is the gold standard of treatment of mucopyoceles of sphenoid sinus. It involves identification of the natural ostium of the sphenoid sinus via transnasal endoscopy, enlarging the ostium to gain necessary visibility for which middle turbinectomy may be done. Marsupialization or opening the cyst wall and completely evacuating the mucoid secretion or purulent pus is the most essential step. Excess pressure, aggressive

blind curettage near sinus roof and stripping of the sphenoid sinus mucocele blindly is to be completely avoided as to protect the optic nerve and avoid injuries.

Post decompression surgery it is imperative to continue with medical management especially in the setting of an inflammatory optic neuritis. Use of high dose intravenous methylprednisolone under controlled settings have been advocated to try and revert the injury to the optic nerve as well to prevent further axonal injury. First, the steroid helps any associated optic neuritis secondary to spread of inflammation from the sphenoidal mucocele. Second, the steroid in combination with the nasal decongestants treats the osteal inflammation thus allowing drainage and decompression of the mucocele. The oral steroid assists in reducing the optic nerve swelling secondary to compression. Intravenous steroids are found to be more beneficial for a more rapid recovery due to higher dosage and earlier onset of action .[11]

CONCLUSION

An isolated persistent headache, especially with a history of prior sinus surgery or fungal infection, mandates cross sectional imaging (CT/MRI) to rule out deep cranial expansion

Preoperative identification of sinus anatomy, its variants and precise spatial mapping of the optic nerve and internal carotid artery are nonnegotiable prerequisites for safe endoscopic clearance.

While compressive headaches are instantly reversible post decompression, visual acuity deficits caused by mucopyoceles or nerve compression often become permanent if intervention is delayed.

Recurrence rates are exceptionally low when modern endoscopic marsupialization is utilized over external approaches.

Funding: No funding sources
Conflict of interest: None declared
Ethical approval: Not required

REFERENCES

1. Raguraman S, Kushwaha A, Kumar PL, Kumar S. One more chance to see the world: a rare case report on sphenoid mucocele causing vision loss. Int J Appl Basic Med Res. 2023;13(3):180-2.
2. Kösling S, Hintner M, Brandt S, Schulz T, Bloching M. Mucoceles of the sphenoid sinus. Eur J Radiol. 2004;51:1-5.
3. Mra Z, Roach JC, Brook A. Infectious and neoplastic diseases of the sphenoid sinus: a report of 10 cases. Rhinology. 2002;40(1):34-40.
4. Singh D, Sohal BS, Aggarwal S. Isolated sphenoid pyocele with Thornwaldt's cyst of nasopharynx. Indian J Otolaryngol Head Neck Surg. 2011;63(1):140-1.
5. Li E, Howard MA, Vining EM, Becker RD, Silbert J, Lesser RL. Visual prognosis in compressive optic neuropathy secondary to sinus mucocele: a systematic review. Orbit. 2018;37:280-6.
6. Moriyama H, Hesaka H, Tachibana T, Honda Y. Mucoceles of ethmoid and sphenoid sinus with visual disturbance. Arch Otolaryngol Head Neck Surg. 1992;118:142-6.
7. Lee LA, Huang CC, Lee TJ. Prolonged visual disturbance secondary to isolated sphenoid sinus disease. Laryngoscope. 2004;114:986-9.
8. Topdag M, Iseri M, Sari F, Erdogan S, Keskin IG. Paranasal sinus mucoceles: our clinical experiments. Int J Clin Exp Med. 2015;8:18518-22.
9. Lasrado S, Moras K, Jacob C. A rare case of sphenoid sinus mucocele presenting with lateral rectus palsy. Indian J Otolaryngol Head Neck Surg. 2022;74(Suppl 2):1396-8.
10. DeLano M, Fun F, Zinreich SJ. Relationship of the optic nerve to the posterior paranasal sinuses: a CT anatomic study. Am J Ophthalmol. 1996;122(2):293-4.
11. Mowatt L, Foster T. Sphenoidal sinus mucocele presenting with acute visual loss in a scuba diver. BMJ Case Rep. 2013;2013:bcr2013010309.

Cite this article as: Mathew N, Rudrappa M, Nayak P. The hidden threat: high stakes in the deep cranium — restoring vision in a case of sphenoid sinus mucopyocele in a diabetic patient: an interesting case report. Int J Otorhinolaryngol Head Neck Surg 2026;12:1047-50.