International Journal of Otorhinolaryngology and Head and Neck Surgery
Mishra G et al. Int J Otorhinolaryngol Head Neck Surg. 2026 Dec;12(6):1041-1046
https://www.ijorl.com
pISSN 2454-5929 | eISSN 2454-5937

DOI: https://dx.doi.org/10.18203/issn.2454-5929.ijohns20264290

Case Report

Recurrent extraocular sebaceous carcinoma of the pinna with temporal extension: a rare case report

Girish Mishra, Dhaval Amin, Ruju Vadaviya*, Akash Ramani

Department of Otorhinolaryngology and Head & Neck Surgery, Pramukhswami Medical College, Bhaikaka University, Karamsad, Gujarat, India

Received: 24 August 2026
Revised: 04 November 2026
Accepted: 12 November 2026

***Correspondence:**
Dr. Ruju Vadaviya,
E-mail: rbvadaviya@gmail.com

Copyright: © the author(s), publisher and licensee Medip Academy. This is an open-access article distributed under the terms of the Creative Commons Attribution Non-Commercial License, which permits unrestricted non-commercial use, distribution, and reproduction in any medium, provided the original work is properly cited.

ABSTRACT

Sebaceous carcinoma is a rare, aggressive cutaneous malignancy that most commonly arises in the periocular region. Extraocular sebaceous carcinoma involving the pinna is exceptionally uncommon and poses significant diagnostic and therapeutic challenges due to its rarity and propensity for local recurrence. We report the case of a 48-year-old woman with recurrent sebaceous carcinoma of the left pinna extending to the temporal region, following previous surgical excision. Clinical examination, contrast-enhanced computed tomography, and positron emission tomography-computed tomography were performed to evaluate the extent of disease. The patient underwent wide local excision of the involved pinna, temporal, and parotid regions with left supraomohyoid neck dissection, followed by staged reconstruction using an anterolateral thigh free flap, supraclavicular flap, and split-thickness skin graft. Histopathological examination confirmed sebaceous carcinoma with tumor-free surgical margins and no cervical lymph node metastasis. Immunohistochemistry supported sebaceous differentiation, while retained mismatch-repair protein expression did not demonstrate mismatch-repair deficiency. The postoperative course was uneventful, and the patient remains disease-free on follow-up. This case highlights the importance of early diagnosis, complete surgical excision with adequate margins, appropriate reconstruction, and vigilant long-term surveillance in managing this rare malignancy.

Keywords: Sebaceous carcinoma, Pinna, Extraocular sebaceous carcinoma, Cutaneous malignancy, Head and neck neoplasms, Reconstruction

INTRODUCTION

Sebaceous carcinoma is an uncommon malignant tumor arising from sebaceous glands and accounts for less than 1% of all cutaneous malignancies.[1] It is broadly classified into periocular and extraocular types, with periocular lesions being more common due to the abundance of sebaceous glands in the eyelids.[2] Extraocular sebaceous carcinoma primarily involves the head and neck region but rarely affects the pinna.[3] The tumor often mimics benign adnexal lesions, resulting in delayed diagnosis and increased risk of recurrence or local invasion.[4]

Wide surgical excision with tumor-free margins remains the cornerstone of treatment, often combined with regional lymph node evaluation when clinically indicated.[5] We report a rare case of recurrent extraocular sebaceous carcinoma of the pinna with temporal extension managed with oncologic resection and staged reconstruction.

CASE REPORT

A 48-year-old female presented with a painless, progressively enlarging ulceroproliferative growth involving the left pinna and temporal region for five months. She had a history of excision of a left temporal lesion in 2019, which was histopathologically diagnosed as sebaceous carcinoma. No adjuvant radiotherapy or chemotherapy had been administered. There was no history of hearing loss, facial nerve dysfunction, dysphagia, weight loss, immunosuppression, prior radiotherapy, or family history suggestive of Muir–Torre syndrome.

On clinical examination, an irregular, nodular, exophytic ulceroproliferative mass involving the anterosuperior and posterosuperior helix of the left pinna with extension toward the temporal region was noted (Figure 1). The lesion was firm, non-tender, and fixed to underlying structures. The external auditory canal was uninvolved. Neck examination revealed a single firm left level II lymph node, clinically suspicious.



Figure 1: Clinical presentation of sebaceous carcinoma of the left pinna; (A) Clinical photograph showing ulceroproliferative growth involving the anterosuperior helix of the left pinna, (B) Extension of lesion toward the temporal region with nodular irregular surface, (C) Posterior view demonstrating involvement of posterosuperior helix, (D) Close-up view showing exophytic, irregular, firm lesion with surface ulceration.

Contrast-enhanced computed tomography of the neck revealed heterogeneously enhancing exophytic soft-tissue lesions arising from the anterosuperior and posterosuperior aspects of the left pinna with temporal extension. The lesions demonstrated broad-based attachment to the auricular cartilage without definite cartilage destruction. The external auditory canal, middle ear, mastoid air cells, skull base, and intracranial structures were uninvolved (Figure 2). Multiple subcentimetric to mildly enlarged cervical lymph nodes, most prominent at left level II, were noted and considered suspicious. Positron emission tomography–computed tomography demonstrated FDG-avid lesions involving the left pinna and temporal region, with low-grade FDG uptake in regional cervical lymph nodes, consistent with recurrent disease.

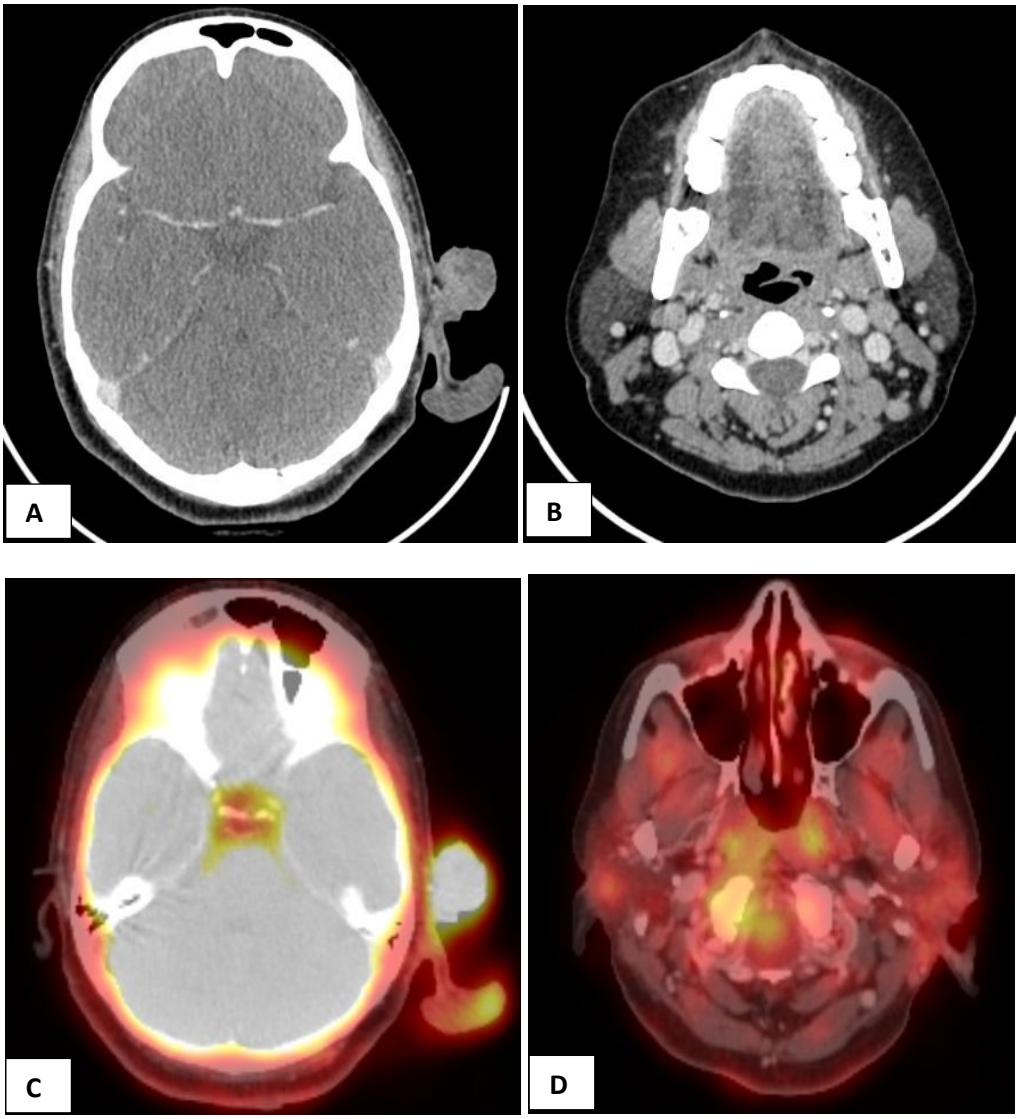

Figure 2: Radiological evaluation of tumor extent; (A) Contrast-enhanced CT scan showing heterogeneously enhancing soft tissue lesion arising from the left pinna, (B) Temporal extension of lesion with broad-based attachment to auricular cartilage without definite cartilage destruction, (C) PET-CT demonstrating FDG-avid lesion in left pinna and temporal region, (D) FDG uptake in regional cervical lymph nodes suggestive of nodal involvement.

The patient underwent wide excision of the left pinna along with the involved temporal and parotid regions, ensuring oncologically adequate margins. In view of suspected nodal disease, a left supraomohyoid neck dissection (levels I–III) was performed. The resultant composite defect was reconstructed in stages. Initial reconstruction was performed using a left anterolateral thigh free flap. Subsequent wound optimization was achieved using a left supraclavicular flap followed by split-thickness skin grafting (Figure 3).

Histopathological examination of the excised specimen confirmed sebaceous carcinoma. The temporal region showed poorly differentiated sebaceous carcinoma with focal squamous metaplasia, while the pinna demonstrated well-differentiated sebaceous carcinoma with mature sebocytes. All surgical margins were free of tumor. There was no lymphovascular or perineural invasion, and all dissected cervical lymph nodes were negative for metastatic disease. The final pathological stage was rmpT2N0 (Figure 4).

Immunohistochemistry revealed tumor cell positivity for androgen receptor, p63, and p40, supporting sebaceous differentiation. The MIB-1 proliferation index was increased in high-grade areas.

Mismatch repair protein analysis (MLH1, PMS2, MSH2, and MSH6) showed retained nuclear expression, consistent with an MMR-proficient tumor, with no evidence suggestive of Muir–Torre syndrome. The postoperative period was uneventful, and the patient remains under regular follow-up with no evidence of recurrence.

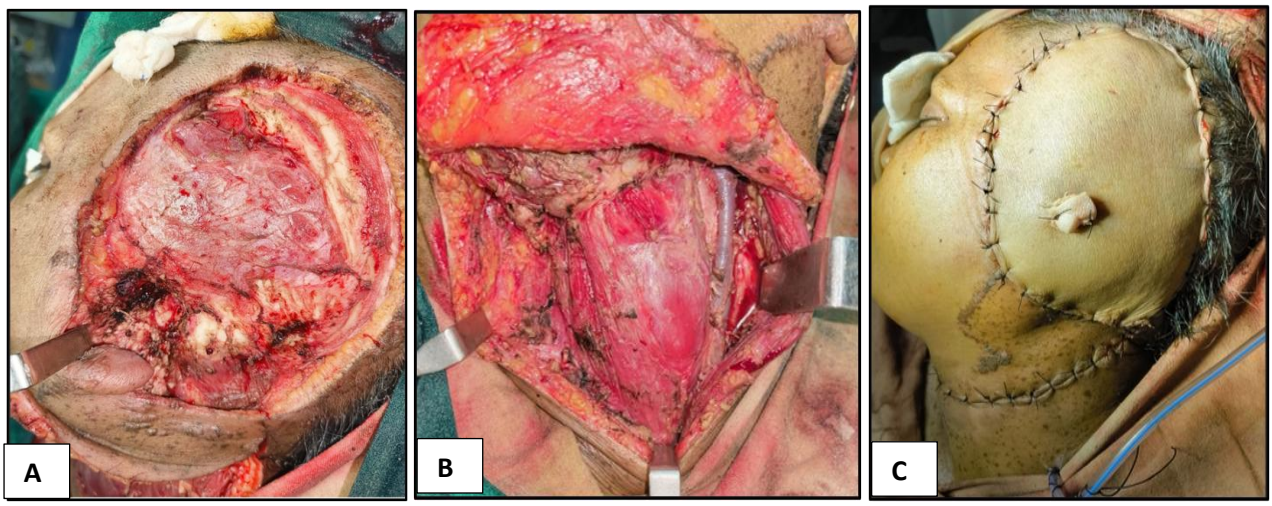

Figure 3: Surgical resection and reconstruction; (A) Intraoperative photograph following wide oncologic excision of left pinna and involved temporal tissue, (B) Reconstruction using left anterolateral thigh free flap, (C) Subsequent reconstruction with supraclavicular flap and split-thickness skin grafting.

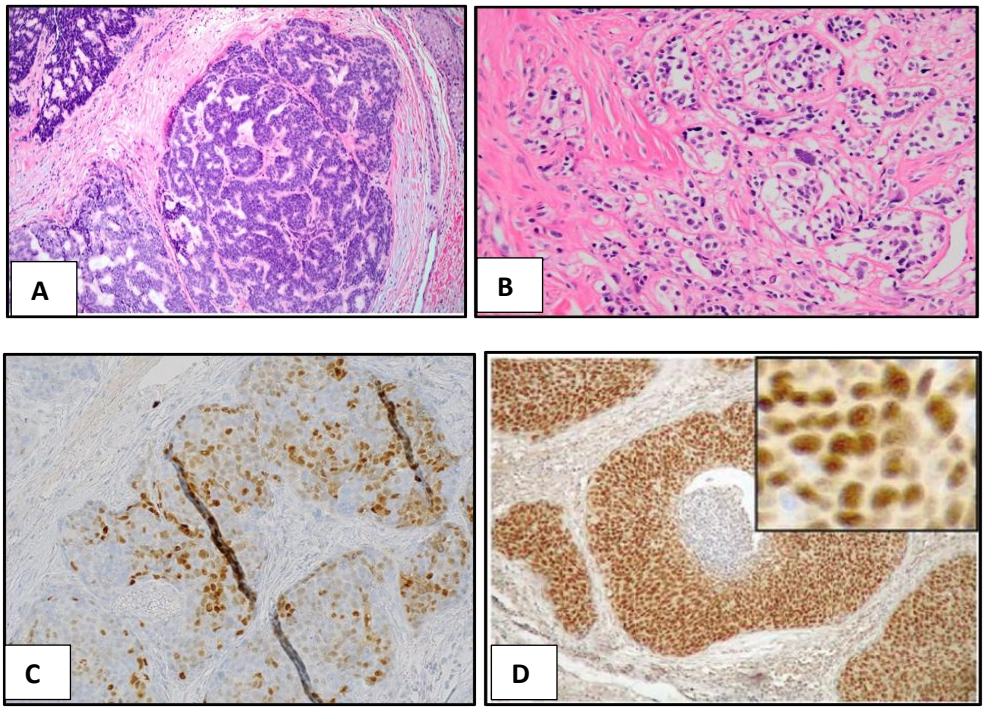

Figure 4: Histopathology and immunohistochemistry; (A) Low-power histological view showing tumor architecture consistent with sebaceous carcinoma, (B) High-power view demonstrating sebaceous differentiation with vacuolated cytoplasm, (C) Poorly differentiated component with focal squamous metaplasia, (D) Immunohistochemistry showing tumor cell positivity supporting sebaceous differentiation.

DISCUSSION

Extraocular sebaceous carcinoma of the pinna is exceptionally rare. The present case is notable for recurrence after previous excision, extension into the temporal region, and the need for extensive oncological resection followed by staged reconstruction. Extraocular sebaceous carcinomas may be locally aggressive and can be difficult to distinguish clinically and histologically from other cutaneous adnexal lesions. Previous reports and clinicopathological series have highlighted their varied presentation and potential for aggressive behaviour.[3,4]

Complete surgical excision with histologically clear margins is the principal treatment for localized

extraocular sebaceous carcinoma. Mohs micrographic surgery or another method of complete margin assessment may be considered when anatomically and technically feasible; wide local excision is appropriate for extensive lesions when margin-controlled techniques are not practical.[5] In the present case, the recurrent tumor involved the pinna and adjacent temporal and parotid regions, requiring extensive oncological resection. A left supraomohyoid neck dissection was performed because of clinical and radiological suspicion of regional nodal disease; however, histopathological examination showed no cervical lymph node metastasis.

Sebaceous neoplasms may be associated with Muir–Torre syndrome, a phenotypic variant of Lynch syndrome. The patient had no reported personal or family history suggestive of the syndrome. Immunohistochemistry showed retained nuclear expression of MLH1, PMS2, MSH2 and MSH6, indicating preserved mismatch-repair protein expression in the sampled tumor. This finding does not demonstrate mismatch-repair deficiency; however, retained expression on immunohistochemistry should not be interpreted as an absolute exclusion of an underlying hereditary syndrome when clinical suspicion remains. The association between sebaceous tumors and Muir–Torre syndrome, and the role of mismatch-repair assessment, have been discussed by Ponti and Ponz de Leon.[6]

Imaging was important for mapping the extent of disease and planning resection. Contrast-enhanced CT demonstrated the relationship of the lesion to the auricular cartilage and excluded definite cartilage destruction or deeper temporal bone involvement. PET-CT showed FDG-avid primary lesions and low-grade uptake in regional cervical nodes. These findings, together with the clinically suspicious level II node, informed the decision to perform regional neck dissection. Imaging findings alone cannot establish nodal metastasis; in this case, histopathological examination of the dissected nodes showed no metastatic disease. Reviews of sebaceous carcinoma support assessment of local extent and suspicious regional nodes in selected patients with advanced or recurrent disease.[7]

Histopathological examination demonstrated two components: a poorly differentiated sebaceous carcinoma with focal squamous metaplasia in the temporal region and a well-differentiated component with mature sebocytes in the pinna. All resection margins were free of tumor and lymphovascular and perineural invasion were absent. The increased MIB-1 proliferation index in the high-grade areas was consistent with the more poorly differentiated component. Immunohistochemical positivity for androgen receptor, p63 and p40 supported the diagnosis in the appropriate morphological context. The distinction between sebaceous carcinoma and other cutaneous adnexal tumors may be challenging because of overlapping histological appearances, as highlighted in the literature on extraocular sebaceous carcinoma.[8]

Sebaceous carcinoma arising in the external auditory canal has also been reported, emphasizing the rarity of sebaceous malignancies in the otologic region and the importance of defining local spread before selecting the surgical approach.[9] Although the anatomical site differs from the pinna, this report provides relevant context for tumors arising in the peri-auricular region. In the present patient, the external auditory canal, middle ear, mastoid, skull base and intracranial structures were spared on imaging.

The resulting composite defect required staged reconstruction. An anterolateral thigh free flap was initially used to cover the extensive defect, followed by wound optimization with a supraclavicular flap and split-thickness skin grafting. This illustrates the reconstructive complexity that may follow oncologically adequate resection of recurrent tumors in the auriculotemporal region. The reconstructive plan must be individualized according to defect size, tissue availability, vascular status and the need for postoperative surveillance.

The patient remains under regular follow-up with no evidence of recurrence at the time of reporting. Given the history of recurrence and the locally extensive presentation, prolonged surveillance is warranted. Follow-up should include examination of the operative site, remaining skin, and regional lymph-node basins, with imaging guided by clinical findings.

CONCLUSION

Extraocular sebaceous carcinoma of the pinna is rare and may recur with extensive local invasion. This case highlights the importance of histopathological confirmation, appropriate imaging to define disease extent, and complete surgical excision with clear margins. When extensive resection is required, individualized staged reconstruction can help address the resulting complex defect. Long-term clinical surveillance is essential, particularly in patients presenting with recurrent disease.

ACKNOWLEDGEMENTS

The authors acknowledge the Departments of Pathology and Radiology for diagnostic and imaging support.

Funding: No funding sources
Conflict of interest: None declared
Ethical approval: Not required

REFERENCES

1. Cribier B, Scrivener Y, Grosshans E. Tumors arising in nevus sebaceus: a study of 596 cases. J Am Acad Dermatol. 2000;42(2 Pt 1):263-8.
2. Mehregan AH, Pinkus H. Life history of organoid nevi: special reference to nevus sebaceus of Jadassohn. Arch Dermatol. 1965;91(6):574-88.

3. Torres JS, Amorim AC, Hercules FM, Kac BK. Giant extraocular sebaceous carcinoma: case report and a brief review of a literature. Dermatol Online J. 2012;18(11):7.
4. Domingo J, Helwig EB. Malignant neoplasms associated with nevus sebaceus of Jadassohn. J Am Acad Dermatol. 1979;1(6):545-56.
5. Snow SN, Larson PO, Lucarelli MJ, Lemke BN, Madjar DD. Sebaceous carcinoma of the eyelids treated by Mohs micrographic surgery: report of nine cases with review of the literature. Dermatol Surg. 2002;28(7):623-31.
6. Ponti G, Ponz de Leon M. Muir-Torre syndrome. Lancet Oncol. 2005;6(12):980-7.
7. Shields JA, Demirci H, Marr BP, Eagle RC Jr, Shields CL. Sebaceous carcinoma of the ocular region: a review. Surv Ophthalmol. 2005;50(2):103-22.
8. Wick MR, Goellner JR, Wolfe JT 3rd, Su WP. Adnexal carcinomas of the skin. II. Extraocular sebaceous carcinomas. Cancer. 1985;56(5):1163-72.
9. Saadi R, Pennock M, Baker A, Isildak H. A case of external auditory canal sebaceous carcinoma: literature review and treatment discussion. Biomed Hub. 2020;5(2):72-8.

Cite this article as: Mishra G, Amin D, Vadaviya R, Ramani A. Recurrent extraocular sebaceous carcinoma of the pinna with temporal extension: a rare case report. Int J Otorhinolaryngol Head Neck Surg 2026;12:1041-6.