International Journal of Otorhinolaryngology and Head and Neck Surgery
Mantri G et al. Int J Otorhinolaryngol Head Neck Surg. 2026 Dec;12(6):1037-1040
https://www.ijorl.com
pISSN 2454-5929 | eISSN 2454-5937
DOI: https://dx.doi.org/10.18203/issn.2454-5929.ijohns20264289

Case Report

A rare case of cervical sympathetic chain ganglioneuroma in a 3-year-old child: a case report

Gaveshani Mantri, D. N. S. Prakash, Chetana Pradhan

Department of ENT and Head and Neck Surgery, IMS and SUM Hospital Campus 2, Phulnakhara, Bhubaneswar, Odisha, India

Received: 23 August 2026
Revised: 12 October 2026
Accepted: 17 October 2026

***Correspondence:**
Dr Gaveshani Mantri,
E-mail: gaveshani_gr8@yahoo.com

Copyright: © the author(s), publisher and licensee Medip Academy. This is an open-access article distributed under the terms of the Creative Commons Attribution Non-Commercial License, which permits unrestricted non-commercial use, distribution, and reproduction in any medium, provided the original work is properly cited.

ABSTRACT

This article deals with a rare occurrence of ganglioneuroma of the left cervical sympathetic chain in a 3-year-old girl, presenting with a painless, progressive neck swelling noticed since 1 year of age. Imaging studies showed a left carotid space mass displacing the contents of the carotid sheath antero-laterally, with no significant vascular feeders. A provisional diagnosis of nerve sheath tumour was established, and the patient underwent surgical excision.

Keywords: Cervical ganglioneuroma, Paediatric neck tumors, Benign cervical masses, Neck swelling, Neurogenic tumor

INTRODUCTION

Ganglioneuromas, Neuroblastomas and Ganglioneuroblastomas constitute a group of neurogenic tumors that are classified mainly by their potential for differentiation and malignancy. Ganglioneuromas represent the benign and well-differentiated form of a neurogenic tumor.[1,2] Neuroblastomas are malignant, undifferentiated and aggressive while ganglioneuroblastomas tend to be more intermediate in nature.

Ganglioneuromas (GN) are rare, benign neoplasms of neuroblastic origin that arise from the autonomic nervous system.[3] Their occurence is estimated at approximately one in 10,00,000 individuals, making them a rare clinical entity. Ganglioneuromas are most frequently found in the posterior mediastinum and retroperitoneum cervical region, being very uncommon location. These tumors occur more frequently in the pediatric population and young adults, with approximately 60% of cases diagnosed in patients under 20 years of age, with a slight female predominance.[4] The signs and symptoms of cervical ganglioneuromas are usually related to the mass effect and nerve dysfunction, these tumors most often present as neck swelling with no specific symptomatology, as in the present case.

We are reporting a case of cervical ganglioneuroma in a 3-year-old female child which is probably the youngest case reported in literature. This case highlights the importance of a thorough examination and differential diagnosis of neck masses, emphasizing the need to consider ganglioneuroma as a potential cause of cervical masses specially in pediatric age group.

CASE REPORT

A 3-year-old female child presented with a swelling in left lateral part of neck which was noticed at around 1 year of age, it was slowly progressive, not associated with pain or difficulty in swallowing, change in voice, fever or any other constitutional symptoms. The child was evaluated for Tubercular lymphadenitis which came out to be negative. On clinical examination the child was afebrile, active without any associated co-morbid conditions, the swelling was around 6x5 cm in size,

smooth, firm, non-tender, non-reducible, not transilluminating, mobile in horizontal axis with limited mobility in vertical axis, non-pulsatile with anterolateral displacement of carotid (Figure-1). The skin over the swelling was pinchable and normal. Intra-oral examination was normal. The Vagus and Hypoglossal nerve were intact, uvula in midline, no ptosis or miosis was found. Preliminary blood and urine investigations with hormonal assay were normal. CECT scan of neck showed (Figure-2) a well-defined round to oval heterogenous enhancing lesion of size 55x42x65mm noted in the left carotid space of the neck with few internal punctate calcifications. The lesion is medially abutting the thyroid gland, esophagus and thyroid cartilage with maintained fat plane and displacing the ICA, ECA and IJV antero-laterally without splaying. There were maintained fat planes with adjacent structures. The lesion was extending into left parapharyngeal space medially and pre vertebral space posteriorly and left SCM anterolaterally. Fine needle aspiration cytology was suggestive of ganglioneuroma. The patient was planned for excision of the tumor under general anesthesia. The patient was positioned in prevertebral extension of neck and head turned to right side, cleaned and draped with strict aseptic precautions, a transcervical incision was planned 2cm below angle of mandible on the left side to prevent injury to marginal mandibular nerve and marked, 2% Lignocaine with 1 in 1,00,000 Adrenaline was infiltrated, Incision was made with no 22 surgical blade and subplatysmal flaps elevated superiorly and inferiorly, SCM was identified and anterior border dissected and carotid space was accessed and the tumor bulge was identified. The internal jugular vein and the common carotid artery which were displaced anterolaterally by the tumor were gently retracted away from the field.



Figure 1: The extension of the cervical swelling as seen clinically.

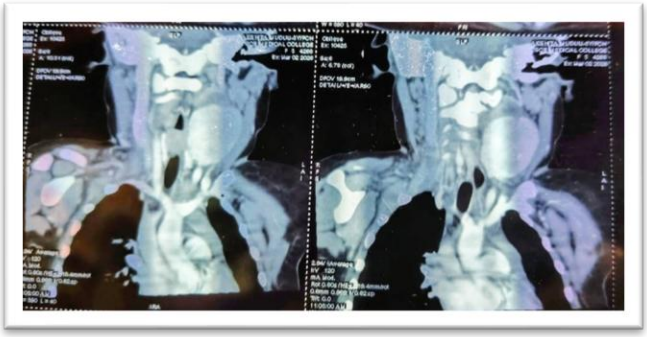

Figure 2: CECT neck showed the mass displacing the ECA, ICA and IJV anterolaterally without splaying

The tumor was delineated and was found to be originating in the carotid space from cervical sympathetic chain which ramified into the mass (Figure-3). The lesion was well circumscribed, making an intact removal possible but the nerve was sacrificed (Figure-4).

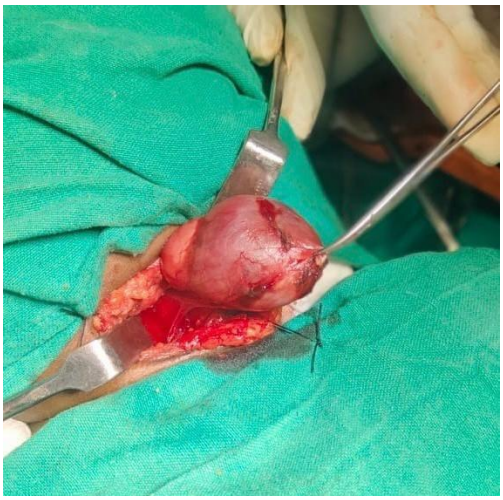

Figure 3: Introperative picture of the tumour involving the nerve (sympathetic chain).



Figure 4: Mass removed in toto.

Haemostasis was confirmed, negative suction drain was placed, and wound was closed in 2 layers with 3-0 vicryl and 3-0 Monocryl for subcuticular skin closure. Post - operative period was uneventful, however mild ptosis was noted on the left side. Post operative management during hospital stay included IV antibiotics, analgesics and other supportive treatments. The drain was removed on postoperative day 2. The patient was discharged on the post-operative day 3 with oral antibiotics anpost-operative. Follow up 10 days the wound was well healed, the child was active and was on oral solid diet, no pain or difficulty in swallowing was noted. Histopathological examination confirmed the diagnosis of ganglioneuroma (Figure-5). The patient is under follow up and at 12 months there are no signs of recurrence. Written informed consent was obtained for this case report from the parents of the patient.

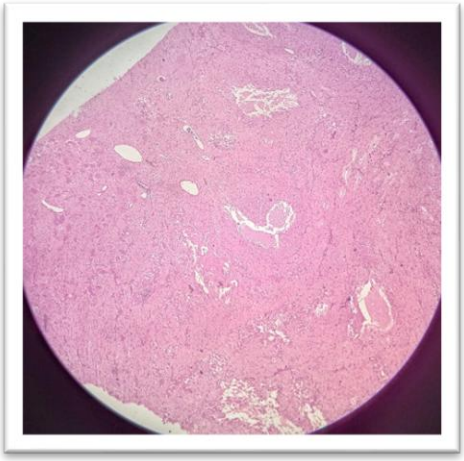

Figure 5: Admixture of Schwann cells and ganglion cells with predominance of Schwannian stroma (4X * 10X).

DISCUSSION

GN is a relatively rare benign neurogenic tumor that originates from primitive neural crest cells, and is mainly composed of well-differentiated Schwann cells, ganglion cells, nerve fibers, and mucinous matrix.[5] It is most frequently located in the abdomen (posterior mediastinum, retroperitoneum, and adrenal glands) in 65%-80% of cases, followed by the thorax in 10%-15%, with the neck region as its rarest location seen in 5%-8% of patients.[6,7] The reviewed literature suggests the possibility of these tumors being secretory; however, our case and the ones reviewed were not metabolically active.[7-10] Nevertheless, the differential diagnosis between ganglioneuroma and neuroendocrine tumors can be quite difficult. According to the North American Neuroendocrine Tumor Society guidelines, the initial testing for pheochromocytoma or paraganglioma must include measurements of fractionated metanephrines in plasma, urine, or both, as available. Given their high sensitivity for neuroendocrine tumors (reaching 100% in children and 99% in adults), they are part of the initial routine evaluation of this kind of masses.[11] CT imaging usually shows a well-circumscribed, encapsulated mass, with calcifications present in nearly half of the cases. While imaging can aid in narrowing the differential diagnosis, it is not sufficient to distinguish ganglioneuroma from neuroblastoma or ganglioneuroblastoma definitively. Nonetheless, ganglioneuromas tend to appear more homogeneous on imaging.[12] The gross appearance of a GN is a well encapsulated tumour which appears mucinous on sectioning. Microscopic examination reveals mature ganglion cells, and a cytological architecture consistent with mature ganglion cells with a lack of structural organization. Malignant potential is usually associated with the presence of undifferentiated components; in contrast, ganglioneuromas are composed entirely of mature ganglion cells and Schwannian stroma, reflecting their benign nature. As in our case, ganglioneuromas represent the most differentiated form, consisting of mature ganglion cells distributed in a predominant Schwannian stroma suggesting purely of benign nature. The prognosis is favorable, as ganglioneuromas do not have metastatic potential. As these tumors are slow growing with so far no recorded metastatic potential, complete excision being suffice to bring about a cure. The site, size and pathological type determine the choice of surgical approach.[13] If the diagnosis is confirmed after surgical excision, it can be curative. Even in the case of incomplete resection, it does not have the potential to recur.[14] Radiation should be avoided in these cases, especially in young ages, as it can cause growth retardation and radiation related problems later. On the other hand, other categories of neurogenic tumor have different behaviors. Neuroblastoma is a malignant solid tumor and ganglioneuroblastoma has moderate malignant potential, which may require the need for close follow-up and for adjuvant treatment, such as chemo- and/or radiotherapy.

CONCLUSION

A neck swelling can have varied differentials like infectious cervical lymphadenopathy, branchial cleft cyst, thyroglossal duct cyst and malignancies such as other forms of neuroplastic tumours, NHL etc. However, the possibility of a ganglioneuroma must be taken into consideration even if it is rare. Surgical excision is the only definite treatment of cervical ganglioneuroma, therefore early diagnosis and excision is imperative as extension superiorly to skull base complicates surgical access. Proper preoperative imaging and surgical planning will minimise morbidity and complications. This case contributes to the literature on cervical ganglioneuromas and reinforces the importance of maintaining a broad differential while evaluating neck masses in children and adolescents.

Funding: No funding sources
Conflict of interest: None declared
Ethical approval: Not required

REFERENCES

1. Folpe AL, Goldblum JR, Weiss S. Enzinger and Weiss's Soft Tissue Tumors. 6th ed. Saunders; 2014.
2. Goldblum JR, Rosai J, Lamps LW, McKenney J, Myers JL. Rosai and Ackerman's Surgical Pathology. 10th ed. Elsevier; 2017.
3. Xu T, Zhu W, Wang P. Cervical ganglioneuroma: a case report and review of the literature. Medicine (Baltimore). 2019;98:e15203.
4. Stout AP. Ganglioneuroma of the sympathetic nervous system. Surg Gynecol Obstet. 1947;84:101-10.
5. Louis DN, Perry A, Wesseling P, Brat DJ, Cree IA. The 2021 WHO classification of tumors of the central nervous system: a summary. Neuro Oncol. 2021;23:1231-1251.
6. Califano L, Zupi A, Mangone FM, Long F. Cervical ganglioneuroma: report of a case. Otolaryngol Head Neck Surg. 2001;124:115-6.
7. Dutta H. Cervical ganglioneuroma in a child. SM J Pediatr Surg. 2016;2:1013.
8. Kaufman MR, Rhee JS, Fliegelman LJ, Costantino PD. Ganglioneuroma of the parapharyngeal space in a pediatric patient. Otolaryngol Head Neck Surg. 2001;124:702-4.
9. Gopal A, Singh S, Sridhar M, Khurana N. Cervical sympathetic chain ganglioneuroma: case report and review of literature. IOSR J Pharm. 2015;5:8-11.
10. Cannady SB, Chung BJ, Hirose K, Garabedian N, Van Den Abbeele T, Kontai PJ. Surgical management of cervical ganglioneuromas in children. Int J Pediatr Otorhinolaryngol. 2006;70:287-94.
11. Chen H, Sippel RS, O'Dorisio MS, Vinik AI, Lloyd RV, Pacak K, et al. The North American Neuroendocrine Tumor Society consensus guideline for the diagnosis and management of neuroendocrine tumors: pheochromocytoma, paraganglioma, and medullary thyroid cancer. Pancreas. 2010;39:775-783.
12. Pacella G, Brunese MC, Donnarumma F, Barrassi M, Bellifemine F, Sciaudone G, et al. Imaging of ganglioneuroma: a literature review and a rare case of cystic presentation in an adolescent girl. Diagnostics (Basel). 2023;13(13):2190.
13. Allison RS, Van der Waal I, Snow GB. Parapharyngeal tumours: a review of 23 cases. Clin Otolaryngol Allied Sci. 1989;14:199-203.
14. Lloyd R, Osamura R, Klöppel G, Rosai J, Bosman F, Jaffe E, et al. WHO Classification of Tumours of Endocrine Organs. 4th ed. Vol. 10. Available from: https://publications.iarc.who.int/Book-And-Report-Series/Who-Classification-Of-Tumours/WHO-Classification-Of-Tumours-Of-Endocrine-Organs-2017. Accessed on 20 July 2026.

Cite this article as: Mantri G, Prakash DNS, Pradhan C. A rare case of cervical sympathetic chain ganglioneuroma in a 3-year-old child: a case report. Int J Otorhinolaryngol Head Neck Surg 2026;12:1037-40.