International Journal of Otorhinolaryngology and Head and Neck Surgery
Shaikh A et al. Int J Otorhinolaryngol Head Neck Surg. 2026 Dec;12(6):924-931
https://www.ijorl.com
pISSN 2454-5929 | eISSN 2454-5937
DOI: https://dx.doi.org/10.18203/issn.2454-5929.ijohns20264273

Original Research Article

Evaluation of status of Eustachian tube by saccharine test and high-resolution computed tomography of the temporal bone in bilateral inactive mucosal chronic otitis media

Ayesha Shaikh[1]*, Vidya Rokade[2], Divya Sawant[3], Saba Javed Alam[4]

[1]Department of ENT ESIC Model Hospital, Basaidarapur New Delhi, India
[2]Department of ENT, Smt Kashibai Navale Medical College Pune, Maharashtra India
[3]Department of ENT, Aundh District Hospital Pune, Maharashtra India
[4]Department of radiology, Cooper hospital and Medical College Mumbai, Maharashtra India

Received: 21 August 2026
Revised: 01 October 2026
Accepted: 08 October 2026

***Correspondence:**
Dr. Ayesha Shaikh,
E-mail: absayesha@gmail.com

Copyright: © the author(s), publisher and licensee Medip Academy. This is an open-access article distributed under the terms of the Creative Commons Attribution Non-Commercial License, which permits unrestricted non-commercial use, distribution, and reproduction in any medium, provided the original work is properly cited.

ABSTRACT

Background: Chronic otitis media (COM) is a chronic inflammatory disease of the middle ear and mastoid cavity. Eustachian tube dysfunction is considered an important etiological factor, particularly in bilateral inactive mucosal chronic suppurative otitis media (CSOM). This study aimed to evaluate Eustachian tube patency using the saccharine test and assess its anatomical characteristics using high-resolution computed tomography (HRCT) of the temporal bone.

Methods: A prospective observational study was conducted on 50 patients with bilateral inactive mucosal CSOM between 2022 and 2024 in the Department of Otorhinolaryngology at Smt. Kashibai Navale Medical College and Hospital. Eustachian tube function was assessed using the saccharine clearance test, while anatomical parameters were evaluated using HRCT of the temporal bones.

Results: The study included 50 patients with bilateral inactive mucosal CSOM, with a mean age of 35.3 years and female predominance (58%). The saccharine test demonstrated longer Eustachian tube clearance time in the left ear compared with the right; however, the difference was not statistically significant. HRCT revealed considerable variation in Eustachian tube anatomical parameters. Significant associations were observed between saccharine clearance time and right pre-tympanic diameter, as well as between reduced Eustachian tube angle and delayed clearance in the left ear.

Conclusion: Eustachian tube function in bilateral inactive mucosal CSOM appears to be multifactorial. Although certain anatomical parameters showed significant associations with functional impairment, HRCT findings alone may not reliably predict Eustachian tube dysfunction in chronic otitis media in patients with bilateral mucosal disease.

Key word: CSOM, Eustachian tube, Saccharine test, HRCT

INTRODUCTION

Chronic otitis media (COM) is a chronic inflammatory disease of the middle ear cleft and mastoid air cell system, commonly associated with tympanic membrane perforation, persistent otorrhea, and hearing impairment.[1] Mucosal COM (tubotympanic disease) primarily involves the Eustachian tube (ET) and tympanic cavity, with bilateral inactive mucosal COM representing a quiescent

stage characterized by persistent mucosal changes without active infection.

Eustachian tube dysfunction plays a central role in the pathogenesis of COM by impairing middle ear ventilation, pressure regulation, and mucociliary clearance. The ET is a complex dynamic structure, and its functional impairment is influenced by both anatomical and physiological factors.[2] The saccharine test provides a simple assessment of ET mucociliary function; however, it does not define underlying anatomical abnormalities.[3]

High-resolution computed tomography (HRCT) of the temporal bone with multiplanar reconstruction allows detailed evaluation of ET anatomy and related temporal bone structures.[4] Parameters such as Eustachian tube angle, pre-tympanic diameter, and tubotympanic angle have been studied as potential anatomical indicators of ET dysfunction.

This study aims to correlate functional assessment of ET using the saccharine test with anatomical parameters obtained from HRCT temporal bone in patients with bilateral inactive mucosal COM, to better understand the relationship between ET anatomy and function in chronic middle ear disease.

METHODS

Study Design and Setting

This prospective observational study was conducted in the Department of Otorhinolaryngology at Smt Kashibai Navale Medical college, a tertiary care teaching hospital, over a period of 18 months from September 2022 to February 2024.The study was approved by the Institutional Ethics Committee, written informed consent was obtained from all participants before enrolment.

Study population

A total of 50 patients (100 ears) diagnosed with bilateral inactive mucosal chronic otitis media (COM) and meeting the eligibility criteria were included in the study. Sample size calculated using formulas

$N= z^2 pq/d^2$

Inclusion criteria

Patients aged 18–60 years with bilateral inactive mucosal chronic otitis media and central tympanic membrane perforation, a dry ear for at least 6 weeks before evaluation, and willingness to provide written informed consent.

Exclusion criteria

The study excluded patients with active ear discharge, unilateral chronic otitis media, acute ear infection, squamosal chronic otitis media, or unwillingness to participate in the study.

Clinical evaluation

A detailed history regarding ear discharge, hearing loss, duration of symptoms, and associated nasal complaints was obtained. All patients underwent complete otorhinolaryngological examination, including otoscopic and microscopic examination of both ears.

Saccharine test for eustachian tube mucociliary clearance[3]

The saccharine test was performed under aseptic conditions with the patient in the sitting position. A sterile saccharine particle (approximately 1 mm in diameter) was placed at the pharyngeal opening of the Eustachian tube through the nasal cavity under endoscopic guidance. Patients were instructed to avoid swallowing, sneezing, eating, or drinking during the procedure and were asked to report the first perception of a sweet taste. The time interval between saccharine placement and perception of sweetness was recorded in minutes and considered the mucociliary clearance time. The results were categorized as:Normal: <20 minutes, Mild dysfunction: 20–45 minutes, Severe dysfunction: >45 minutes. Both ears were evaluated separately

High-Resolution Computed Tomography (HRCT) Temporal Bone

All participants underwent HRCT temporal bone using a multidetector CT scanner with 1 mm slice thickness in axial and coronal planes. Images were reconstructed using a high-resolution bone algorithm. The following parameters were assessed for eustachian tube anatomy: Pretympanic diameter (figure 1), Eustachian tube angle (Figure 2) and Tubotympanic angle (Figure 3). HRCT images were interpreted independently by an experienced radiologist who was blinded to the saccharine test results.

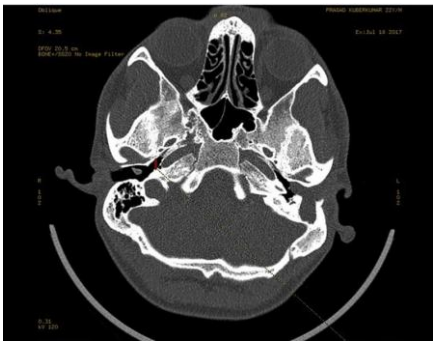

Figure 1: HRCT temporal bone showing measurement of pretympanic diameter.

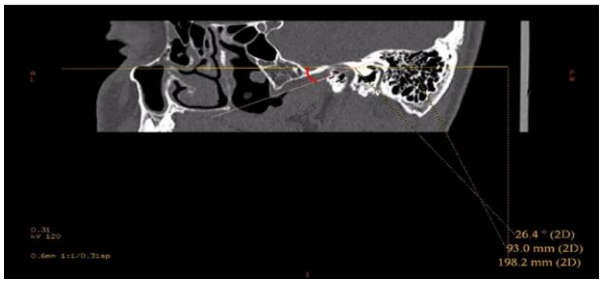

Figure 2: HRCT of temporal bone showing measurement of eustachian tube angle.

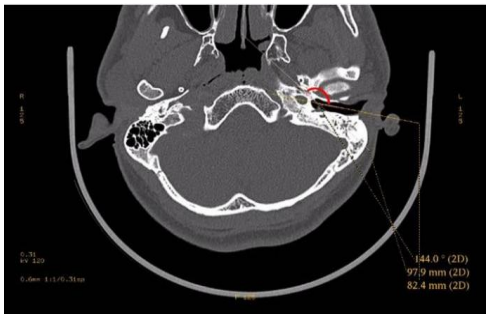

Figure 3: HRCT showing measurement of tubotympanic angle.

Outcome Measures

The primary outcome was assessment of Eustachian tube mucociliary clearance using the saccharine test. Secondary outcomes included evaluation of HRCT temporal bone findings (eustachian tube anatomy) and determination of the association between saccharine test results and radiological findings.

Statistical Analysis

Data were entered into Microsoft Excel and analyzed using IBM SPSS Statistics version [26.0]. Continuous variables were expressed as mean±standard deviation (SD), while categorical variables were presented as frequency and percentage. The association between categorical variables was analyzed using the Chi-square test or ANOVA test, as appropriate. Qualitative variables were expressed as percentages, reflecting the proportion of participants falling into each category. Statistical significance was determined by a p-value less than 0.05, indicating that any observed differences or associations were unlikely to have occurred by random chance alone. This threshold guided the interpretation of results, with values below it considered statistically significant.

RESULT

Table 1 shows among the 50 study participants, the highest proportion belonged to the 31–40 years age group (30%), followed by those aged 18–20 years (24%), 51–60 years (18%), and 21–30 and 41–50 years (14% each), indicating a broad age distribution within the study population.

Table 1 shows the sex profile of the 50 participants. Among them, 29 (58%) are female,and 21 (42%) are male.

Table 1. Demographic and perforation profile of study participants (n=50).

Variables	Category	Frequency (N)	Percentage (%)	Right ear N (%)	Left ear N (%)
Age (years)	18–20	12	24.0	—	—
	21–30	7	14.0	—	—
	31–40	15	30.0	—	—
	41–50	7	14.0	—	—
	51–60	9	18.0	—	—
Sex	Female	29	58.0	—	—
	Male	21	42.0	—	—
Perforation size	Large CP	—	—	27 (54.0)	22 (44.0)
	Moderate CP	—	—	20 (40.0)	22 (44.0)
	Small CP	—	—	3 (6.0)	6 (12.0)

Tables 1 summarizes the distribution of tympanic membrane perforation sizes in the right and left ears. In the right ear, large central perforations were most common (54%), followed by moderate (40%) and small central perforations (6%). In the left ear, large and moderate central perforations were equally prevalent (44% each), while small central perforations accounted for 12% of cases.

Tables 2 summarizes the saccharine test results for mucociliary clearance in the right and left ears. In the right ear, 84% of participants had a saccharine clearance time of <20 minutes, while 16% had a clearance time of 20–45 minutes (mean: 13.05±7.11 minutes; range: 2.5–35.0 minutes). In the left ear, 70% had a clrance time of <20 minutes and 30% had a clearance time of 20–45 minutes (mean: 16.45±8.39 minutes; range: 3.0–41.0

minutes). No participant demonstrated a saccharine clearance time exceeding 45 minutes in either ear.

Table 2. Saccharine test results in right and left ears

Saccharine test	Right ear N (%)	Left ear N (%)
<20 min	42 (84.0)	35 (70.0)
20–45 min	8 (16.0)	15 (30.0)
>45 min	0 (0.0)	0 (0.0)
Total	50 (100.0)	50 (100.0)

Comparison of the saccharine test results between the right and left ears showed no statistically significant difference (p>0.05). However, the left ear demonstrated relatively poorer Eustachian tube function, as reflected by longer saccharine clearance times, although this difference did not reach statistical significance.

HRCT temporal bone finding

Eustachian tube parameter

Pretympanic diameter

Pretympanic is funnel shaped portion of eustachian tube adjacent to tympanic orifice, on the axial view, it is easy to find lumen of pre tympanic segment.

Tables 3 present the pre-tympanic diameter measurements for the right and left ears. The mean pre-tympanic diameter was 4.91±0.69 mm (range: 3.51–5.99 mm) in the right ear and 4.53±0.87 mm (range: 3.00–5.90 mm) in the left ear.

The mean difference between the pretympanic diameter between the right ear and left ear was -0.38, indicating that, on an average, the right pretympanic diameter is slightly larger than the left However this difference is statistical significance (p value<0.05).

Table 3. HRCT temporal bone measurements in right and left ears.

HRCT parameter	Right ear Mean±SD (Range)	Left ear Mean±SD (Range)
Pre-tympanic diameter	4.91±0.69 (3.51–5.99)	4.53±0.87 (3.00–5.90)
Eustachian tube angle	26.48±3.15 (20.00–31.00)	26.75±3.75 (19.00–32.73)
Tubotympanic angle	140.15±5.93 (129.96–160.00)	137.87±7.54 (124.74–153.00)

Eustachian tube angle

The Eustachian tube angle, defined as the inclination of the tube relative to the horizontal (Reid) plane, was measured using high-resolution computed tomography (HRCT) of the temporal bone with multiplanar reconstruction. Images were acquired with a 1-mm slice thickness. The Reid plane, passing through the bilateral inferior orbital walls and the superior walls of the external auditory canals, served as the reference. The Eustachian tube axis was identified by connecting the tympanic and pharyngeal orifices on reconstructed coronal images, and the angle was measured between this axis and the Reid plane.

Tables 3 present the Eustachian tube angle measurements for the right and left ears. The mean Eustachian tube angle was 26.48±3.15° (range: 20.00–31.00°) in the right ear and 26.75±3.75° (range: 19.00–32.73°) in the left ear.

The mean difference in Eustachian tube angle between the right and left ears was−0.27°, indicating a slightly more acute angle in the left ear. However, this difference was not statistically significant (p > 0.05).

The tubo-tympanic angle

The tubo-tympanic angle, defined as the angle between the Eustachian tube axis and the longitudinal axis of the external auditory canal extending to the tympanic membrane, was measured on HRCT temporal bone images. It was determined as the angle between a line passing through the tympanic orifice of the Eustachian tube and the longitudinal axis drawn from the bony external auditory canal within the tympanic cavity.

Tables 3 present the tubo-tympanic angle measurements for the right and left ears. The mean tubo-tympanic angle was 140.15±5.93° (range: 129.96–160.00°) in the right ear and 137.87±7.54° (range: 124.74–153.00°) in the left ear.

Difference of means in the tubotympanic angle in the right and left ear

The mean difference in tubo-tympanic angle between the right and left ears was 2.28°, indicating a slightly larger angle on the right side. However, this difference was not statistically significant (p>0.05).

Tables 4 demonstrate the association between saccharine clearance time and tympanic membrane perforation size in the right and left ears. In the right ear, most participants across all perforation sizes showed saccharine clearance times of<20 minutes. No significant association was observed between perforation size and saccharine clearance time (χ^2=0.71, p=0.70). In the left ear, delayed clearance (20–45 minutes) was relatively more frequent among participants with small central perforations; however, the association remained statistically insignificant (χ^2=4.47, p=0.107).

Table 4: Association between saccharine test and perforation size.

Ear	Saccharine test	Large CP N (%)	Moderate CP N (%)	Small CP N (%)	P value
Right	<20 min	22 (81.5)	17 (85.0)	3 (100.0)	0.70
	20–45 min	5 (18.5)	3 (15.0)	0 (0.0)	
Left	<20 min	16 (72.7)	17 (77.3)	2 (33.3)	0.107
	20–45 min	6 (27.3)	5 (22.7)	4 (66.7)	

Tables 5 present the association between saccharine clearance time and HRCT-based Eustachian tube parameters in the right and left ears. In the right ear, participants with delayed saccharine clearance (20–45 minutes) showed a significantly higher mean pre-tympanic diameter compared with those with clearance time <20 minutes (5.35 mm vs. 4.83 mm, p=0.047). However, no significant association was observed with Eustachian tube angle (p=0.38) or tubo-tympanic angle (p=0.379).

Table 5: Association between saccharine test and individual HRCT Eustachian tube parameters

Ear	Parameter	<20 min Mean±SD	20–45 min Mean±SD	P value
Right	Pre-tympanic diameter	4.827±0.680	5.350±0.594	0.047 significant
	Eustachian tube angle	26.310±3.197	27.375±2.925	0.380
	Tubotympanic angle	139.822±5.567	141.849±7.786	0.379
Left	Pre-tympanic diameter	4.520±0.869	4.561±0.901	0.880
	Eustachian tube angle	27.462±3.885	25.073±2.870	0.037 significant
	Tubotympanic angle	137.259±5.876	139.283±10.595	0.390

Table 6: Association of saccharine test, perforation size and HRCT parameters in the right ear.

Saccharine test	HRCT parameter	Large CP	Moderate CP	Small CP	P value (ANOVA)
<20 min	Pre-tympanic diameter	4.557±0.853	4.645±0.851	5.287±0.531	0.300
	Eustachian tube angle	26.41±3.46	26.80±3.03	24.67±2.89	0.590
	Tubotympanic angle	129.53±5.78	131.88±5.83	124.67±4.89	0.650
20–45 min	Pre-tympanic diameter	4.058±1.088	3.750±0.000	—	0.650
	Eustachian tube angle	25.80±2.59	30.00±0.00	—	0.030
	Tubotympanic angle	126.43±5.01	132.73±0.00	—	0.0019

Table 7: Association of saccharine test, perforation size and HRCT parameters in the left ear.

Saccharine test	HRCT parameter	Large CP	Moderate CP	Small CP	P value (ANOVA TEST)
<20 min	Pre-tympanic diameter	4.679±0.918	4.243±0.750	5.600±0.000	0.619
	Eustachian tube angle	27.93±3.13	27.55±4.49	23.00±0.00	0.200
	Tubotympanic angle	137.07±7.50	138.47±3.06	128.46±0.00	0.060
20–45 min	Pre-tympanic diameter	5.180±0.343	3.990±0.904	4.348±1.064	0.060
	Eustachian tube angle	24.67±3.72	25.42±2.21	27.50±2.12	0.300
	Tubotympanic angle	133.47±5.33	141.70±15.48	144.99±6.03	0.200

In the left ear, pre-tympanic diameter and tubo-tympanic angle showed no significant association with saccharine clearance time (p=0.88 and p=0.39, respectively). However, the Eustachian tube angle was significantly lower in participants with delayed clearance compared with those with clearance time <20 minutes (25.07° vs. 27.46°, p=0.037).

Tables 6 and 7 demonstrate the association between saccharine clearance time, tympanic membrane perforation size, and HRCT-based Eustachian tube parameters in the right and left ears. In the right ear, among participants with saccharine clearance time <20 minutes, no significant differences were observed in pre-tympanic diameter, Eustachian tube angle, or tubo-tympanic angle across perforation sizes. In those with

delayed clearance (20–45 minutes), Eustachian tube angle and tubo-tympanic angle were significantly higher in moderate central perforations compared with large central perforations (p 0.03 and p=0.0019, respectively), while pre-tympanic diameter showed no significant difference.

In the left ear, no significant differences were observed in pre-tympanic diameter, Eustachian tube angle, or tubo-tympanic angle across different perforation sizes, irrespective of saccharine clearance time (p>0.05).

DISCUSSION

Age distribution

In the present study, the mean age of participants was 35.30 years, with the highest proportion belonging to the 31–40 years age group (30%) (Table 1). The observed age distribution is comparable with previous studies, including Majhi et al who reported a higher prevalence of chronic otitis media among individuals aged 30–44 years.[5] Similar findings by Kumar et al and Suresh Menon et al suggest that age-related anatomical and functional changes may influence Eustachian tube morphology and function.[6,7] The present findings are therefore consistent with earlier reports describing chronic otitis media across adult age groups.

Sex distribution

A female predominance was observed in the present study, with females comprising 58% and males 42% of participants (female-to-male ratio 1.3:1). This finding is consistent with the observations of Sunny et al, who reported a similar female predominance. However, contrasting results have been reported by Singh et al, who observed a male predominance, suggesting that sex distribution may vary among different study populations.[8,9]

Tympanic membrane perforation pattern

The present study showed that bilateral large central perforations were the most frequent pattern (32%), followed by bilateral moderate central perforations (26%). Bilateral small central perforations were not observed, while unilateral small central perforations were present in 18% of cases. These findings are in agreement with Singh et al, who reported a predominance of large central perforations among patients with mucosal chronic otitis media.[9] The predominance of larger central perforations may reflect the progressive nature of chronic middle ear disease and prolonged Eustachian tube dysfunction.

Saccharine test and mucociliary clearance

The saccharine test demonstrated normal mucociliary clearance (<20 minutes) in 84% of right ears and 70% of left ears, with an overall normal clearance rate of 77%. Mildly prolonged clearance (20–45 minutes) was observed more frequently in the left ear. These findings are comparable with those reported by Das et al.[10] The mean saccharine clearance time was higher in the left ear (16.45 minutes) compared with the right ear (13.05 minutes), indicating relatively reduced mucociliary clearance on the left side. Similar interaural variations in Eustachian tube function have been reported by Vivek et al and Patel et al, which may be attributed to anatomical variations and chronic inflammatory changes associated with chronic otitis media.[11,12]

Eustachian tube parameters on HRCT temporal bone

Pre-tympanic diameter

In the present study, the mean pre-tympanic diameter was 4.91 mm in the right ear and 4.53 mm in the left ear, with a mean interaural difference of 0.38 mm (Table 3). The right ear demonstrated a significantly larger pre-tympanic diameter compared with the left (p<0.05). Variations in the bony and cartilaginous components of the Eustachian tube may influence middle ear ventilation and drainage. Similar observations have been reported by Smith et al, who suggested that reduced pre-tympanic diameter may serve as a potential radiological marker associated with chronic middle ear disease.[13]

Eustachian tube angle

The mean Eustachian tube (ET) angle was 26.48° in the right ear and 26.75° in the left ear, with no significant interaural difference. The findings are comparable with those of Takasaki et al, who reported mean ET angles of 27.3°±2.0° and 27.3°±2.8° in the right and left ears, respectively, among healthy adults.[14] Nemade et al demonstrated a reduced Reid plane ET angle in diseased ears compared with healthy ears, suggesting that altered ET orientation may contribute to impaired middle ear ventilation.[15] The present findings support the role of ET morphology as one of the contributing factors in chronic middle ear pathology.

Tubo-tympanic angle

The mean tubo-tympanic angle was 140.15° in the right ear and 137.87° in the left ear, with a mean interaural difference of 2.28°. Although the right-sided angle was slightly larger, the difference was not statistically significant (p>0.05). The observed values are comparable with previous reports by Takasaki et al, who demonstrated a relationship between altered tubo-tympanic angulation and chronic middle ear disease.[14] In the present study, the tubo-tympanic angle measurements were within the range described in patients with chronic otitis media, indicating that this parameter may contribute to Eustachian tube efficiency but is unlikely to act as an isolated determinant of dysfunction.

Association of saccharine test with tympanic membrane perforation size (Table 4)

The present study evaluated the relationship between mucociliary clearance and tympanic membrane perforation size using the saccharine test. Although variations in clearance time were observed among different perforation sizes, no statistically significant association was identified. These findings suggest that perforation size alone may not determine mucociliary clearance in patients with inactive mucosal chronic otitis media. Previous studies by Prasad et al and Ikehata et al. have also demonstrated variability in saccharine clearance times, indicating that Eustachian tube function depends on multiple factors, including mucosal integrity, ciliary activity, and pressure regulation mechanisms.[14,16]

Correlation between saccharine test and HRCT-based eustachian tube parameters (Table 5)

The present study demonstrated a limited correlation between anatomical parameters of the Eustachian tube on HRCT and functional assessment by saccharine testing. In the right ear, pre-tympanic diameter showed a significant association with saccharine clearance time ($p=0.047$), with delayed clearance observed among participants with larger mean pre-tympanic diameter. However, ET angle and tubo-tympanic angle showed no significant correlation with saccharine clearance time.

In the left ear, pre-tympanic diameter and tubo-tympanic angle were not significantly associated with saccharine clearance time, whereas ET angle demonstrated a significant association ($p=0.037$), with smaller angles being associated with delayed mucociliary clearance. These findings indicate that static anatomical parameters alone may not fully predict functional Eustachian tube performance. Similar observations by Kumar et al., Sharma et al, and Vivek et al highlight the multifactorial nature of Eustachian tube dysfunction, involving anatomical configuration, mucosal changes, and dynamic muscular function.[11]

Association of saccharine test, tympanic membrane perforation, and HRCT findings (Table 6 & 7)

The relationship between saccharine clearance time, tympanic membrane perforation size, and HRCT-based Eustachian tube parameters demonstrated variable patterns in both ears. In the right ear, participants with normal saccharine clearance (<20 minutes) predominantly had large central perforations, whereas delayed clearance was associated with variations in ET angle and tubo-tympanic angle, particularly among moderate perforations.

Similarly, in the left ear, large central perforations were commonly observed among participants with normal clearance, while prolonged saccharine clearance showed greater variability in Eustachian tube parameters. The association between ET angle and perforation characteristics suggests that anatomical orientation may influence mucociliary function in selected cases.

Overall, the present study indicates that Eustachian tube dysfunction in chronic otitis media is a complex process influenced by the interaction of anatomical variations, mucosal condition, and functional impairment. HRCT-based measurements provide valuable anatomical information; however, combining radiological assessment with functional tests such as the saccharine test may provide a more comprehensive evaluation of Eustachian tube function and its role in chronic middle ear disease.

There are some limitations to the present study. The study had a relatively small sample size of 50 patients and was conducted at a single centre, which may limit the statistical power and generalizability of the findings. Its cross-sectional observational design allows identification of associations but does not establish causal relationships. The saccharine test is an indirect measure of mucociliary clearance and may be influenced by individual physiological variations and other factors affecting mucociliary function. HRCT provides information on static anatomical parameters but does not assess the dynamic function of the Eustachian tube. The associations between saccharine clearance time and anatomical parameters were not consistent across both ears, limiting the identification of a uniform anatomical predictor. Potential confounding factors such as nasal pathology, allergic rhinitis, upper respiratory tract infections, and smoking may also have influenced the results. Additionally, other objective Eustachian tube function tests, such as tympanometry, sonotubometry, tubomanometry, and pressure chamber testing, were not included, which could have provided complementary functional information.

CONCLUSION

This study evaluated Eustachian tube function using the saccharine test and anatomical parameters using HRCT temporal bone. HRCT with multiplanar reconstruction provides a reliable, non-invasive method for assessing Eustachian tube anatomy. Although anatomical parameters such as Eustachian tube angle, pre-tympanic diameter, and tubotympanic angle showed variability, their correlation with saccharine test results was weak, suggesting that Eustachian tube function is influenced by multiple factors beyond static anatomical measurements.

Funding: No funding sources
Conflict of interest: None declared
Ethical approval: The study was approved by the Institutional Ethics Committee

REFERENCES

1. Bluestone CD. Eustachian tube: structure, function, role in otitis media. Hamilton (ON): BC Decker Inc.; 2005.
2. Fujii N, Inui Y, Katada K. Temporal bone anatomy: correlation of multiplanar reconstruction sections

and three-dimensional computed tomography images. Jpn J Radiol. 2010;28(9):637–48.
3. Prasad KC, Hegde MC, Prasad SC, Meyappan H. Assessment of eustachian tube function in tympanoplasty. Otolaryngol Head Neck Surg. 2009;140(6):889–93.
4. Yoshida H, Kobayashi T, Takasaki K, Takahashi H, Ishimaru H, Morikawa M, et al. Imaging of the patulous Eustachian tube: high-resolution CT evaluation with multiplanar reconstruction technique. Acta Otolaryngol. 2004;124(8):918–923.
5. Rayamajhi P, Aggarwal P, Dutta HD, Tripathi P, Kharel B, Pradhananga RB, et al. Burden of chronic otitis media—mucosal type and the impact of its surgical management in the quality of life of patients in a tertiary hospital. Nepalese J ENT Head Neck Surg. 2020;11(2):19–24.
6. Mohan Kumar J, Rajasekar MK. Evaluation of Eustachian tube function in chronic suppurative otitis media in relation to surgical treatment results. J Res Med Dent Sci. 2022;10(1):548–554.
7. Menon et al. HRCT findings of CSOM. Sch J Appl Med Sci. 2015;3(4C):1765–8.
8. Sunny FA, Nalamate R, Chandran S, et al. Mucosal-type chronic otitis media: clinical predictors of postoperative success. Cureus. 2024;16(3):e56213.
9. Virk RS, Kudawla K, Bansal S, Rathod R, Behera S. Correlation of site and size of tympanic membrane perforation and middle ear air space volume with magnitude of hearing loss. Ann Otol Neurotol. 2019;2(1).
10. Das AK, Varshney H, Biswas S, Ghosh SK, Varshney J. Relationship between Eustachian tube function and location of the perforation in chronic otitis media. Indian J Otol. 2015;21(1):51–6.
11. Vivek S, Menon UK, Sandya CJ, Polson AM. Study of the reliability of high-resolution CT scan evaluation of Eustachian tube as predictor of predisposition for chronic otitis media. Indian J Otolaryngol Head Neck Surg. 2022;74(Suppl 1):332–338.
12. Patel DK, Sahu J. Assessment of Eustachian tube function in middle ear diseases. Indian J Appl Res. 2022;12(3):69–72.
13. Llewellyn A, Norman G, Harden M, Coatesworth A, Kimberling D, Schilder A, et al. Interventions for adult Eustachian tube dysfunction: a systematic review. Health Technol Assess. 2014;18(46):1–180.
14. Takasaki K, Takahashi H, Miyamoto I, Yoshida H, Yamamoto-Fukuda T, Enatsu K, et al. Measurement of angle and length of the Eustachian tube on computed tomography using the multiplanar reconstruction technique. Laryngoscope. 2007;117:1251–4.
15. Nemade SV, Shinde KJ, Rangankar VP, Bhole P. Evaluation and significance of Eustachian tube angles and pretympanic diameter in HRCT temporal bone of patients with chronic otitis media. World J Otorhinolaryngol Head Neck Surg. 2018;4(4):240-5.
16. Ikeda R, Kikuchi T, Oshima H, Miyazaki H, Hidaka H, Kawase T, et al. Computed tomography findings of the bony portion of the Eustachian tube with or without patulous Eustachian tube patients. Eur Arch Otorhinolaryngol. 2017;274(2):781–6.

Cite this article as: Shaikh A, Rokade V, Sawant D, Alam SJ. Evaluation of status of Eustachian tube by saccharine test and high-resolution computed tomography of the temporal bone in bilateral inactive mucosal chronic otitis media. Int J Otorhinolaryngol Head Neck Surg 2026;12:924-31.