International Journal of Otorhinolaryngology and Head and Neck Surgery
Elangovan P et al. Int J Otorhinolaryngol Head Neck Surg. 2026 Dec;12(6):918-923
https://www.ijorl.com
pISSN 2454-5929 | eISSN 2454-5937

DOI: https://dx.doi.org/10.18203/issn.2454-5929.ijohns20264272

Original Research Article

Effectiveness of steroid therapy in patients with sinonasal polyposis

Pugazhendhi Elangovan*, Marur Mehanaz Begum, Sridhara S.

Department of Otorhinolaryngology, Shivamogga Institute of Medical Sciences, Shivamogga, Karnataka, India

Received: 16 August 2026
Revised: 04 November 2026
Accepted: 19 November 2026

***Correspondence:**
Dr. Pugazhendhi Elangovan,
E-mail: drpugazh98@gmail.com

Copyright: © the author(s), publisher and licensee Medip Academy. This is an open-access article distributed under the terms of the Creative Commons Attribution Non-Commercial License, which permits unrestricted non-commercial use, distribution, and reproduction in any medium, provided the original work is properly cited.

ABSTRACT

Background: Sinonasal polyposis is a chronic inflammatory condition of the nasal cavity and paranasal sinuses that significantly impairs quality of life, presenting with nasal obstruction, discharge, hyposmia, and facial pressure. Corticosteroids remain the cornerstone of treatment due to their strong anti-inflammatory effects, reducing mucosal edema and polyp size. The aim of the present study was to evaluate the effectiveness of steroid therapy in newly diagnosed sinonasal polyposis and Objectives were to assess symptomatic improvement using TNSS, evaluate endoscopic changes with the modified Lund-Kennedy score, and assess radiological improvement using the Kennedy staging system.
Methods: This prospective observational study was conducted at Shivamogga Institute of Medical Sciences from February 2024 to February 2025 and included 100 patients with unilateral or bilateral sinonasal polyposis. Baseline assessment involved Total Nasal Symptom Score (TNSS), diagnostic nasal endoscopy graded by the Modified Lund–Kennedy score, and radiological evaluation using the Kennedy staging system. Patients received topical corticosteroids for three months along with a two-week course of oral steroids. Post-treatment outcomes were assessed using the same parameters.
Results: Significant improvement was observed in TNSS, with reduction in polyp size on endoscopy and improved radiological staging, particularly in less extensive disease.
Conclusions: Steroid therapy is an effective first-line treatment for sinonasal polyposis, offering symptomatic relief and objective improvement, potentially delaying surgical intervention.

Keywords: Nasal polyps, Corticosteroids, Endoscopy, Computed tomography

INTRODUCTION

Sinonasal polyposis is a chronic inflammatory disorder involving the nasal cavity and paranasal sinuses. It is characterised by benign polypoidal growths that commonly present with nasal obstruction, reduced or altered sense of smell, facial pressure and persistent nasal discharge. These symptoms can interfere with daily activities and have a considerable impact on quality of life.[1] Although the exact cause of the condition is not fully understood, its development is believed to involve several interacting factors, including genetic predisposition, environmental influences and persistent inflammation of the sinonasal mucosa.[2] Nasal polyposis may occur alongside other medical conditions, including bronchial asthma, aspirin intolerance and cystic fibrosis. It has also been associated with conditions such as Churg–Strauss syndrome and impaired mucociliary clearance. These associations suggest that sinonasal polyposis is a complex inflammatory condition rather than an isolated disorder of the nasal mucosa.[3]

The management of sinonasal polyposis includes both medical and surgical options, with the choice of treatment depending on disease severity, symptom burden and

response to medical therapy.[4] Corticosteroids form an important part of medical management because their anti-inflammatory action can reduce mucosal oedema, polyp size and associated symptoms.[5] However, some patients do not achieve adequate disease control with medical treatment alone and may require surgical intervention.[6]

Topical corticosteroids are commonly used for ongoing treatment, whereas systemic corticosteroids may be prescribed for a short period when more rapid control of inflammation is required. Their use must be balanced against the possibility of systemic adverse effects, particularly with prolonged treatment.[7,8] In this context, the present study evaluates the effectiveness of steroid therapy in sinonasal polyposis by assessing changes in symptoms, endoscopic findings and radiological disease severity before and after treatment.

METHODS

Study design and setting

This prospective observational study was conducted in the Department of Otorhinolaryngology at Shivamogga Institute of Medical Sciences, Shivamogga, from February 2024 to February 2025.

Study participants

The study included patients of all age groups and both sexes who were newly diagnosed with unilateral or bilateral sinonasal polyposis. The diagnosis was established through clinical examination, diagnostic nasal endoscopy and, where available, computed tomography of the paranasal sinuses.

Inclusion and exclusion criteria

Patients diagnosed with sinonasal polyposis and planned for steroid therapy were considered eligible for inclusion. Patients with immunocompromised status, mucociliary disorders, allergic fungal rhinosinusitis, acute infections, antrochoanal polyps or recurrent nasal polyps were excluded from the study.

Study procedure

At baseline, all participants underwent clinical assessment using the Total Nasal Symptom Score (TNSS), diagnostic nasal endoscopy using the Modified Lund–Kennedy grading system, and computed tomography assessment using the Kennedy radiological staging system. Patients were treated with intranasal fluticasone furoate (27.5 micrograms) for three months, together with oral deflazacort (6 mg twice daily) for two weeks. Following completion of treatment, participants were reassessed using the same clinical, endoscopic and radiological parameters to evaluate changes from baseline.

Sample size

A total of 100 patients with newly diagnosed sinonasal polyposis were included in the study.

Ethical considerations

The study was conducted after obtaining approval from the Institutional Ethics Committee (IEC), Shivamogga Institute of Medical Sciences (SIMS), Shivamogga, Karnataka, India (Approval No. SIMS/IEC/903/2023-24, dated 12 February 2024). Written informed consent was obtained from all participants before their inclusion in the study

Statistical analysis

Data were analysed using IBM SPSS Statistics, version 23. Continuous variables were expressed as mean and standard deviation, while categorical variables were presented as frequencies and percentages. Pre-treatment and post-treatment findings were compared to assess changes in symptom scores, endoscopic grades and radiological stages.

RESULTS

Socio-demographic characteristics

A total of 100 patients with newly diagnosed sinonasal polyposis were included in the study. Out of these, 67 (67%) were male and 33 (33%) were female. The participants ranged in age from 19 to 71 years, with a mean age of 46.7 years and a median age of 47.5 years. More than half of the participants (54%) were older than 45 years. Participants aged 36–45 years accounted for 17%, while 14% were aged 26–35 years and 15% were 25 years or younger (Figure 1). The sex distribution is shown in Figure 2.

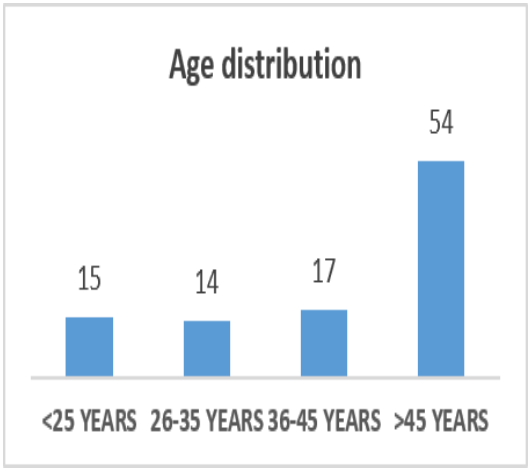

Figure 1: Age distribution of study participants with sinonasal polyposis.

Clinical presentation

Nasal obstruction was the most frequently reported presenting symptom and was present in all 100 participants (100%). Other common symptoms included sneezing in 83 patients (83%), nasal discharge in 65 (65%) and headache in 57 (57%). Altered sense of smell and post-nasal drip were each reported by 11 patients (11%) (Figure 3).

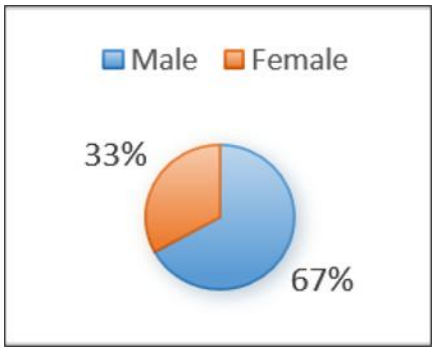

Figure 2: Sex distribution of study participants with sinonasal polyposis.

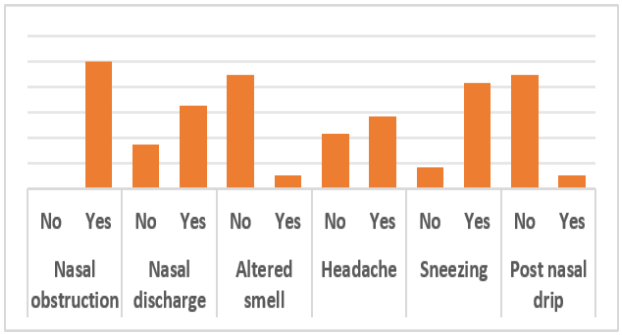

Figure 3: Distribution of presenting symptoms among study participants with sinonasal polyposis.

Bilateral nasal obstruction was observed in 83% of patients, while the remaining 17% had unilateral obstruction. Nasal discharge was absent in 50% of patients, clear in 33% and purulent in 17%.

On clinical examination, polyps were visualised on anterior rhinoscopy in 80% of patients, while 85% had polyps visible within the nasal cavity. Septal deviation was present in 78% of participants, including left-sided deviation in 55% and right-sided deviation in 23%. Inferior turbinate hypertrophy was noted in 35% of patients.

Baseline vs. post-treatment outcomes

TNSS score

Before treatment, TNSS values ranged from 2 to 10, with a mean score of 6.05±2.08. Following steroid therapy, scores ranged from 0 to 6, with a mean of 2.56±1.82. This reduction indicates a marked improvement in reported nasal symptoms after treatment. The paired comparison showed a statistically significant reduction in TNSS (Wilcoxon signed-rank test, $p<0.001$) (Figure 4).

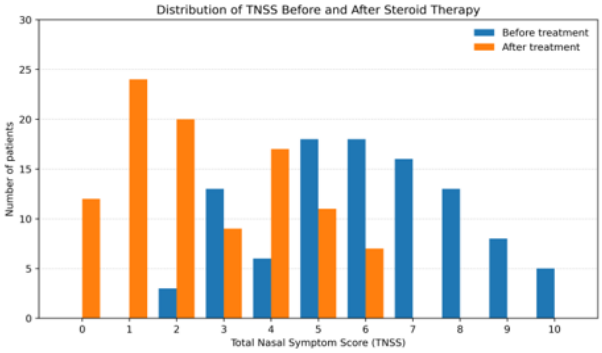

Figure 4: Comparison of TNSS scores before and after steroid therapy among study participants.

Endoscopic score

At baseline, endoscopic assessment showed grade 1 polyps in 29% of patients, grade 2 in 48% and grade 3 in 23%. No patients were classified as grade 0 before treatment. Following steroid therapy, 24% of patients had no visible polyps (grade 0), while 46% had grade 1, 28% had grade 2 and 2% had grade 3 findings. This distribution demonstrates a shift towards lower endoscopic grades after treatment (Figures 5 and 6).

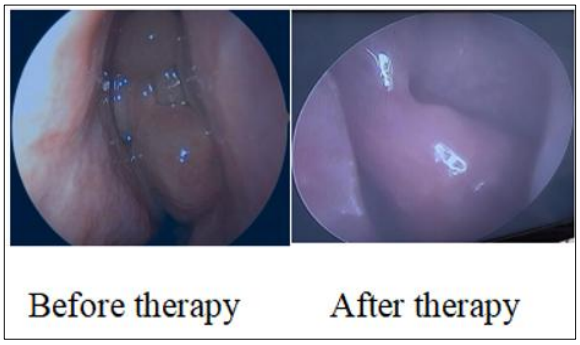

Figure 5: Diagnostic nasal endoscopic images demonstrating sinonasal polyposis before and after steroid therapy (from grade 3 to 2).

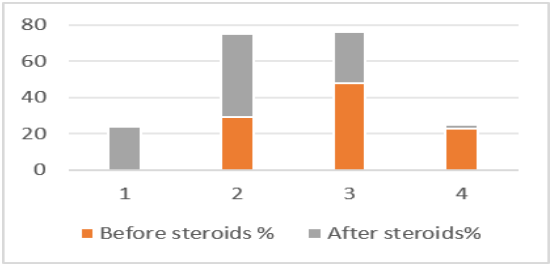

Figure 6: Comparison of modified Lund-Kennedy endoscopic scores before and after steroid therapy among study participants.

Post-treatment radiological findings

Radiological score

At baseline, radiological assessment showed grade 1 disease in 19% of patients, grade 2 in 27%, grade 3 in 39% and grade 4 in 15%. No patients were classified as grade 0 before treatment. Following steroid therapy, 22% of patients were classified as grade 0, 31% as grade 1, 40% as grade 2 and 7% as grade 3. No patients remained in grade 4 after treatment. These findings indicate an overall shift towards lower radiological grades following steroid therapy (Figures 7 and 8).

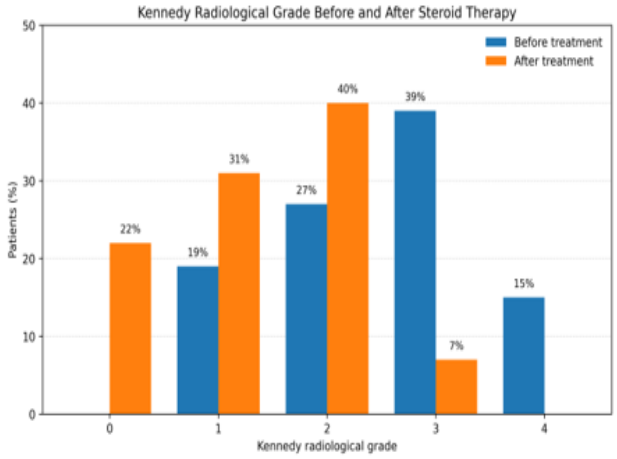

Figure 7: Comparison of Kennedy radiological staging before and after steroid therapy among study participants.

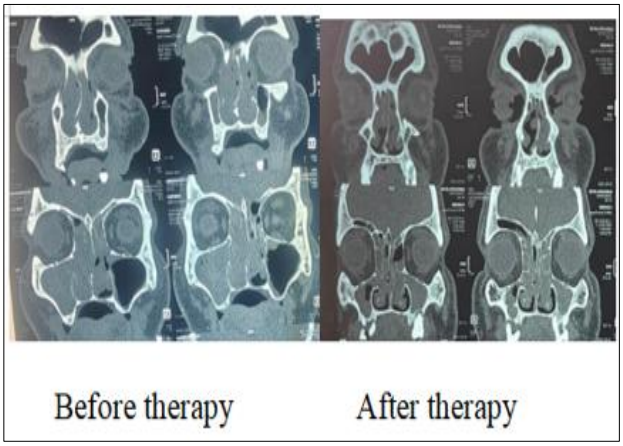

Figure 8: Computed tomography images showing sinonasal polyposis before and after steroid therapy (improved from grade 4 to 3).

Overall, the findings showed improvement in symptom scores, endoscopic grades and radiological staging following steroid therapy. The paired comparisons demonstrated statistically significant changes in all three assessment parameters ($p<0.001$).

DISCUSSION

The present study evaluated the effectiveness of steroid therapy in patients with sinonasal polyposis by assessing symptomatic, endoscopic, and radiological outcomes. The findings demonstrated significant improvement across all parameters, reinforcing the established role of corticosteroids as the cornerstone of medical management in chronic rhinosinusitis with nasal polyps (CRSwNP).[1]

In this study, males constituted the majority (67%), while females accounted for 33%. The age ranged from 19 to 71 years, with a mean of 46.9±16.1 years. These findings are consistent with previous epidemiological studies reporting male predominance and peak incidence in the fourth and fifth decades of life.[2] Similar demographic patterns have been described by Settipane and by Kirtsreesakul et al and Hissaria et al who reported comparable mean ages in patients undergoing corticosteroid therapy.[3,4]

Nasal obstruction was the most common presenting symptom, followed by sneezing, nasal discharge, and headache, while olfactory disturbance and post-nasal drip were less frequent. This pattern is consistent with the classical clinical presentation of CRSwNP, where nasal obstruction and rhinorrhea predominate.[5] Berkiten et al and Van Zele et al have also identified nasal obstruction as the most disabling symptom in such patients.[6,7]

Endoscopic findings revealed that polyps were most commonly located in the middle meatus and sphenoethmoidal recess, in accordance with the anatomical drainage pathways of the paranasal sinuses. Radiological assessment showed predominant involvement of the ethmoid sinuses, followed by the maxillary and frontal sinuses. This distribution is consistent with previous reports suggesting that ethmoid sinus disease often represents the initial site of inflammation in CRSwNP.[8]

A significant reduction in symptom severity was observed following steroid therapy. The mean Total Nasal Symptom Score (TNSS) decreased markedly, with statistical analysis confirming significant improvement ($Z=-8.74$, $p<0.001$). Similar reductions in symptom scores have been reported by Berkiten et al, Kirtsreesakul et al and Hissaria et al following corticosteroid therapy.[3,4,6] This improvement can be attributed to the potent anti-inflammatory effects of corticosteroids, which suppress eosinophilic inflammation and reduce mucosal edema.[9]

Endoscopic evaluation using the Modified Lund–Kennedy scoring system demonstrated significant reduction in polyp size after treatment. Post-treatment, 24% of patients showed complete resolution of polyps, with a marked decrease in higher grades ($Z=-7.62$, $p<0.001$). These findings are comparable to those reported by Gevaert et al and by Wright and Agrawal

who documented significant reductions in polyp burden following corticosteroid therapy.[10,11]

Radiological evaluation also demonstrated significant improvement, with a shift toward lower disease grades after treatment ($Z=-6.84$, $p<0.001$). Although radiological changes may occur more gradually, these findings support the beneficial effect of corticosteroids on sinonasal mucosal inflammation. Similar observations have been reported by Van Zele et al and Tuncer et al.[7,12]

Overall, the present study demonstrates that steroid therapy results in significant improvement in symptoms, endoscopic findings, and radiological severity in sinonasal polyposis. These findings are consistent with current international guidelines, including the European Position Paper on Rhinosinusitis and Nasal Polyps (EPOS), which recommend corticosteroids as the first-line treatment modality.[13]

Further clinical considerations are relevant when interpreting the present findings. Hummel et al examined the effects of systemic corticosteroids on olfactory function, highlighting the importance of olfactory disturbance as a clinical feature in patients with sinonasal disease.[14] In the present study, altered sense of smell was reported by 11% of patients; however, olfactory function was not assessed as a separate pre and post-treatment outcome. Therefore, improvement in olfaction cannot be concluded from our results. Settipane has discussed the epidemiology of nasal polyps, providing a broader context for interpreting the demographic characteristics observed in different patient populations.[15] Differences in population characteristics and study settings should nevertheless be considered when comparing demographic patterns. The staging framework described by Lund and Kennedy also highlights the importance of systematic assessment of disease extent in rhinosinusitis.[16]

Surgical management remains an important consideration in patients who do not achieve adequate control with medical treatment. Stammberger and Posawetz described the concept, indications, and results of functional endoscopic sinus surgery, while Kennedy discussed the development and role of this surgical approach.[17,18] These contributions provide the background for the current role of endoscopic sinus surgery in the management of sinonasal disease. The present study, however, evaluated medical treatment outcomes and did not directly compare steroid therapy with surgical intervention.

The inflammatory processes associated with sinonasal polyposis are complex. Baraniuk and Kaliner discussed the role of neuropeptides in nasal secretion, while Lund et al examined neurogenic inflammation in nasal polyposis.[19,20] These studies provide additional pathophysiological context for the nasal secretory and inflammatory features observed in this condition. Although the present study did not investigate neuropeptide activity or neurogenic inflammatory pathways, these mechanisms may help explain the complex clinical manifestations of sinonasal polyposis.

Topical corticosteroid delivery is another important aspect of medical management. Bernstein et al reviewed the evidence supporting nasal corticosteroid irrigation in chronic rhinosinusitis.[21] The present study used intranasal fluticasone furoate spray rather than corticosteroid irrigation; therefore, the findings of irrigation studies are not directly equivalent to the treatment regimen used here. Nevertheless, this literature provides broader context for the use of topical corticosteroids in the management of chronic sinonasal inflammation.

CONCLUSION

This prospective observational study evaluated the effectiveness of steroid therapy in patients with sinonasal polyposis using clinical, endoscopic, and radiological assessment tools. Symptom severity was assessed using the Total Nasal Symptom Score (TNSS), while disease severity was evaluated through the Modified Lund–Kennedy endoscopic grading system and the Kennedy radiological staging system. The results demonstrated a significant reduction in symptom severity following steroid therapy, as reflected by the marked decrease in TNSS scores. Endoscopic evaluation revealed a substantial reduction in polyp size and mucosal inflammation, while radiological findings showed improvement in sinus involvement in a majority of patients. These changes were statistically significant, indicating the effectiveness of corticosteroid therapy in reducing the inflammatory burden associated with sinonasal polyposis. Overall, the findings of this study support the role of steroid therapy as an effective first-line treatment for sinonasal polyposis. Corticosteroid therapy provides significant clinical, endoscopic, and radiological improvement and may help reduce disease severity and delay or avoid the need for surgical intervention in selected patients

Funding: No funding sources
Conflict of interest: None declared
Ethical approval: The study was approved by the Institutional Ethics Committee

REFERENCES

1. Berkiten G, Salturk Z, Topaloğlu I. Efficacy of systemic steroid treatment in sinonasal polyposis. J Craniofac Surg. 2013;24(3):e305-8.
2. Kirtsreesakul V, Wongsritrang K, Ruttanaphol S. Clinical efficacy of a short course of systemic steroids in nasal polyposis. Rhinology. 2011;49(5):525-32.
3. Van Zele T, Gevaert P, Holtappels G, Beule A, Wormald PJ, Mayr S, et al. Oral steroids and doxycycline: two different approaches to treat nasal polyps. J Allergy Clin Immunol. 2010;125(5):1069-76.e4.

4. Gevaert P, Van Zele T, Holtappels G, Van Cauwenberge P, Bachert C. Oral corticosteroids in nasal polyposis: effects on inflammation and polyp size. J Allergy Clin Immunol. 2006;118(5):1133-41.
5. Meltzer EO, Munafo DA, Chung W, Gopalan G, Varghese ST. Intranasal mometasone furoate therapy for allergic rhinitis symptoms and rhinitis-disturbed sleep. Ann Allergy Asthma Immunol. 2010;105(1):65-74.
6. Snidvongs K, Kalish L, Sacks R, Sivasubramaniam R, Cope D, Harvey RJ. Sinus surgery and delivery method influence the effectiveness of topical corticosteroids for chronic rhinosinusitis: systematic review and meta-analysis. Am J Rhinol Allergy. 2013;27(3):221-33.
7. Wright ED, Agrawal S. Impact of perioperative systemic steroids on surgical outcomes in patients with chronic rhinosinusitis with polyposis: evaluation with the novel Perioperative Sinus Endoscopy (POSE) scoring system. Laryngoscope. 2007;117(11 Pt 2 Suppl 115):1-28.
8. Rudmik L, Soler ZM. Medical therapies for adult chronic sinusitis: a systematic review. JAMA. 2015;314(9):926-39.
9. Fokkens WJ, Lund VJ, Hopkins C, Hellings PW, Kern R, Reitsma S, et al. European position paper on rhinosinusitis and nasal polyps 2020. Rhinology. 2020;58(Suppl S29):1-464.
10. Hissaria P, Smith W, Wormald PJ, et al. Short-course systemic corticosteroids in nasal polyposis. J Allergy Clin Immunol. 2006;118(1):128-33.
11. Tuncer U, Soylu L, Aydogan B, et al. Effectiveness of steroid treatment in nasal polyposis. Auris Nasus Larynx. 2003;30(3):263-8.
12. Barnes PJ. Glucocorticoids: current and future directions. Br J Pharmacol. 2011;163(1):29-43.
13. Allen DB. Systemic effects of intranasal steroids: an endocrinologist's perspective. J Allergy Clin Immunol. 2000;106(4 Suppl):S179-90.
14. Hummel T, Rissom K, Reden J, Hähner A, Weidenbecher M, Hüttenbrink KB. Effects of systemic corticosteroids on olfactory function. Arch Otolaryngol Head Neck Surg. 2003;129(6):640-3.
15. Settipane GA. Epidemiology of nasal polyps. Allergy Asthma Proc. 1996;17(5):231-6.
16. Lund VJ, Kennedy DW. Staging for rhinosinusitis. Otolaryngol Head Neck Surg. 1997;117(3 Pt 2):S35-40.
17. Stammberger H, Posawetz W. Functional endoscopic sinus surgery. Concept, indications and results of the Messerklinger technique. Eur Arch Otorhinolaryngol. 1990;247(2):63-76.
18. Kennedy DW. Functional endoscopic sinus surgery. Arch Otolaryngol. 1985;111(9):576-82.
19. Baraniuk JN, Kaliner MA. Neuropeptides and nasal secretion. J Allergy Clin Immunol. 1990;86(4 Pt 2):620-7.
20. Lund VJ, Dessi P, Zohar Y. Neurogenic inflammation in nasal polyposis. Acta Otolaryngol. 1991;111(5):885-92.
21. Bernstein JA, White AA, Han JK, Lang DM, Elkayam D, Baroody FM. Review of evidence supporting the use of nasal corticosteroid irrigation for chronic rhinosinusitis. Ann Allergy Asthma Immunol. 2023;130(1):46-57.

Cite this article as: Elangovan P, Begum MM, Sridhara S. Effectiveness of steroid therapy in patients with sinonasal polyposis. Int J Otorhinolaryngol Head Neck Surg 2026;12:918-23.