International Journal of Otorhinolaryngology and Head and Neck Surgery
Kumar N et al. Int J Otorhinolaryngol Head Neck Surg. 2026 Dec;12(6):888-895
https://www.ijorl.com
pISSN 2454-5929 | eISSN 2454-5937

DOI: https://dx.doi.org/10.18203/issn.2454-5929.ijohns20264268

Original Research Article

Dreaded ENT diseases in patients with diabetes mellitus: challenges in management

Nikhil Kumar*, Kiran Natarajan, Kune Saphi Pyrbot, Parvathi, Raghunandhan S., Mohan Kameswaran

ENT Research Foundation, 1, 1st cross street, off 2nd main road, Raja Annamalaipuram, Chennai, India

Received: 17 July 2026
Revised: 22 September 2026
Accepted: 23 September 2026

***Correspondence:**
Dr. Nikhil Kumar,
E-mail: nikhilkumar1206@gmail.com

Copyright: © the author(s), publisher and licensee Medip Academy. This is an open-access article distributed under the terms of the Creative Commons Attribution Non-Commercial License, which permits unrestricted non-commercial use, distribution, and reproduction in any medium, provided the original work is properly cited.

ABSTRACT

Background: Diabetes mellitus is a very prevalent medical condition in the Indian subcontinent causing significant morbidity and mortality. In otorhinolaryngology, several ENT manifestations are noted ranging from mild to severe. The majority of ENT conditions in diabetic patients can be managed in the outpatient setting; however several dreaded complications such as malignant otitis externa (skull base osteomyelitis), invasive fungal sinusitis and deep neck space infections are commonly encountered and need aggressive management.
Methods: This is a retrospective study of the dreaded ENT complications of diabetes mellitus treated over a six-year period (Jan 2019–Jan 2025) in a tertiary care centre. The diagnostic modalities, treatment protocols and outcomes were analysed.
Results: All patients with skull base osteomyelitis, invasive fungal sinusitis and deep neck space infections underwent appropriate management of diabetes mellitus and the ENT complications were managed medically and surgically in a select group of patients. The outcomes of management were satisfactory at last follow-up.
Conclusion: Early identification and management of the diabetic complications in ENT is crucial for good outcomes. A multidisciplinary team has to be involved in the treatment. Awareness of the potential ENT complications, diagnosis and treatment protocols is vital.

Keywords: Skull base osteomyelitis, Invasive fungal sinusitis, Deep neck space infections, Diabetes mellitus, Management

INTRODUCTION

Diabetes mellitus (DM) is one of the most common non-communicable diseases in India and one of the leading causes of morbidity and mortality worldwide. It poses significant challenges in management due to multisystem involvement. Diabetes mellitus (DM) occurs in epidemic proportions in India and globally, more than 640 million persons are predicted to be affected by 2040.[1] Diabetes mellituhas numerous presentations and complications in the ear, nose, throat and head & neck. Decreased ability of wounds to heal and the patient's increased susceptibility to infection secondary to immunodeficiency are of great concern to otorhinolaryngologists.[2] Complications of DM occur due to micro and macrovascular disease, neuropathies or immunodeficiency secondary to impairment of leukocyte/phagocyte function.[2] These can be life threatening, especially if there is a delay in diagnosis and appropriate management. Hence awareness of the diseases complicating DM is crucial. Several dreaded complications such as malignant otitis externa (Skull base osteomyelitis -SBO), invasive fungal sinusitis and deep neck space infections are commonly seen in

otorhinolaryngology practice and requires prompt diagnosis and management.Malignant otitis externa (MOE/ SBO) - This condition is characterized by severe dangerous cellulitis & inflammation of the external auditory canal and temporal bone. Malignant (necrotizing) otitis externa, may be a medical emergency and occurs primarily in elderly individuals with diabetes mellitus.[1] Severe unrelenting nocturnal otalgia is characteristic, otorrhoea and hearing loss occur.

Mucormycosis (zygomycosis) is an opportunistic fungal infection in patients with immunosuppressive conditions such as diabetes mellitus, steroid use, hematological malignancies, neutropenia, and organ transplantation. The causative organisms are filamentous fungi of the Mucorales order, mainly Rhizopus species, Lichthemia species, and Mucor species.[3] The incidence of mucormycosis has increased significantly in recent years, particularly in India which has a high prevalence of diabetes mellitus.

Deep neck infections occur in spaces bound by cervical fascia and spread rapidly along fascial planes. Diabetic patients have an increased susceptibility to these infections.

This study aims to describe the diagnostic modalities, treatment and outcomes of patients with Malignant otitis externa, Rhino-orbital-cerebral mucormycosis (ROCM) and deep neck space infections managed at our center from January 2019 to January 2025.

METHODS

This is a retrospective study of patients with diabetes mellitus who had severe ENT complications and were managed at a tertiary care centre over a six-year period (January 2019–January 2025; 72 months). All patients diagnosed with malignant otitis externa, rhino-orbito-cerebral mucormycosis or deep neck space infection at our centre during the study period were included in the study and the diagnostic modalities, treatment protocols and outcomes were analysed. There was no comparison of the various conditions studied and no sample size calculation was performed. Inclusion criteria were patients with diabetes mellitus diagnosed clinically and radiologically with malignant otitis externa, rhino-orbito-cerebral mucormycosis or deep neck space infection during the study period. Exclusion criteria were patients who did not have diabetes mellitus and pediatric population. One hundred and eight patients were diagnosed with malignant otitis externa, sixty-one patients with rhinoorbitocerebral Mucormycosis and fifty-one patients with deep neck space infections. The clinical symptoms and signs were documented, imaging was done for all patients and all patients underwent medical management of their ENT complication, glycemic control by the diabetologist and surgery was indicated in select patients. Informed consent was taken and all patients underwent medical / surgical management. Institutional Ethics Committee approval was obtained. The outcomes in all patients were analysed and all patients were advised regular follow up.

RESULTS

This is a retrospective study of patients with diabetes mellitus who had severe ENT complications - malignant otitis externa, rhinoorbitocerebral Mucormycosis and deep neck space infections and were managed over a six year period (January 2019–January 2025).

Malignant otitis externa

The database comprised clinical records of 108 patients with MOE. The mean age was 66.8 years (range 40–85 years), with 82.4% of patients aged ≥60 years. Male predominance was marked (78 males vs. 30 females; M:F ratio 2.6:1). The mean fasting blood sugar (FBS) was significantly elevated at 284.5 mg/dL, with 73.7% of values exceeding 200 mg/dL and 10.5% surpassing 400 mg/dL. The mean HbA1c was 7.57% (range 4.2–13.3%); 29.4% had poor control (HbA1c ≥8%), and 15.7% had severely uncontrolled glycaemia (HbA1c ≥10%). Culture data showed that Pseudomonas aeruginosa was the dominant pathogen. Staphylococcus aureus was isolated in 2 cases, while Klebsiella species, Acinetobacter species, coagulase-negative Streptococcus, and Candida albicans were isolated in 4 different patients. Two specimens yielded no growth, likely due to prior antibiotic exposure. Inflammatory marker-ESR was universally elevated with a mean of 95.7 mm/hr (range 65–132 mm/hr); mean CRP was 34 mg/dl (range: 25-45 mg/dl). These markers served as both diagnostic and treatment-monitoring roles in MOE. HRCT temporal bones demonstrated a disease spectrum from soft tissue density in the EAC to otomastoiditis and focal tegmen tympani rarefaction. MRI scans were used to assess soft tissue involvement, for extensive disease, lower cranial nerve involvement or central SBO (CSBO) / intracranial disease. Gallium scans were done in a few patients with extensive disease to monitor recurrence (Figure 1).

All patients received aggressive intravenous antipseudomonal antibiotics and control of diabetes mellitus. Facial nerve palsy occurred in 17 patients (15.7%). Other neurological sequelae included multiple cranial nerve neuropathies (1.9%), intracranial extension (1.9%), meningitis (0.9%), hemiparesis (0.9%). The follow up duration was 25 months (mean duration- 11–34 months). Patients with external auditory canal, localized disease had excellent prognosis and were managed with intravenous antibiotic treatment and local debridement if necessary. All were disease free at last follow up. Patients with extensive skull base osteomyelitis were managed with long-term parenteral antibiotic treatment and sixty-eight patients underwent subtotal petrosectomy.

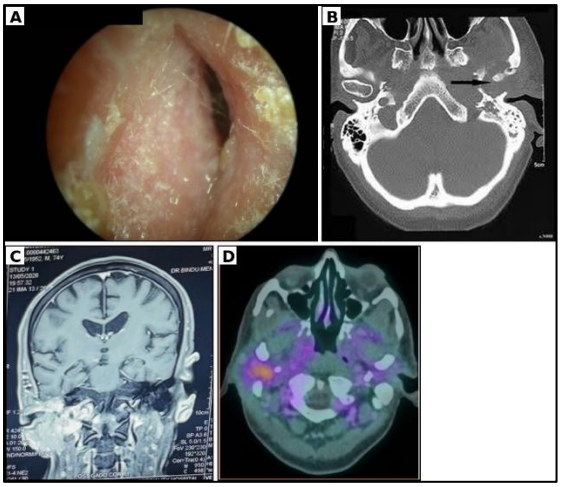

Figure 1: Malignant otitis externa in a diabetic patient, (A) Edema of the external auditory canal; (B) CT scan showing changes of malignant otitis externa; (C) MRI scan showing extensive right skull base osteomyelitis; (D) Gallium-67 scan showing recurrent disease in a patient post subtotal petrosectomy.

The recurrence/readmission rate was 19% driven primarily by persistent suboptimal glycaemic control. Patients with primary central skull base osteomyelitis or patients treated for lateral SBO who later on developed CSBO were referred to the neurosurgical team for further management. Of 32 patients with CSBO, 11 patients presented with primary CSBO with polymicrobial infection due to bacterial and fungal disease and these patients required long term antibiotics and anti-fungal therapy after confirmation of microbial flora through targeted endoscopic bone biopsy from the nasopharynx. Twenty-one patients developed CSBO and contralateral disease despite maximal medical therapy and surgical debridement possibly due to multi drug resistant organisms penetrating the periosteal barriers in an uncontrolled diabetic environment. The mortality rate for central skull base osteomyelitis in our series was 45% due to the rapid progression and virulent nature of the disease-causing intracranial complications.

Rhino-orbito-cerebral mucormycosis (2019–2025)

A cohort of 61 patients with invasive fungal sinusitis was analyzed. The mean age was 58.2 years (range 32–76 years), with an M:F ratio of 2.8:1. Uncontrolled diabetes mellitus was present in 56 patients (91.8%) on admission. A significant proportion of cases was linked to steroid-induced hyperglycaemia during treatment for the COVID-19 Delta variant wave: 46 patients (75.4%) had documented COVID-19, with 80.3% of all ROCM cases occurring in 2021 alone. All patients underwent diagnostic nasal endoscopy (Figure 2). CT/ MRI scans were done for all patients with ROCM (Figure. 2B, Figure 3).

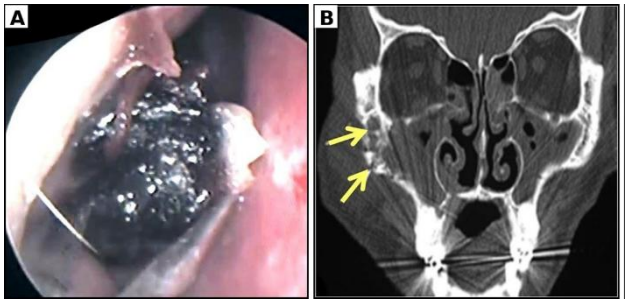

Figure 2: Diagnostic nasal endoscopy and clinical findings in rhino-orbito-cerebral mucormycosis, (A) Black eschar in the nasal cavity; (B) Invasive fungal sinusitis.

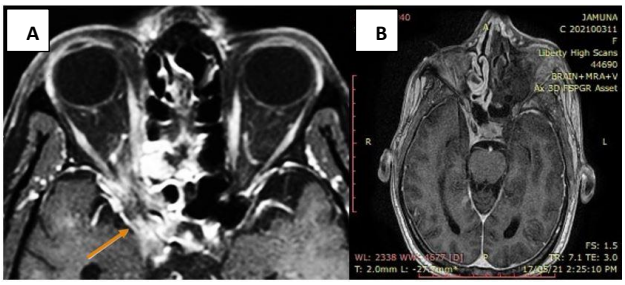

Figure 3: Imaging findings in rhino-orbito-cerebral mucormycosis, (A) T1 MRI showing invasive fungal infection involving the ethmoid sinus, orbital apex and cavernous sinus; (B) Rhino-orbito-cerebral mucormycosis resulting in stroke.

Rhinosinusitis was present in 25 patients (41%), rhino-orbital involvement in 19 (31.1%), and rhinocerebral extension in 7 patients (11.5%). All patients received liposomal Amphotericin B - 5 mg/kg/day (escalated to 10 mg/kg/day for CNS extension) up to a total dose of 3 grams. Patients with renal impairment were transitioned to oral Posaconazole or Isavuconazole. Seventeen patients underwent urgent sinonasal endoscopic debridement, partial/medial maxillectomy was done in 16 patients and total maxillectomy in 5 patients, orbital / optic nerve decompression in 3 patients, orbital exentertion in 1 patient (Figure 4).

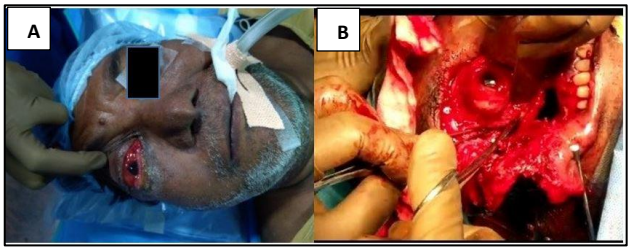

Figure 4: (A) Rhinoorbital mucormycosis, (B) Right orbital exenteration for rhino-orbital mucormycosis.

Seven patients with cerebral mucormycois were referred to the neurosurgical team for further management. All patients were under periodic follow up post treatment. The average follow up was for 12 months (9 months – 18 months). All patients with rhinological involvement were disease free at last follow up. Five patients developed recurrence which was managed medically. Post mucor treatment osteomyelitis was seen in 7 patients who were all treated for COVID-19 disease. They subsequently underwent surgical debridement by the ENT and maxillofacial team and are currently disease free. Patients with cerebral mucormycosis had the worst outcomes; survival was 100% in patients with rhinological (sinonasal) disease, 95% in those with rhino-orbital disease, and 10% in those with rhino-orbito-cerebral disease.

Deep neck space infections

Of the 51 patients included in the study from 2019 - 2025, 28 (54.9%) were females and 23 (45.1%) were males and the mean age was 57.6 years (range 33–81 years). Diabetes mellitus was present in all patients, with 49 patients having a pre-existing diagnosis and 2 patients being newly diagnosed during admission. CT / MRI scans were done for all patients (Figure. 5).

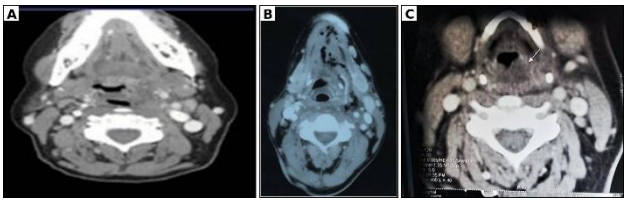

Figure.5: Imaging of deep neck space infections in diabetic patients. (A) Parapharyngeal abscess requiring incision and drainage. (B) CT scan showing Ludwig's angina requiring incision and drainage. (C) CT scan showing retropharyngeal infection.

Parotid abscess was the most frequently encountered abscess site, accounting for 21 cases (41.1%). Ludwigs angina was the next most common in 12 cases (23.5 %). Other sites included parapharyngeal (9 cases), retropharyngeal (5 cases) and peritonsillar (4 cases). Seventeen patients (33.3%) were successfully treated with medical management alone. Remaining 34 patients (66.7%) underwent surgical intervention–incision and drainage. Emergency tracheostomy was done for 4 patients. All patients were doing well at follow up. One patient developed recurrent Ludwigs angina for whom medical management and strict diabetic control was done and recovered without further complications. The average duration of follow up is 3 months (2–8 months).

DISCUSSION

Diabetes mellitus (DM) is a metabolic inflammatory disease-causing functional defect of immune cells, aberrant immune responses and production of inflammatory cytokines, causing an increased risk for infections. The chronic inflammatory state and the high-glucose environment in DM predisposes to several ENT infections and there is strong evidence of the interaction between metabolic and inflammatory signalling pathways.[4]

Malignant otitis externa (MOE/SBO)

MOE is a potentially life-threatening infection involving the external auditory canal, temporal bone and skull base and is increasingly seen in otolaryngology practice. The condition was initially described by Chandler in 1968 as an aggressive, often fatal infection of the external auditory canal and temporal bone, afflicting elderly diabetic patients.[5] Malignant (necrotizing) otitis externa occurs primarily in elderly individuals with diabetes mellitus.[6] It has been reported that the diabetic ear has a higher average pH (alkaline pH) which could provide a beneficial environment for bacterial overgrowth. The patient with MOE presents with severe unrelenting nocturnal otalgia, otorrhoea and hearing loss. The causative organism is mostly Pseudomonas aeruginosa, although other organisms are also implicated. Granulation tissue at the bony-cartilagenous junction and external auditory canal edema on otomicroscopy is characteristic of this condition.[2] The infection begins as an external otitis and cellulitis and can subsequently rapidly progress into an osteomyelitis of the skull base which may result in cranial nerve palsies involving cranial nerves VII, VIII, IX, X, XI and XII. In MOE, involvement of the facial nerve at the stylomastoid foramen has been reported in about 30%–40% of patients.[7] The temporomandibular joint may be involved by the infection. The infection can progress from lateral skull base osteomyelitis to central skull base osteomyelitis. Extensive intracranial involvement results in a mortality rate of about 30%.[7] Yang et al (n=753) reported that the median age of patients with MOE is the sixth to seventh decade, predominantly in males.[8]

The non-classical MOE phenotype may be observed in younger, non-elderly individuals without diabetes mellitus if they are in an immunosuppressed state, such as haematological malignancy, HIV infection, those receiving chemotherapy, or post organ transplant patients. Of these, the association between MOE and diabetes mellitus is among the most robust of all etiologies. In an African systematic review by Azeez and Adeagbo (n=848) diabetes mellitus was reported in 94% of cases, with a pooled HbA1c of 9.8%.[9] In the European series by Peled et al (n=89) diabetes mellitus was prevalent in 94.3% and a mean admission HbA1c of 8.13% was documented.[10] Peled et al reported that HbA1c at admission was a significant independent predictor of hospitalisation duration with patients with HbA1c $\geq$ 8% having hospitalisations exceeding 20 days thereby proving that glycaemic control is not merely a predisposing factor but a modifier of disease severity.[10]

Hyperglycaemia results in micro-angiopathy impairing external auditory canal (EAC) perfusion; causes suppression of neutrophil chemotaxis, phagocytosis, and oxidative burst; increased microbial adhesion, elevation of ceruminal pH occurs creating a predisposing milieu for invasion of Pseudomonas aeruginosa through the fissures of Santorini.[11] Pseudomonas aeruginosa is the predominant causative pathogen in MOE since Chandler's original description.[5] Hobson et al reported non-Pseudomonal pathogens, including Staphylococcus aureus and Aspergillus species, particularly in non-diabetic immunocompromised patients.[12] Fungal MOE, although uncommon carries a risk of higher mortality, more frequent intracranial extension, and warrants systemic antifungal therapy rather than antipseudomonal antibiotics alone.[13]

The evaluation of a patient with malignant otitis externa includes fasting blood sugar (FBS), post prandial blood sugar (PPBS), HbA1c, ESR, CRP, ear discharge staining and culture, HRCT of the temporal bone and tissue biopsy from the EAC floor when indicated. MRI scans or gallium scans may be necessary in patients with extensive involvement. Tabashiri et al (2025) reported that elevated ESR was significantly associated with higher mortality ($p=0.015$), while elevated CRP correlated with higher disease relapse rates ($p=0.049$); hence baseline and serial ESR and CRP monitoring throughout the course of MOE treatment is recommended for prognosis.[14] High-resolution CT of the temporal bone (HRCT) is the first-line imaging investigation for identifying bony cortical erosion, soft-tissue extension and mastoid involvement. However, CT cannot detect early inflammatory change before bony destruction occurs. MRI offers superior soft-tissue resolution for assessing soft tissue, dural involvement and intracranial extension.[3] Nuclear imaging - Tc-99m bone scintigraphy for diagnosis and Gallium-67 scanning for treatment response monitoring have sensitivities approaching 100% for detection of bony osteomyelitis.[3] The Gallium scan shows increased accumulation in the affected areas, indicating a soft tissue infection and disease progression and helps in monitoring the response to treatment.

Facial nerve palsy is the most common complication of MOE, due to involvement of the facial nerve at the stylomastoid foramen. Chandler reported a 32% incidence of facial paralysis.[5] More recent series report lower rates Krawiec et al documented facial palsy in 13% of 39 patients, Zonnour et al found cranial nerve involvement in 27.7% of 119 patients, with the facial nerve specifically affected in 26.1%.[15,16] Stern Shavit et al. reported that facial nerve palsy is an independent predictor of poor clinical outcomes.[17]

Rapid diagnosis and treatment are vital to managing MOE. Progression of MOE to involve cranial nerves IX–XII at the jugular foramen (jugular foramen syndrome) is a major adverse prognostic indicator of advanced skull base osteomyelitis with potential intracranial extension. Meningitis is the most dreaded intracranial complication of MOE with a high mortality risk. Management of MOE consists of administering antipseudomonal antibiotics and strict glycemic control, while surgery should be considered in special situations. The typical duration of intravenous antipseudomonal antibiotic treatment for MOE is at least 4–6 weeks.[18] Maintenance with oral quinolones is done until inflammatory markers and nuclear imaging normalise. Systemic antifungal coverage may be necessary in a select group of patients.

A multidisciplinary team should include an otolaryngologist–head and neck surgeon, endocrinologist, infectious disease physician, radiologist (with nuclear medicine access), and microbiologist. Surgery is generally done in resistant disease, presence of severe unrelenting pain, detection of sequestration on HRCT and in the presence of any complications. Central or Atypical SBO is a serious, potentially life-threatening condition if not recognized early and treated. Life-threatening complications of MOE include cranial neuropathy, cavernous sinus thrombosis, meningeal and brain parenchymal involvement. A high index of suspicion is essential to diagnose MOE and any elderly, diabetic / immunocompromised patient presenting with severe otalgia, discharging ear, headache and neural symptoms should be considered to have SBO unless proved otherwise and treated urgently to improve outcomes.

Recurrence typically manifests within 6–12 months of completion of initial treatment and generally correlates with failure to achieve HbA1c control at discharge. As per the 2024 COSNOE Delphi consensus study by Lodhi et al., standardised diagnostic criteria and outcome measurement frameworks for MOE have been established.[19] Post-treatment surveillance includes clinical examination, serial ESR / CRP measurements, and Gallium-67 scintigraphy (if indicated) for at least 12 months.

Rhino-orbito-cerebral mucormycosis (ROCM)

This is a dreaded opportunistic infection with angiotropic fungus of the mucorales species. The order Mucorales include Rhizopus, Mucor, Rhizomucor, Absidia, Apophysomyces, Saksenaea, Cunninghamella, Syncephalastrum, and Cokeromyces.[20] The infection is associated with a high morbidity and mortality (approximately 50%). Neutrophils, Natural Killer (NK) cells and T cells play a key role in the host defence against Mucormycosis. Predisposing factors include uncontrolled diabetes, long-term corticosteroid therapy, chemotherapy, neutropenia, chronic renal failure, hematological malignancy, organ transplant recipients on immunosuppressants esp. renal transplantees. About 50%–75% of cases of ROCM have been known to occur in patients with DM. The clinical presentation includes fever, headache, nausea, generalized weakness, nasal discharge which is either purulent, blackish or blood stained, nasal block, pain or numbness over the

face/cheek, facial swelling, black eschar in the nasal cavity, periorbital or retro-orbital pain, loosening of teeth, blurring of vision, double vision, orbital swelling, altered sensorium, unstable gait, seizures and stroke.[21] Diabetic ketoacidosis is the most likely predisposing factor, although it is present in only 50% of the patients with DM who have mucormycosis.[22] It is an aggressive infection characterized by infarction, tissue necrosis with vascular invasion which is the hallmark. Mucor is an angiotropic fungus and the crucial step for angioinvasion is penetration of and damage to the endothelial cells and extracellular matrix proteins lining the blood vessels. The receptor known to be involved in the penetration process is glucose-regulated protein (GRP78). The nasal turbinates are the initial site of infection, with the pterygopalatine fossa being the largest reservoir of infection.[23] An acute episode of sinusitis progresses into pansinusitis rapidly within days and spreads to the palate, orbit, and brain. The four stages of mucormycosis are - Stage 1–Nasal, Stage 2–Sinuses, Stage 3–Orbital and Stage 4–Cerebral involvement. Necrosis of the nasal mucosa and anaesthesia of the nasal mucosa or cheeks is the characteristic finding. Diagnostic nasal endoscopy and CT/MRI scans are necessary. Biopsy, KOH mount and culture help to confirm the diagnosis of mucormycosis. Histopathology reveals broad non or pauci-septate fungal hyphae with tissue invasion. Polymerase chain reaction (PCR) based molecular identification can detect fungal DNA in serum and paraffin-embedded tissues. Early diagnosis and treatment of Mucormycosis in patients with DM is mandatory to limit invasion of the fungus into the orbit and cranial cavity and the resulting morbidity and mortality. Antifungals are the mainstay of treatment along with surgical debridement and strict glycemic control. Liposomal amphotericin therapy (5 mg/kg per day up to a maximum of 10 mg/kg/day for CNS infections to a total of 3 grams) is recommended. Irrigation of sinuses with amphotericin B (1 mg/ ml) is recommended for all patients. Oral Posaconazole / Isavuconazole as step-down or salvage therapy are also effective against mucor and indicated in patients who have renal impairment, cannot tolerate Amphotericin and selected cases of cerebral mucor.

Immediate wide surgical debridement is required in most patients; surgery depends upon the extent of the disease and includes endoscopic sinus debridement with or without maxillectomy (partial/total), clearance of the pterygopalatine fossa, infratemporal fossa, orbital decompression or orbital exenteration depending on the extent of disease. Orbital mucormycosis clearance is important because the orbit is a gateway for the spread of fungi intracranially via the superior orbital fissure and the optic canals.[7]

Orbital exenteration is considered for an actively inflamed orbit with a painful, blind, immobile eye and the opinion of at least two ophthalmologists is mandatory prior to exenteration. The goals of surgery include reduction of disease burden, better penetration of drugs, limitation of further spread of the disease, and to obtain material for histopathological and microbiological confirmation of mucor. If untreated, the disease is fatal, but aggressive surgery and treatment with liposomal amphotericin B can lower the mortality rate. The current survival of patients without brain involvement can be up to 50%-80% but the survival drops to 20% with brain involvement.

There was a surge in mucormycosis cases linked to the second wave of COVID-19 infection due to the Delta variant mostly due to uncontrolled diabetic status in patients managed with steroids.[23] Ketoacidosis, hyperglycemia, hypoxia and tissue rich in iron were excellent growth conditions for mucor. Long-term monitoring of patients was essential as many patients presented with a chronic invasive form after recovering from the acute stage of mucormycosis which emerged as an epidemic within the COVID pandemic in India. Effective management of Mucormycosis necessitates a multidisciplinary team approach comprising of otorhinolaryngology, microbiology, pathology, radiology, ophthalmology, neurosurgery and critical care.

Deep neck space infections (DNSI)

Odontogenic infections and upper airway infections are usually the two important causes of deep neck infection (DNI) in ENT practice.[24] Diabetes mellitus is the most common comorbidity and predisposing factor in patients with DNI because hyperglycemia impairs bactericidal functions of neutrophils, cellular immunity, and complement activation. In the study by Sharma et al, DNSI patients with diabetes were reported to have a more severe clinical course, more frequent complications and a longer duration of hospitalization.[25] Pain, dysphagia, odynophagia and neck swelling are the commonest clinical features. Organisms implicated in neck abscess include *Staphylococcus aureus, Streptococcus*, *Klebsiella, Pseudomonous, E. coli, anerobes,* etc. *Klebsiell*a pneumoniae has been reported to be the commonest aerobic organism and *Peptostreptococcus* the frequent anaerobe in DNSI. Serious fatal complications such as airway obstruction, pneumonia, lung abscess, mediastinitis, pericarditis can ensue. Cavernous sinus thrombosis has been reported in patients with parapharyngeal abscess. Spread of parapharyngeal or retropharyngeal space infection into the mediastinumcan occur via the carotid sheath (Lincoln Highway).[26]

Parapharyngeal abscess causing neck swelling, fever, throat pain, trismus and dysphagia is diagnosed by oropharyngeal examination which reveals medial displacement of the tonsil and lateral pharyngeal wall. CT scans are done to confirm the diagnosis and extent of the infection. In a study comparing deep neck infections in non-diabetics vs diabetics, diabetics were reported to have older mean age (57.2 y versus 46.2 y), longer duration of hospital stay (19.7 days versus 10.2 days),

more frequent complications (33.9% versus 8.5%), and more frequent tracheostomy or intubation (19.6% versus 6.2%).[24] Ludwig's angina is a rapidly progressing polymicrobial cellulitis of the sublingual and submandibular spaces especially common in diabetic patients. This infection usually originates from molar and premolar teeth root infections. It is a serious, potentially life -threatening infection of the neck and the floor of the mouth which can cause life-threatening airway compromise. Retropharyngeal abscess occurs in the space anterior to the prevertebral space and posterior to the pharynx causing pain, dysphagia, fever and occasionally, dyspnea. Mediastinitis is a recognized dreaded complication.

Deep neck infections need aggressive treatment which includes early incision and drainage of abscess, prompt empirical antibiotic administration, intensive blood glucose regulation and dental surgery to eradicate the source of infection if needed.

Awareness of the management of the dreaded ENT complications of DM is especially relevant in India owing to the high incidence of diabetes mellitus.

Diabetes mellitus is a complex, progressive, and multifactorial metabolic disorder which has proved to be a major public health burden. The development of novel drugs for the management of diabetes is ongoing. Besides glycemic control, multifactorial interventions including nanotechnology, gene therapy, stem cell therapy, medical nutrition therapy, and lifestyle modification will result in improved management of diabetes mellitus and its complications.

Limitations

This study has certain limitations. It is a retrospective, single-centre study, which may limit generalizability of the findings. Long-term follow-up data were not available for all patients, particularly in the deep neck space infection cohort (mean follow-up-3 months). Multi-centric, prospective studies with longer follow-up are needed to validate these findings and further improve management protocols for these conditions.

CONCLUSION

Several ENT manifestations and complications can occur in diabetes mellitus, usually related to the duration and severity of diabetes mellitus and the extent of glycemic control. Infections such as malignant otitis externa, invasive fungal sinusitis and deep space neck infections can be severe and life threatening in patients with diabetes mellitus if not treated early. Hence timely diagnosis and intervention, together with stringent diabetic control is crucial.

Funding: No funding sources
Conflict of Interest: None declared
Ethical approval: The study was approved by the Institutional Ethics Committee

REFERENCES

1. Aloke C, Egwu CO, Aja PM, Obasi NA, Chukwu J, Akumadu BO, et al. Current advances in the management of diabetes mellitus. Biomedicines. 2022;10(10):2436.
2. Jain A, Narve VP. A clinical study of ENT manifestations in diabetes mellitus patients. J Cardiovasc Dis Res. 2023;14(1):77-81.
3. Rajyalakshmi R, Athaluri SA, Arava DR, Pyla KR, Manthena SV. Unexpected discrepancies in the histopathological and microbiological diagnoses of suspected mucormycosis cases at a South Indian tertiary care center during the COVID-19 pandemic. Cureus. 2024;16(12):e75478.
4. Zhou Z, Wang H, Tan S, Zhang H, Zhu Y. The alterations of innate immunity and enhanced severity of infections in diabetes mellitus. Immunology. 2024;171(3):313-23.
5. Chandler JR. Malignant external otitis. Laryngoscope. 1968;78(8):1257-94.
6. Rubin Grandis J, Branstetter BF 4th, Yu VL. The changing face of malignant (necrotising) external otitis: clinical, radiological, and anatomic correlations. Lancet Infect Dis. 2004;4(1):34-9.
7. Rajagopalan S. Serious infections in elderly patients with diabetes mellitus. Clin Infect Dis. 2005;40(7):990-6.
8. Yang TH, Xirasagar S, Cheng YF, Wu CS, Kao YW, Shia BC, et al. Malignant otitis externa is associated with diabetes: a population-based case-control study. Ann Otol Rhinol Laryngol. 2020;129(6):585-90.
9. Azeez TA, Adeagbo AK. The association between malignant otitis externa and diabetes mellitus in Africa: a systematic review. Indian J Otolaryngol Head Neck Surg. 2023;75(4):3277-87.
10. Peled C, Sadeh R, El-Saied S, Novack V, Kaplan DM. Diabetes and glycemic control in necrotizing otitis externa (NOE). Eur Arch Otorhinolaryngol. 2022;279(3):1269-75.
11. Tsilivigkos C, Avramidis K, Ferekidis E, Doupis J. Malignant external otitis: what the diabetes specialist should know-a narrative review. Diabetes Ther. 2023;14(4):629-38.
12. Hobson CE, Moy JD, Byers KE, Raz Y, Hirsch BE, McCall AA. Malignant otitis externa: evolving pathogens and implications for diagnosis and treatment. Otolaryngol Head Neck Surg. 2014;151(1):112-6.
13. Treviño González JL, Reyes Suárez LL, Hernández de León JE. Malignant otitis externa: an updated review. Am J Otolaryngol. 2021;42(2):102894.
14. Tabashiri A, Allahverdi Nazhand H, Fathy M, Mortazavi SM, Javandoust Gharehbagh F, Haghighi-Morad M, et al. Evaluation of the clinical and radiological features of patients with malignant

otitis externa (MOE). BMC Infect Dis. 2025;25(1):277.
15. Krawiec E, Brenet E, Truong F, Nguyen Y, Papthanassiou D, Labrousse M, et al. Epidemiology and risk factors for extension of necrotizing otitis externa. Eur Arch Otorhinolaryngol. 2024;281(5):2383-2394.
16. Zonnour A, Shahnazar R, Jamshidi A, Dabiri S, Saedi E, Emami H, et al. Cranial nerve palsy prevalence and associated factors in patients with malignant otitis externa. Laryngoscope Investig Otolaryngol. 2023;8(2):538-45.
17. Stern Shavit S, Soudry E, Hamzany Y, Nageris B. Malignant external otitis: factors predicting patient outcomes. Am J Otolaryngol. 2016;37(5):425-30.
18. Arsovic N, Radivojevic N, Jesic S, Babac S, Cvorovic L, Dudvarski Z. Malignant otitis externa: causes for various treatment responses. J Int Adv Otol. 2020;16(1):98-103.
19. Lodhi S, Dodgson K, Dykes M, Vishwanath V, Bazaz R, Mathur S, et al. Diagnostic criteria and core outcome set development for necrotising otitis externa: the COSNOE Delphi consensus study. J Laryngol Otol. 2024;138(9):913-20.
20. Szalai G, Fellegi V, Szabó Z, Vitéz LC. Mucormycosis mimics sinusitis in a diabetic adult. Ann N Y Acad Sci. 2006;1084:520-30.
21. Bhanuprasad K, Manesh A, Devasagayam E, Varghese L, Cherian LM, Kurien R, et al. Risk factors associated with the mucormycosis epidemic during the COVID-19 pandemic. Int J Infect Dis. 2021;111:267-70.
22. Sukaina M. Re-emergence of mucormycosis in COVID-19 recovered patients transiting from silent threat to an epidemic in India. J Glob Health Rep. 2021;5:e2021067.
23. John TM, Jacob CN, Kontoyiannis DP. When uncontrolled diabetes mellitus and severe COVID-19 converge: the perfect storm for mucormycosis. J Fungi (Basel). 2021;7(4):298.
24. Huang TT, Tseng FY, Liu TC, Hsu CJ, Chen YS. Deep neck infection in diabetic patients: comparison of clinical picture and outcomes with nondiabetic patients. Otolaryngol Head Neck Surg. 2005;132(6):943-7.
25. Sharma K, Das D, Joshi M, Barman D, Sarma AJ. Deep neck space infections—a study in diabetic population in a tertiary care centre. Indian J Otolaryngol Head Neck Surg. 2018;70(1):22-7.
26. Jami AA, Alom K, Pervin Nice N. Clinico-pathological study of neck abscess in diabetic patients. The Insight. 2024;7(1):205-14.

Cite this article as: Kumar N, Natarajan K, Pyrbot KS, Parvathi, Raghunandhan S, Kameswaran M. Dreaded ENT diseases in patients with diabetes mellitus: challenges in management. Int J Otorhinolaryngol Head Neck Surg 2026;12:888-95.