International Journal of Otorhinolaryngology and Head and Neck Surgery
Hussain AA et al. Int J Otorhinolaryngol Head Neck Surg. 2026 Dec;12(6):1031-1036
https://www.ijorl.com
pISSN 2454-5929 | eISSN 2454-5937

DOI: https://dx.doi.org/10.18203/issn.2454-5929.ijohns20264288

Case Report

Diagnostic dilemma in a unilateral maxillary sinus mass – from fungal sinusitis to EBER-positive plasma cell neoplasm: a case report

Ayesha Ather Hussain[1]*, Shyam Gade[2]

[1]MS ENT, Shadan Institute of Medical Sciences, Hyderabad, Telangana
[2]Head of the department, Professor Department of ENT, Head & Neck Surgery, Mahavir Hospital & Research Centre, Hyderabad, Telangana, India

Received: 19 September 2026
Accepted: 26 September 2026

***Correspondence:**
Dr. Ayesha Ather Hussain,
E-mail: ayesha_ather@outlook.com

Copyright: © the author(s), publisher and licensee Medip Academy. This is an open-access article distributed under the terms of the Creative Commons Attribution Non-Commercial License, which permits unrestricted non-commercial use, distribution, and reproduction in any medium, provided the original work is properly cited.

ABSTRACT

Persistent unilateral sinonasal symptoms warrant careful evaluation as inflammatory or fungal sinus disease may occasionally mask underlying malignancy. Distinguishing sinonasal plasmacytoma from plasmablastic lymphoma (PBL) remains particularly challenging because of overlapping histomorphological and immunohistochemical features.

A 50-year-old male presented with progressive right-sided nasal obstruction, facial pain, cheek numbness, and upper jaw discomfort initially managed as fungal sinusitis. Functional endoscopic sinus surgery (FESS) with biopsy revealed a plasma cell neoplasm with diagnostic uncertainty between plasmacytoma and plasmablastic lymphoma. Histopathological review across multiple tertiary centres demonstrated CD138 positivity, kappa light chain restriction, EBER positivity, and absence of c-MYC rearrangement on fluorescence in situ hybridization (FISH). Integrated clinicopathological correlation ultimately favoured an EBER-positive plasmacytoma/plasma cell neoplasm over plasmablastic lymphoma.

This case highlights the importance of early biopsy in unilateral sinonasal disease and demonstrates the critical role of multidisciplinary review, EBER studies, and MYC analysis in differentiating sinonasal plasma cell neoplasms from plasmablastic lymphoma. ENT surgeons should maintain a high index of suspicion in atypical or treatment-refractory maxillary sinus disease.

Keywords: Plasmacytoma, Plasmablastic lymphoma, Maxillary sinus neoplasm, Fungal sinusitis, EBER

INTRODUCTION

Unilateral sinonasal symptoms associated with facial pain, dental complaints, or persistent nasal obstruction require careful evaluation because neoplastic lesions may mimic inflammatory or infective conditions. Fungal sinusitis, chronic rhinosinusitis, and plasma cell neoplasms may present with overlapping clinical and radiological findings, leading to diagnostic delay. Extramedullary plasmacytoma (EMP) involving the maxillary sinus is uncommon and may pose considerable diagnostic difficulty, particularly when histological features overlap with plasmablastic lymphoma (PBL).[1]

Plasmablastic lymphoma is an aggressive Epstein–Barr virus (EBV)-associated lymphoma commonly encountered in immunocompromised individuals and characterized by plasmacytic differentiation.[2] However, differentiating PBL from plasmacytoma is challenging because both entities may express plasma cell markers such as CD138 and MUM1 while lacking conventional B-cell markers.[3] Ancillary investigations including EBER in situ hybridization (ISH), MYC rearrangement analysis, clinical staging, and multidisciplinary pathological review are often essential for accurate diagnosis.[4]

We report a diagnostically challenging case of unilateral maxillary sinus mass initially treated as fungal sinusitis and subsequently identified as an EBER-positive plasma cell neoplasm with differential consideration of plasmablastic lymphoma. The case emphasizes the importance of repeated histopathological review and integrated clinicopathological correlation in atypical sinonasal lesions.

CASE REPORT

A 50-year-old male presented to the ENT outpatient department with progressive right-sided nasal obstruction, facial pain, cheek numbness, upper jaw discomfort, and dental pain of approximately three months duration. The patient also complained of pain radiating to the right upper teeth and infraorbital region. He was a known case of type 2 Diabetes Mellitus, Hypertension, and Obesity.

Initial nasal endoscopy demonstrated right-sided sinonasal disease involving the maxillary sinus. Contrast-enhanced CT of the paranasal sinuses demonstrated a heterogeneously enhancing right maxillary sinus mass with superior, medial, and anterior extension associated with bony erosion (Figure 1). KOH mount and microbiological evaluation revealed fungal elements suggestive of fungal sinusitis. The patient was initially managed conservatively with antifungal therapy including itraconazole, amphotericin nasal douching, topical steroid nasal sprays, saline irrigation, antihistamines, and antibiotics (Table 1). Despite medical management, symptoms persisted with progressive facial numbness and maxillary discomfort

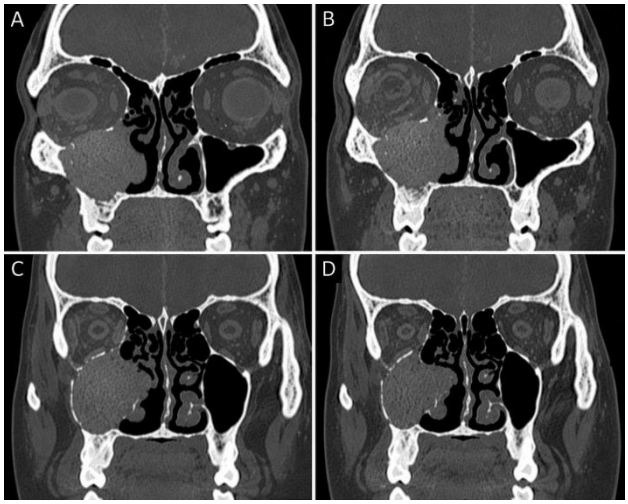

Figure 1: Pre-operative contrast-enhanced coronal computed tomography (CT) images of the paranasal sinuses. Panels A–D demonstrate a heterogeneously enhancing soft tissue mass occupying the right maxillary sinus. The lesion shows superior extension toward the orbital floor, medial extension into the nasal cavity, and anterior extension with associated bony erosion of the maxillary sinus walls. Sequential coronal sections illustrate the extent of local disease and its relationship to adjacent sinonasal structures.

Table 1: Diagnostic evolution and multidisciplinary review timeline in a patient with unilateral maxillary sinus plasma cell neoplasm.

Timeline/Stage	Clinical Findings and Management	Diagnostic Interpretation
Initial presentation	Right-sided nasal obstruction, facial pain, upper jaw discomfort, cheek numbness, dental pain	Chronic unilateral sinonasal disease
Initial ENT evaluation	Diagnostic nasal endoscopy and medical therapy initiated	Suspected fungal sinusitis/chronic rhinosinusitis
Microbiological evaluation	KOH smear positive for fungal elements from right maxillary sinus	Fungal sinusitis considered
Initial medical management	Itraconazole, amphotericin nasal douching, topical steroid sprays, saline irrigation, antibiotics	Persistent symptoms despite therapy
Surgical intervention	Functional endoscopic sinus surgery (FESS) with biopsy of right maxillary sinus lesion	Tissue diagnosis performed
Initial histopathology	Plasmacytoid atypical cells with eccentric nuclei and eosinophilic cytoplasm	Differential diagnosis: plasmablastic lymphoma vs plasma cell neoplasm
Immunohistochemistry	CD138+, CD38+, MUM1+, CD56+, kappa restricted, CD20−, PAX5−, Ki-67 ~40–50%	Plasma cell lineage confirmed
EBER-ISH study	Positive for Epstein–Barr virus encoded RNA	Raised suspicion for plasmablastic lymphoma

Continued.

Timeline/Stage	Clinical Findings and Management	Diagnostic Interpretation
External pathology review (Apollo Hospitals)	Review favoured plasmablastic lymphoma	Diagnostic uncertainty persisted
Secondary/tertiary reviews (Yashoda and Basavatarakam Cancer Hospital)	Correlation with morphology and immunophenotype	Plasma cell neoplasm/plasmacytoma favoured
FISH analysis for c-MYC	Negative for c-MYC rearrangement	Supported diagnosis against plasmablastic lymphoma
PET-CT imaging	Metabolically active right maxillary sinus lesion without disseminated disease	Localized sinonasal plasma cell neoplasm
Final integrated diagnosis	Multidisciplinary ENT–pathology–haematology correlation	EBER-positive plasmacytoma/plasma cell neoplasm

Subsequently, Functional Endoscopic Sinus Surgery (FESS) with biopsy of the right maxillary sinus lesion was performed. Histopathological examination demonstrated sheets of atypical plasmacytoid cells with eccentric nuclei and eosinophilic cytoplasm. Initial pathological review raised suspicion for plasmablastic lymphoma versus plasma cell neoplasm.

Immunohistochemistry (IHC) demonstrated positivity for CD138, CD56, MUM1, CD38, and kappa light chain restriction, while CD20 and PAX5 were negative. Ki-67 proliferation index was approximately 40–50% (Table 2).

Table 2: Histopathological and immunohistochemical features contributing to the differential diagnosis between plasmablastic lymphoma and plasmacytoma in the present case.

Parameters	Findings in present case	Significance
Site of lesion	Right maxillary sinus	Uncommon site for plasma cell neoplasm
Histopathology	Sheets/trabeculae of atypical plasmacytoid cells with eccentric nuclei and eosinophilic cytoplasm	Overlapping morphology between plasmacytoma and plasmablastic lymphoma
CD138	Positive	Plasma cell differentiation
CD38	Positive	Plasma cell phenotype
MUM1	Positive	Supports plasmacytic differentiation
CD56	Positive	Frequently expressed in plasma cell neoplasms
Kappa light chain	Positive	Monoclonal plasma cell proliferation
Lambda light chain	Negative	Light chain restriction
CD20	Negative	Loss of mature B-cell phenotype
PAX5	Negative	Supports plasmacytic differentiation
EBER-ISH	Positive	Seen in plasmablastic lymphoma but may occur in plasmacytoma
Ki-67 proliferation index	Approximately 40–50%	Intermediate proliferative activity
c-MYC rearrangement by FISH	Negative	Against plasmablastic lymphoma
PET-CT findings	Localized metabolically active sinonasal lesion without disseminated disease	Favored localized plasma cell neoplasm
Final integrated diagnosis	EBER-positive plasmacytoma/plasma cell neoplasm	Based on multidisciplinary clinicopathological correlation

Representative histopathological, immunohistochemical, EBER-ISH, and FISH findings are shown in Figure 2. EBER by ISH was positive. Owing to the diagnostic uncertainty, slides and paraffin blocks underwent review at multiple tertiary centres including Apollo Hospitals, Yashoda Hospitals, and Basavatarakam Indo-American Cancer Hospital.

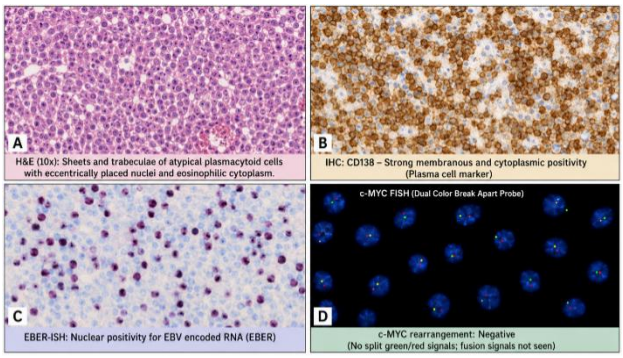

Figure 2: Histopathology and immunohistochemistry panel of the right maxillary sinus lesion (A) Hematoxylin and eosin (H&E) stained section showing sheets and trabeculae of atypical plasmacytoid cells with eccentrically placed nuclei and abundant eosinophilic cytoplasm involving the right maxillary sinus lesion; (B) Immunohistochemistry demonstrating strong membranous and cytoplasmic positivity for CD138, confirming plasma cell differentiation; (C) Epstein–Barr virus encoded RNA (EBER) in situ hybridization (EBER-ISH) demonstrating nuclear positivity within tumour cells; (D) Fluorescence in situ hybridization (FISH) analysis negative for c-MYC gene rearrangement, without evidence of split red/green signals.

Overall findings supported the diagnosis of an EBER-positive plasma cell neoplasm/plasmacytoma and argued against plasmablastic lymphoma in correlation with clinicopathological and molecular features.

One review favoured plasmablastic lymphoma because of EBER positivity and plasmablastic morphology. However, subsequent expert review noted absence of c-MYC expression and preserved plasma cell phenotype favouring plasmacytoma/plasma cell neoplasm. Fluorescence in situ hybridization (FISH) analysis was negative for c-MYC gene rearrangement. Integrated pathological correlation ultimately favoured an EBER-positive plasma cell neoplasm/plasmacytoma over plasmablastic lymphoma.

Positron emission tomography-computed tomography (PET-CT) demonstrated metabolically active disease localized predominantly to the right maxillary sinus region without evidence of disseminated systemic disease. Haematology and oncology evaluation was subsequently undertaken for definitive management planning.

Post-treatment FDG PET-CT demonstrated non-FDG-avid postoperative thickening along the lateral wall of the right maxilla without evidence of metabolically active residual disease. A minimally FDG-avid right level II cervical lymph node (SUVmax 2.35) was considered inflammatory. No distant metabolically active lesions were identified (Figure 3).

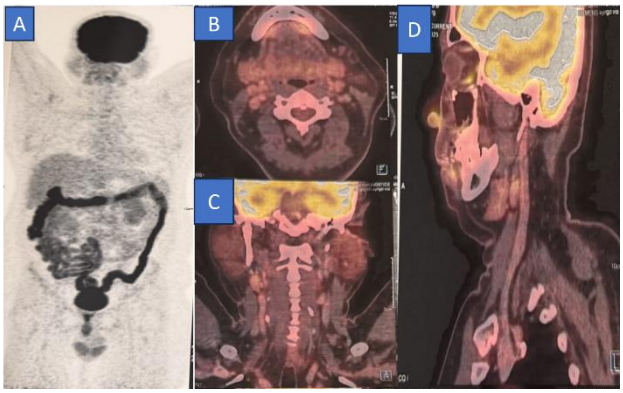

Figure 3: Postoperative FDG PET-CT Imaging Following Functional Endoscopic Sinus Surgery (FESS) (A) Whole-body maximum intensity projection (MIP) image demonstrating no evidence of disseminated FDG-avid disease; (B) Axial fused PET-CT image at the level of the neck showing a minimally FDG-avid right level II cervical lymph node; (C) Coronal fused PET-CT image demonstrating postoperative changes involving the right maxillary region without significant residual FDG uptake; (D) Sagittal CT image showing postoperative soft tissue thickening along the lateral wall of the right maxilla. PET-CT revealed non-FDG-avid postoperative thickening at the primary site and a minimally FDG-avid right level II cervical lymph node (SUVmax 2.35), considered inflammatory, with no evidence of distant metabolically active disease.

DISCUSSION

EMP is an uncommon plasma cell neoplasm accounting for approximately 3–5% of all plasma cell dyscrasias, with nearly 80% of cases arising in the upper aerodigestive tract, particularly the nasal cavity, paranasal sinuses, nasopharynx, and oropharynx. Despite its predilection for the head and neck region, diagnosis remains challenging because of its rarity, nonspecific clinical presentation, and considerable overlap with inflammatory, infectious, and lymphoid neoplasms. Furthermore, EBV-associated plasma cell neoplasms represent an uncommon subset of these lesions and may demonstrate morphologic and immunophenotypic features overlapping with plasmablastic lymphoma, necessitating comprehensive pathological evaluation including immunohistochemistry, EBER in situ hybridization, and molecular studies for accurate classification.[5-9]

Sinonasal EMPs commonly present with unilateral nasal obstruction, facial pain, epistaxis, cheek swelling, dental symptoms, rhinorrhoea, or radiological features suggestive of chronic rhinosinusitis and fungal sinus disease. Consequently, delays in diagnosis are not uncommon, particularly when initial clinical or microbiological findings favour an infective aetiology. In the present case, the identification of fungal elements on KOH examination together with the patient's diabetic

status initially supported a diagnosis of fungal sinusitis. However, persistent symptoms despite appropriate management prompted repeat tissue sampling and a more extensive pathological workup, ultimately demonstrating an EBER-positive plasma cell neoplasm. This case highlights the importance of maintaining a high index of suspicion for underlying neoplasia in patients with unilateral sinonasal disease showing atypical clinical behaviour or failure to respond to conventional treatment.[10-13]

Extramedullary plasmacytoma involving the sinonasal tract is rare, accounting for a small proportion of plasma cell neoplasms.[14] The upper aerodigestive tract is the most common site of involvement, with the nasal cavity and paranasal sinuses frequently affected.[15] Patients typically present with nonspecific symptoms such as nasal obstruction, epistaxis, facial pain, rhinorrhoea, or dental complaints, making early diagnosis difficult.

The present case is clinically important because the lesion initially mimicked fungal sinusitis. Positive fungal smear findings and radiological sinonasal involvement initially supported an infective aetiology. However, persistence of unilateral symptoms despite therapy prompted surgical biopsy, ultimately revealing an underlying plasma cell neoplasm. This highlights an important teaching point for otolaryngologists: persistent unilateral sinonasal disease with facial numbness or dental symptoms should always raise suspicion for malignancy and warrants histopathological evaluation.

The principal diagnostic challenge in this case was differentiation between plasmablastic lymphoma and plasmacytoma. Both lesions can exhibit plasmablastic morphology, CD138 positivity, and loss of conventional B-cell markers.[16] EBER positivity further complicated interpretation because it is strongly associated with plasmablastic lymphoma. Nevertheless, EBER-positive plasmacytomas have also been described in the literature.[17]

MYC rearrangement testing played a crucial role in narrowing the diagnosis. MYC abnormalities are commonly associated with plasmablastic lymphoma and correlate with aggressive clinical behaviour.[18] In the present case, absence of MYC rearrangement on FISH, combined with clinicoradiological findings and plasma cell immunophenotype, favoured plasmacytoma/plasma cell neoplasm over plasmablastic lymphoma.

Another noteworthy aspect was the requirement for repeated tertiary pathology review. Sinonasal plasma cell lesions are uncommon, and diagnosis may vary between centres because of overlapping histological and immunophenotypic features. Multidisciplinary collaboration among ENT surgeons, pathologists, haematologists, radiologists, and oncologists was essential in reaching a clinically meaningful diagnosis.

The diagnosis in the present case was established through a comprehensive multidisciplinary approach incorporating clinical assessment, radiological evaluation, histopathology, immunohistochemistry, EBER in situ hybridization, and MYC rearrangement testing. Correlation of findings from these complementary diagnostic modalities was essential in distinguishing an EBER-positive plasma cell neoplasm from other morphologically similar entities, particularly plasmablastic lymphoma. Following definitive diagnosis, the patient was referred for specialist oncological management and demonstrated a favourable clinical response. This case highlights the value of coordinated multidisciplinary care in achieving accurate diagnosis and appropriate treatment of rare sinonasal plasma cell neoplasms.

This case reinforces the importance of integrating histopathology with radiological findings, immunohistochemistry, molecular studies, and clinical presentation rather than relying on a single pathological parameter.

CONCLUSION

To the best of our knowledge, this is the first reported case of an EBER-positive plasma cell neoplasm involving the maxillary sinus from the Telangana region. Sinonasal plasma cell neoplasms may clinically and radiologically mimic fungal sinusitis and other inflammatory conditions, leading to diagnostic delay. Persistent unilateral maxillary sinus disease associated with facial numbness, dental symptoms, or poor response to medical therapy should prompt early biopsy and multidisciplinary evaluation. EBER positivity alone should not lead to a diagnosis of plasmablastic lymphoma, and ancillary molecular studies such as MYC rearrangement testing are critical in diagnostically challenging cases. Early recognition and integrated clinicopathological assessment are essential for accurate diagnosis and optimal management.

Funding: No funding sources
Conflict of interest: None declared
Ethical approval: Not required

REFERENCES

1. Holler A, Cicha I, Eckstein M, Haderlein M, Pöttler M, Rappl A, et al. Extramedullary plasmacytoma: tumor occurrence and therapeutic concepts—a follow-up. Cancer Med. 2022;11(24):4743-55.
2. Castillo JJ, Bibas M, Miranda RN. The biology and treatment of plasmablastic lymphoma. Blood. 2015;125(15):2323-30.
3. Vega F, Chang CC, Medeiros LJ, Udden MM, Cho-Vega JH, Lau CC, et al. Plasmablastic lymphomas and plasmablastic plasma cell myelomas have nearly identical immunophenotypic profiles. Mod Pathol. 2005;18(6):806-15.

4. Loghavi S, Alayed K, Aladily TN, Zuo Z, Ng SB, Tang G, et al. Stage, age, and EBV status impact outcomes of plasmablastic lymphoma patients: a clinicopathologic analysis of 61 patients. J Hematol Oncol. 2015;8:65.
5. Lee DH, Yeom S, Lim SC, Song J. Extramedullary plasmacytoma of the head and neck region in a single institution. J Craniofac Surg. 2025.
6. Holler A, Cicha I, Eckstein M, Haderlein M, Pöttler M, Rappl A, et al. Extramedullary plasmacytoma: tumor occurrence and therapeutic concepts—a follow-up. Cancer Med. 2022;11(24):4743-4755.
7. Galieni P, Cavo M, Pulsoni A, Avvisati G, Bigazzi C, Neri S, et al. Clinical outcome of extramedullary plasmacytoma. Haematologica. 2000;85(1):47-51.
8. Castillo JJ, Bibas M, Miranda RN. The biology and treatment of plasmablastic lymphoma. Blood. 2015;125(15):2323-30.
9. Ahn JS, Okal R, Vos JA, Smolkin M, Kanate AS, Rosado FG. Plasmablastic lymphoma versus plasmablastic myeloma: an ongoing diagnostic dilemma. J Clin Pathol. 2017;70(9):775-80.
10. Kilciksiz S, Karakoyun-Celik O, Agaoglu FY, Haydaroglu A. A review for solitary plasmacytoma of bone and extramedullary plasmacytoma. ScientificWorldJournal. 2012;2012:895765.
11. Bachar G, Goldstein D, Brown D, Tsang R, Lockwood G, Perez-Ordonez B, et al. Solitary extramedullary plasmacytoma of the head and neck—long-term outcome analysis of 68 cases. Head Neck. 2008;30(8):1012-9.
12. Reed V, Shah J, Medeiros LJ, Ha CS, Mazloom A, Weber DM, et al. Solitary plasmacytomas: outcome and prognostic factors after definitive radiation therapy. Cancer. 2011;117(19):4468-74.
13. Strojan P, Soba E, Lamovec J, Munda A. Extramedullary plasmacytoma: clinical and histopathologic study. Int J Radiat Oncol Biol Phys. 2002;53(3):692-701.
14. Susnerwala SS, Shanks JH, Banerjee SS, Scarffe JH, Farrington WT, Slevin NJ. Extramedullary plasmacytoma of the head and neck region: clinicopathological correlation in 25 cases. Br J Cancer. 1997;75(6):921-7.
15. D'Aguillo C, Soni RS, Gordhan C, Liu JK, Baredes S, Eloy JA. Sinonasal extramedullary plasmacytoma: a systematic review of 175 patients. Int Forum Allergy Rhinol. 2014;4(2):156-63.
16. Taddesse-Heath L, Meloni-Ehrig A, Scheerle J, Kelly JC, Jaffe ES. Plasmablastic lymphoma with MYC translocation: evidence for a common pathway in the generation of plasmablastic features. Mod Pathol. 2010;23(7):991-9.
17. Penzhorn IH, Schneider JW, Sher-Locketz C. The prevalence of Epstein-Barr virus in plasma cell neoplasms is higher in HIV-positive individuals. Int J Surg Pathol. 2023;31(5):564-71.
18. Valera A, Balagué O, Colomo L, Martínez A, Delabie J, Taddesse-Heath L, et al. IG/MYC rearrangements are the main cytogenetic alteration in plasmablastic lymphomas. Am J Surg Pathol. 2010;34(11):1686-94.

Cite this article as: Hussain AA, Gade S. Diagnostic dilemma in a unilateral maxillary sinus mass – from fungal sinusitis to EBER-positive plasma cell neoplasm: a case report. Int J Otorhinolaryngol Head Neck Surg 2026;12:1031-6.