International Journal of Otorhinolaryngology and Head and Neck Surgery
Pyrbot KS et al. Int J Otorhinolaryngol Head Neck Surg. 2026 Dec;12(6):1022-1027
https://www.ijorl.com
pISSN 2454-5929 | eISSN 2454-5937

DOI: https://dx.doi.org/10.18203/issn.2454-5929.ijohns20264286

Case Series

Post cochlear implantation meningitis: challenges and outcomes

Kune Saphi Pyrbot*, Roopak Vaidhyswaran, Kiran Natarajan and Mohan Kameswaran

Department of Implantation Otology, Madras ENT Research Foundation, 1, 1st cross street, Off 2nd main road, Raja Annamalaipuram, Chennai, Tamil Nadu, India

Received: 27 May 2026
Revised: 22 September 2026
Accepted: 23 September 2026

***Correspondence:**
Dr. Kune Saphi Pyrbot,
E-mail: drkunesaphi@gmail.com

Copyright: © the author(s), publisher and licensee Medip Academy. This is an open-access article distributed under the terms of the Creative Commons Attribution Non-Commercial License, which permits unrestricted non-commercial use, distribution, and reproduction in any medium, provided the original work is properly cited.

ABSTRACT

Meningitis is a rare but significant complication after Cochlear implantation (CI) owing to the high incidence of morbidity and mortality. Several risk factors for meningitis have been reported, including otitis media, prior meningitis, inner ear malformations, CSF leak, poor surgical technique and lack of appropriate immunization. The aim of this study was to analyse the cause of meningitis, and the outcomes of management. This is a report of three cases of meningitis following cochlear implantation treated at a tertiary ENT centre. After medical management of meningitis, revision surgery was performed which revealed tegmen defect with brain herniation in a thirty-two-year-old lady, CSF leak from the round window in a five-year-old girl with bilateral Incomplete Partition Type II (IP-II) and CSF leak from the round window in a three-year-old boy with Incomplete Partition Type I (IP- I) malformation. All three patients were treated with subtotal petrosectomy with repair of the CSF leak. Re-implantation was done in one patient at the same sitting and scheduled at a later date in another patient. Postoperative follow-up demonstrated favourable outcomes with no recurrence of meningitis and all patients are currently under follow-up. Meningitis after cochlear implantation though rare, remains a significant complication after cochlear implantation. Early diagnosis and timely medical and surgical management are essential to prevent recurrence. Preventive measures such as appropriate vaccination and meticulous surgical technique are crucial in reducing postoperative risk of meningitis.

Keywords: Cochlear Implant, Meningitis, CSF leak, Tegmen defect, Subtotal petrosectomy, Reimplantation

INTRODUCTION

Cochlear implantation (CI) is an effective and safe procedure to restore hearing in severe – profound hearing loss. CI involves opening the cochlea and inserting an electrode array to directly stimulate the cochlear nerve.[1]Although cochlear implantation is considered a safe procedure, the complication rate can reach approximately 12.5%, particularly in children.[2] Meningitis is a rare complication after cochlear implantation, albeit with significant morbidity and mortality. The CI can act as a nidus for infection, facilitating spread of infection.[3] Early detection and management of meningitis is crucial. Subsequently, CT scans can help identify the cause for meningitis followed by revision surgery. This retrospective study includes three patients who developed meningitis following cochlear implantation, managed at a tertiary care centre over a 29 year period (March 1997 - March 2026).

CASE SERIES

This is a retrospective study of three patients who developed meningitis following CI, managed at a tertiary care centre over a 29 year period (March 1997-March 2026). One patient was adult and two were pediatric

patients with age ranging from 3 to 32 years. All three patients who developed meningitis post CI underwent successful medical management of meningitis. Informed consent was taken and all patients underwent revision surgery.

Case 1

A 32-year-old woman was referred to our centre with a history of recurrent meningitis following right-sided cochlear implantation performed at another institution. She was treated for three documented episodes of meningitis following implantation. After successful medical management of meningitis, she was referred to our institution for surgical intervention. The patient had progressive bilateral sensorineural hearing loss, was using hearing aids with limited benefit; she had been counselled regarding the likelihood of limited auditory benefit prior to cochlear implantation which was undertaken primarily to provide environmental sound awareness. High-resolution computed tomography (HRCT) of the temporal bone revealed normal cochlear anatomy, tegmen defect with brain herniation and evidence of infection. In view of the recurrent episodes of meningitis and radiological findings, surgical intervention was planned.



Figure 1: HRCT showing defect in the tegmen with brain herniation & infection in case1.



Figure 2: HRCT showing CI in normal cochlear anatomy in case 1c

The cochlear implant was explanted, the tegmen defect was identified and sealed using a multilayered closure with autologous fat, cartilage, fascia, and fibrin glue. Subtotal petrosectomy was performed to eradicate the source of infection and prevent further cerebrospinal fluid leakage. (Figures 1-4) The patient declined reimplantation following explantation of the device. The patient is under periodic follow - up since 23 months till date and is asymptomatic.

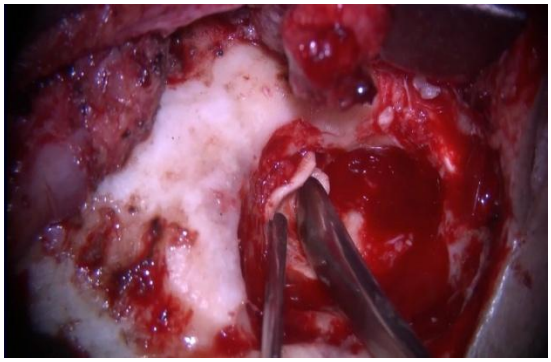

Figure 3: Tragal cartilage sealed over defect in the tegmen in case 1.

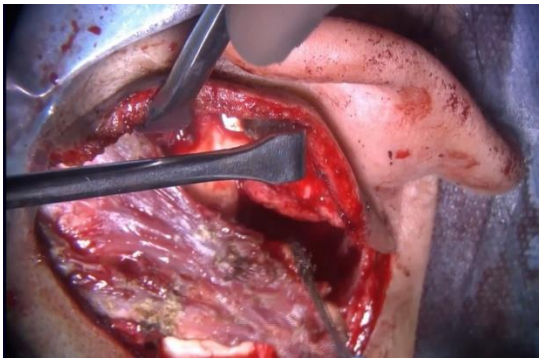

Figure 4: Subtotal petrosectomy and explantation done in case 1.

Case 2

A 5-year girl was referred to our centre with a history of meningitis following right-sided cochlear implantation performed at another institution. She had bilateral sensorineural hearing loss associated with IP-II malformation. After 4 months, the patient developed CSF otorhinorrhea, followed by an episode of meningitis. After successful medical management of meningitis, she was referred to our institution for further management.

HRCT temporal bone demonstrated features consistent with an IP-II malformation on both sides. The cochlear implant electrode was seen in situ in the right cochlea with a potential cerebrospinal fluid communication, correlating with the clinical presentation of CSF rhinorrhea and otorrhea. Intraoperative exploration revealed an active CSF leak originating from the extended round window. Subtotal petrosectomy was

performed to address the leak and eliminate the source of infection. The CSF leak was meticulously sealed using autologous fat and fascia reinforced with fibrin glue, followed by reimplantation with a MED-EL FORM 19 electrode. (Figures 5, 6) Categories of Auditory Performance (CAP) scores and Speech Intelligibility Rating (SIR) scores were measured every three monthly and recorded at the end of one year which showed CAP score of 4 and SIR score of 3. The patient is under periodic follow - up since 48 months till date and is asymptomatic till date.

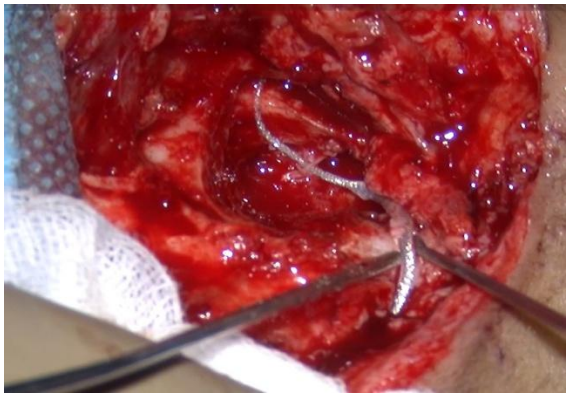

Figure 5: Previous CI electrode removed in case 2 at revision surgery.

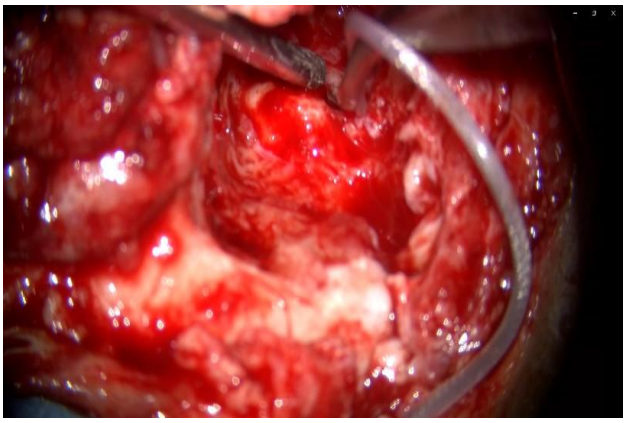

Figure 6: FORM 19 electrode reinserted after subtotal petrosectomy in case 2.

Case 3

A 3-year-old boy with left IP-I and right-sided Michel's aplasia underwent left sided cochlear implantation at our institute. After 8 months, he developed an episode of meningitis which was medically managed at another institution following which he was referred to our centre for further evaluation and management. HRCT of the temporal bone demonstrated the cochlear implant electrode in situ in the left ear with a collection suggestive of CSF in the middle ear cavity. During revision surgery, the previously implanted FORM 19 electrode was removed. An active CSF leak was noted from the extended round window. Cochlear stenting was performed using an insertion test device (ITD) and the round window was sealed using a soft tissue plug reinforced with fibrin glue. Subtotal petrosectomy was done to address the CSF leak and eliminate the risk of recurrent meningitis. Reimplantation with a new MED-EL FORM 19 electrode was performed six months later. (Figure 7-9) The staging was done to give a time frame of six months after the episode of meningitis. The patient has a CAP score of 2 and SIR score of 1.5 and is on follow up since three months.

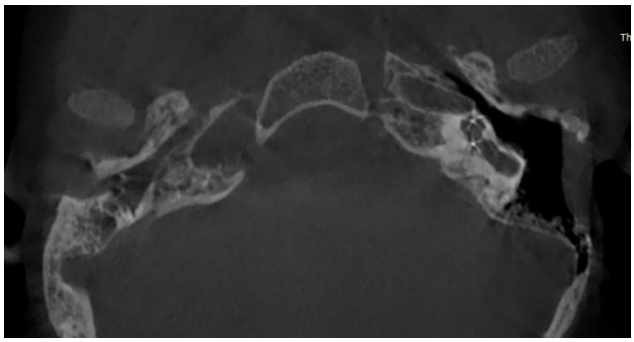

Figure 7: HRCT showing insertion test device in situ and subtotal petrosectomy in case 3.

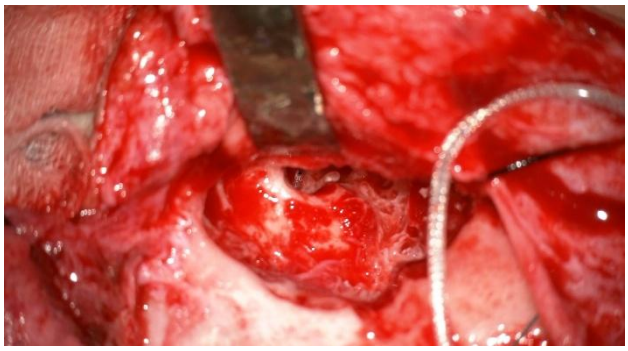

Figure 8: ITD stenting the cochlea in case 3.

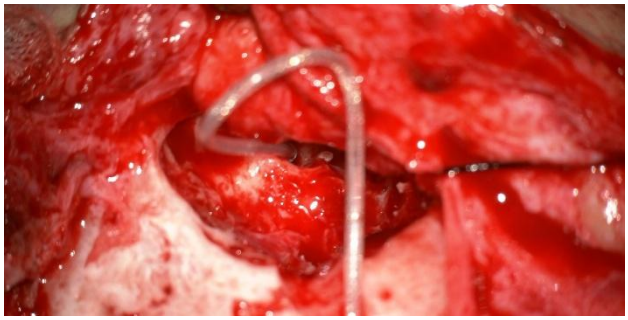

Figure 9: Reimplantation after 6 months with FORM 19 electrode in case 3.

DISCUSSION

Cochlear implantation is a very safe and effective procedure for restoring hearing in severe - profound sensori-neural hearing loss. Complications and failures in CI are rare as reported in world literature (1 - 5.5%) and include device failure, hematoma or abscess, skin

necrosis, exposed implant, mastoiditis/middle ear infections, cholesteatoma, extrusion of the electrode/receiver-stimulator, dislocation/incorrect position of the electrode, meningitis, cerebrospinal fluid (CSF) leakage, facial nerve paresis or paralysis, severe facial nerve stimulation, posterior canal wall injury, tinnitus or vertigo, resulting in non-use. Minor complications include transient facial palsy, minor wound problem/wound infection, otitis media, pain/headache, vertigo and tinnitus, chorda tympani injury. Meningitis is a rare but serious complication following cochlear implantation, with a risk of postoperative meningitis (both immediate and long-term) at 0.07%.[1] The association between bacterial meningitis and cochlear implants was reported in June 2002.[4] Clinically, a patient with post-CI meningitis presents similar to classical meningitis viz. fever, headache, neck stiffness, photophobia, and vomiting. However, CI users are reported to have vertigo.[5] The most common causative organisms for meningitis are Streptococcus pneumoniae and Haemophilus influenzae. Severe complications of meningitis include septic shock, organ failure, and even death. Complication such as brain injury has been reported in 10% to 20% of survivors.[1] Meningitis may occur any time after cochlear implantation, hence urgent identification and management is extremely important. Of 32 studies which included 27358 cochlear implantees, meningitis was reported in 202 cases and occurred from 1 day to 72 months after CI.[5] Bacterial meningitis can occur even several years post CI.[6] Although the exact mechanism underlying post-CI meningitis may be unclear; animal studies have reported that the presence of a foreign body within the inner ear has the potential to alter local immune responses.[5] After cochlear implantation, the risk factors for meningitis include otitis media, head trauma, cochlear malformation, cerebrospinal fluid (CSF) leaks, past history of otitis media / meningitis, presence of ventriculoperitoneal shunt, diminished immune status and vaccination status. Inner ear bone malformations are known to occur in approximately 20% of cases of congenital sensorineural hearing loss.[6,7,8] The presence of inner-ear malformation (IEM) can increase the incidence rate of CSF gushers up to 40%. Patients with IP-III are reported to have the highest risk of CSF gushers during cochlear implantation than all other IEM.[9] Enlarged vestibular aqueduct (EVA) is also associated with an increased risk of CSF gushers during CI.[9] In cochlear malformations in which a well-developed modiolus is absent, communication between the CSF and the perilymphatic spaces increases risk of CSF leakage. After CI, patients are advised to avoid contact sports, scuba diving, or other activities which increase pressure in the middle or inner ear.[8] In IP-I patients, meningitis can occur due to a defect between the cochlea and internal auditory canal resulting in CSF completely filling the cochlea. A defective stapes footplate may also be present in IP-I.[10] In IP-1, the absence of internal architecture within the cochlea, including absent modiolus and cribriform plate with a lack of interscalar septum poses a high risk of CSF gusher during CI. The vestibular aqueduct can be normal or enlarged.[11] Of 10 cases of meningitis after cochlear implantation in 1300 malformed ears, an overall rate of meningitis after cochlear implantation was reported to be 0.12% - Incomplete Partition (n=5), Mondini deformity (n=2), common cavity (n=2), and enlarged internal auditory canal (n=1). Six of 10 cases of post CI meningitis occurred with an intraoperative cerebrospinal fluid leak.[3] In a meta-analysis by Gowrishankar SV et al, the rate of postoperative meningitis in implanted patients who received the pneumococcal vaccine was reported to be negligible. The risk of meningitis in patients who received pneumococcal vaccine, antibiotic prophylaxis, who developed postoperative AOM, round window / cochleostomy electrode insertion, unilateral or bilateral CI was reported to be negligible.[1] Tegmen tympani defects can occur during surgery and result in cerebrospinal fluid (CSF) leakage and meningitis.[12] Prompt identification and management of meningitis is crucial to minimize morbidity and mortality. The parenteral antibiotic regimen for cochlear-implanted patients with meningitis should include vancomycin in combination with a broad-spectrum cephalosporin with good CSF penetration. After the medical management of meningitis, imaging with a CT scan to identify the possible cause followed by revision surgery is recommended.[6] Subtotal petrosectomy (SP) with closure of the external auditory canal and eustachian tube, and obliteration of the cavity can enable management of middle ear infection, deal with cerebrospinal fluid (CSF) leakage and prevent further risk of meningitis by isolating the cavity from the external environment.[13] Petrosectomy with a blind sac closure of the external auditory canal and obliteration of the Eustachian tube is a safe and effective procedure that protects against central nervous system infection in patients with otogenic CSF leak and has a low rate of recurrence.[14,15] Audiological outcomes following cochlear implantation in meningitis are reported to be satisfactory, providing functional levels of speech perception and intelligibility. The presence of neurological sequelae can pose significant challenges to the CI habilitation process and patients should undergo a complete evaluation so that any additional difficulties can be identified and addressed.

To prevent meningitis in CI recipients, conjugate vaccines against Streptococcus pneumoniae is recommended for all pediatric CI candidates by the Centers for Disease Control and Prevention (CDC) in 2003.[6] In children aged 2–9 years, a pneumococcal conjugate vaccine followed by a 23-valent pneumococcal polysaccharide vaccine is advised.[5] Children should receive vaccinations two or more weeks prior to cochlear implantation.

Atraumatic cochlear implantation, an adequate fibrous seal around the cochleostomy / round window can reduce the risk of meningitis.[16] Prophylactic antibiotics after cochlear implantation should be prescribed.[5] Measures to reduce meningitis risk after acute otitis media (AOM)

after CI include early treatment of AOM with antibiotics, and placement of ventilation tubes, if necessary.[1] Appropriate vaccination, along with early diagnosis and prompt medical and surgical management, plays a crucial role in prevention and effective management and avoidance of adverse outcomes. Parents of cochlear implantees should be counselled about this rare risk of meningitis after cochlear implantation, its clinical presentation and the need for immediate consultation and management.[6]

In our series, in all three patients, the contributory factor for meningitis post-implantation was CSF leak; two patients had inner ear malformation (IP I – 1 patient, IP II–1 patient) and 1 patient had breach in the tegmen. All patients were initially managed medically, with appropriate intravenous antibiotics which cross the blood–brain barrier. Definitive surgical management was individualized based on patient-specific risk factors and intraoperative findings. **(**Table 1)

Table 1: Summary of patient demographics, etiology and surgical management of meningitis.

Parameters	Patient 1	Patient 2	Patient 3
Age & gender	32 years / Female	5 years / Female	4 years / Male
Etiology of meningitis	CSF leak Tegmen defect	CSF leak, IP-II malformation	CSF leak, IP-I malformation
Onset of meningitis after CI	3 episodes - 6 months, 2 years, 3 years	4 months	1 year
Subtotal petrosectomy and CI-staging	STP done Declined CI	Single sitting	Two stage procedure Explanted – 6 weeks after meningitis CI–after 6 months post explantation

Subtotal petrosectomy (STP) played a critical role in the management of all three cases. Through closure of the tubal orifice and the external auditory canal, STP enabled complete isolation of the surgical cavity from the external environment, thereby decreasing the subsequent risk of postoperative infection, cerebrospinal fluid (CSF) leakage, and meningitis. In addition, the unobstructed view of the surgical cavity helped in excellent control and visualization of anatomical landmarks. In one patient without active infection, reimplantation was performed during the same surgical setting, whereas in another patient, reimplantation was staged after six months to allow complete healing and further reduce the risk of reinfection. The duration of follow-up ranged from 3 months – 48 months with an average follow-up period of 24 months. During this period, no recurrence of meningitis, CSF leak, or implant extrusion was observed, supporting the safety and efficacy of STP in these high-risk patients.

Audiological and speech outcomes following reimplantation were satisfactory, with improvements observed in Categories of Auditory Performance (CAP) score, Speech Intelligibility rating (SIR) score, with statistically significant improvement ($p < 0.05$). Meticulous surgical technique combined with appropriate immunization remains central to minimizing infectious complications in cochlear implantees. Early recognition of symptoms, effective medical management of meningitis and timely surgical management are crucial to minimizing morbidity and optimizing long-term outcomes after cochlear implantation.

CONCLUSION

To conclude, meningitis is a rare but serious complication after cochlear implantation. Preventive measures such as vaccination, appropriate CI surgical technique, early management of ear infections and close follow up are essential. This study emphasizes the need for early recognition, thorough imaging, and prompt medical and surgical management in preventing recurrent meningitis. Reimplantation when appropriately timed results in satisfactory auditory, speech and language outcomes.

Funding: No funding sources
Conflict of interest: None declared
Ethical approval: Not required

REFERENCES

1. Gowrishankar SV, Fleet A, Tomasoni M, Durham R, Umeria R, Merchant SA, et al. The risk of meningitis after cochlear implantation: a systematic review and meta-analysis. Otolaryngol Head Neck Surg. 2023;169(3):467-81.
2. Neagoș CM, Nenec BG, Neagoș A, Sin A. Complications in cochlear implant surgery: a comprehensive review. J Med Life. 2025;18(10):939-45.
3. Gowrishankar S, Fleet A, Tomasoni M, Kuhn I, Tysome J, Smith ME, et al. Meningitis risk in patients with inner ear malformations after cochlear implants: a systematic review and meta-analysis. Otol Neurotol. 2023;44(7):627-35.

4. Young NM, Tan TQ. Current techniques in management of postmeningitic deafness in children. Arch Otolaryngol Head Neck Surg. 2010;136(10):993-8.
5. Alanazi GA, Alrashidi AS, Alqarni KS, Khozym SAA, Alenzi S. Meningitis post-cochlear implant and role of vaccination. Saudi Med J. 2022;43(12):1300-8.
6. Pettersen G, Ovetchkine P, Tapiero B. Group A streptococcal meningitis in a pediatric patient following cochlear implantation: report of the first case and review of the literature. J Clin Microbiol. 2005;43(11):5816-5818.
7. Reefhuis J, Honein MA, Whitney CG, Chamany S, Mann EA, Biernath KR, et al. Risk of bacterial meningitis in children with cochlear implants. N Engl J Med. 2003;349(5):435-5.
8. Zwierz A, Masna K, Burduk P. Recurrent meningitis in congenital inner ear malformation. Ear Nose Throat J. 2021;100(1 Suppl):38S-41S.
9. Hazazi M, Almashharawi E, Alamry S, Alkusayer MM, Altimyat A, Alsalamah Y. Retrospective analysis of cerebrospinal gushers in cochlear implant surgery: incidence, risk factors, and outcomes—a systematic review and meta-analysis. Ear Nose Throat J. 2024.
10. Hamano Y, Kase K, Tetsuka A, Dias M, Nakamura K, Sasaki T, et al. Surgical indication of inner ear malformation associated with bacterial meningitis. Clinics in Surgery. 2018;3:2012.
11. Parlak Ş, Akgoz A, Arslan S, Sennaroglu L, Karlı Oguz K. Flocculus herniation into the internal acoustic canal in incomplete partition type I: a case report. J Int Adv Otol. 2023;19(3):266–8.
12. Nguyen D, Deitrick J, Sessions W, Nguyen T. Tegmen tympani cerebrospinal fluid leakage repair: transmastoid approach utilizing Stryker bone cement. J Med Cases. 2018;9(3):90-3.
13. Sanna M, Merkus P, Free R, Falcioni M. Surgery for Cochlear and Other Auditory Implants. Stuttgart, Germany: Thieme; 2016. p. 158-78.
14. Amernik K, Jaworowska E. Congenital spontaneous otogenic cerebrospinal fluid leak as a cause of recurrent meningitis in a 9-year-old child: case report and literature review. Pol Otorhinolaryngol Rev. 2022;11(1):41-4.
15. D'Angelo G, Donati G, Bacciu A, Guida M, Falcioni M. Subtotal petrosectomy and cochlear implantation. Acta Otorhinolaryngol Ital. 2020;40(6):450-6.
16. Wei BP, Shepherd RK, Robins-Browne RM, Clark GM, O'Leary SJ. Pneumococcal meningitis post-cochlear implantation: preventative measures. Otolaryngol Head Neck Surg. 2010;143(5 Suppl 3):S9-14.

Cite this article as: Pyrbot KS, Vaidhyswaran R, Natarajan K, Kameswaran M. Post-cochlear implantation meningitis: challenges and outcomes. Int J Otorhinolaryngol Head Neck Surg 2026;12:1022-7.