

## Original Research Article

# Endonasal dacryocystorhinostomy without stents: our experience

Preeti S. Raga\*, Amrith Laal Waghre

Department of ENT, Kamineni Institute of Medical Sciences, Narketpally, Nalgonda, Telangana, India

**Received:** 13 June 2017

**Revised:** 25 June 2017

**Accepted:** 29 June 2017

### \*Correspondence:

Dr. Preeti S. Raga,

E-mail: [dr.preetiraga.or@gmail.com](mailto:dr.preetiraga.or@gmail.com)

**Copyright:** © the author(s), publisher and licensee Medip Academy. This is an open-access article distributed under the terms of the Creative Commons Attribution Non-Commercial License, which permits unrestricted non-commercial use, distribution, and reproduction in any medium, provided the original work is properly cited.

## ABSTRACT

**Background:** Dacryocystorhinostomy (DCR) for the treatment of nasolacrimal duct obstruction. The aims of the study were to assess the patency rate of endoscopic (ED DCR) using a technique similar to that described by McDonogh and Meiring but without the use of nasolacrimal silicone stents.

**Methods:** Endonasal dacryocysto-rhinostomies (ED DCRs) were performed without the use of silicone stents in 46 patients (20 male, 26 female). These patients were followed up for an average of eight months.

**Results:** The procedure was successful in 86.95% of cases as measured by patient's relief of symptoms and endoscopic visualization of a middle meatal ostium draining the lacrimal sac.

**Conclusions:** In our study ED DCR without stents had less complications and also a success rate of 86.95% achieved when compared with DCR with stents.

**Keywords:** Endoscopic endonasal dacryocysto- rhinostomy, External DCR, Dacryocystitis

## INTRODUCTION

Dacryocystorhinostomy (DCR) for the treatment of nasolacrimal duct obstruction was first described via an external approach by Toti in 1904, Intranasal DCR by Caldwell in 1893 and the endoscopic trans-nasal DCR by McDonogh and Meiring in 1989.<sup>1-3</sup> A number of modifications using lasers have also been introduced as a useful tool in endoscopic DCR.<sup>4-6</sup> There is some controversy, however, regarding the use of stenting for DCR. Those who advocate its use report an increased patency rate, due to maintenance of the ostium of the lacrimal sac into the middle meatus and correction of presacral stenosis.<sup>1,7</sup> Allen and Berlin, however reported a higher failure rate when using silicone tubing. Formation of granulomatous inflammation, punctal erosion and slitting of the canaliculi in association with silicone intubation as the reason for failure.<sup>8-10</sup> So this study was aimed to assess the patency rate of endoscopic (ED DCR) using a technique similar to that described by

McDonogh and Meiring but without the use of nasolacrimal silicone stents.

## METHODS

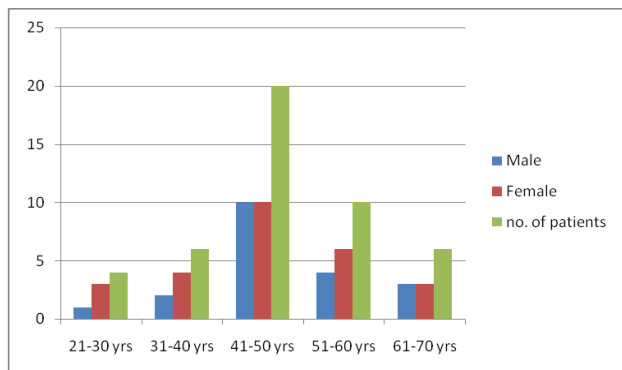
Between March 2007 and September 2012, 46 patients (20 males, 26 females) of age group 21-70 years (Figure 1 and 2) were treated surgically for naso-lacrimal duct obstruction at Kamineni Institute of Medical Sciences Narketpaly Nalgonda Dist. All 46 patients main complaint was epiphora. In 18 cases had right epiphora and 18 cases had left epiphora, other 10 cases were having bilateral epiphora.

### *Inclusion criteria*

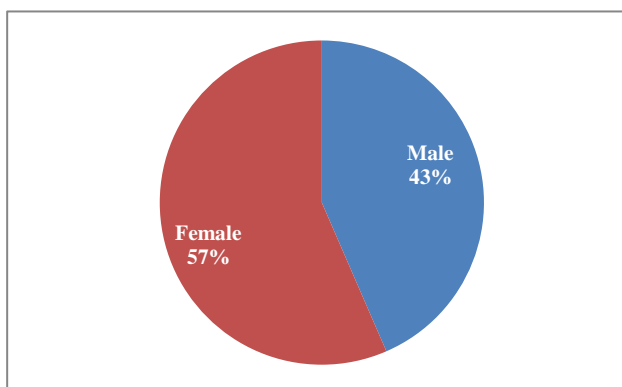
Inclusion criteria were patient with age group of 21-70 yrs of both genders; history of chronic epiphora; hard stop of probe test.

**Exclusion criteria**

Exclusion criteria were age below 20 years; history of congenital epiphora, acute epiphora; soft stop of probe test; H/O HTN, DM, allergy, tumours of nose and PNS, granulomatous diseases of nose.



**Figure 1: Age and sex distribution in patients of chronic dacryocystitis.**



**Figure 2: Sex ratio in patients of chronic dacryocystitis.**

**Table 1: Clinical feature and procedures.**

Clinical features	No.	Percentage (%)	Procedures
<b>Right epiphora</b>	18	39.13	Right ED DCR
<b>Left epiphora</b>	18	39.13	Left ED DCR
<b>Bilateral epiphora</b>	10	21.74	6 left ED DCR 4 right ED DCR
<b>Total</b>	46	100	

Patients underwent ophthalmologic and otorhinolaryngological evaluation, including nasal endoscopy using 0° rigid endoscopes. Apart from chronic dacryocystitis, on clinical examination seven patients had deflected nasal septum, middle turbinate hypertrophy (five patients), chronic maxillary sinusitis (two patients), mucocele (five patients) and lacrimal abscess (4 patients) (Table 1 and 2). We performed a CT scan in above 23 patients in order to assess the anatomy and possible cause of obstruction.

**Table 2: Diagnosis and surgical procedures performed.**

Diagnosis	n	Percentage	Procedures
<b>Chr. DCT</b>	32	69.56%	Endonasal DCR
<b>DNS with DCT</b>	07	15.22%	Septoplasty with ED DCR
<b>Conchobullosa with DCT</b>	05	10.86%	Partial turbinectomy with ED DCR
<b>Chr. maxillary sinusitis with DCT</b>	02	4.36%	Middle meatus antrostomy and ED DCR
<b>Total</b>	46	100%	

46 enrolled patients were diagnosed as chronic dacryocystitis, and endonasal DCR were performed in all 46 patients. 23/46 patients were having associated findings like deflected nasal septum in 7, concha bullosa in 5 and chronic sinusitis in 2, mucocele 5 patients and lacrimal abscess in 4 patients. Septoplasty, middle turbinoplasty, for better exposure of the surgical area, and middle meatal antrostomies were carried in the same sitting (Table 2).

**Surgical technique**

Those who consented for surgery were then listed for an endoscopic ED DCR without stent. The technique used was similar to that described by McDonogh and Meiring.<sup>3</sup>

**Post-operative care**

The post-operative treatment included oral antibiotics and nasal saline douching. Patients were examined on a monthly basis for the first 3 months and then every six months for the second year. Complete epithelialisation of the rhinostomy occurred within two months, but the final diameter of the rhinostomy was only considered stable at 8-12 months after surgery.

**Statistical analysis**

Data were entered in Microsoft Excel (U.S.A). Results are expressed in percentages and shown with the help of bar diagram and pie chart.

**RESULTS**

Surgical success was defined by resolution of signs and symptoms, rhinostomy stabilization and free lacrimal drainage. A modified 5-point Likert Scale was used to assess subjective changes in symptoms.<sup>5</sup> The patients were asked about the degree of the epiphora and improvement of the symptoms. Declaration of improvement, on the modified Likert Scale, (Table 3 and Table 4) with a score of 1 to 3 was considered successful. Functional success was observed in 40/46 cases (86.95%). Among these 40 cases, 38 were without

epiphora and 2 reported an improvement in symptoms (Table 3). Our anatomical success, showed that, in 40/46 cases, the rhinostomy was patent leading to an overall anatomical success rate of 86.95% (Table 4).

**Table 3: Subjective (functional) results: modified Likert scale.**

<b>Score 1</b>	No symptoms	40
<b>Score 2</b>	Significant improvement	02
<b>Score 3</b>	Slight improvement	00
<b>Score 4</b>	No improvement	04
<b>Score 5</b>	Worsening of symptoms	00
<b>Results</b>	40/46	86.95%

**Table 4: Total anatomical results ED DCR.**

Patency	No. of patients
<b>Rhinostomy open</b>	40
<b>Rhinostomy closed</b>	02
<b>Failure</b>	04
<b>Results</b>	40

In two patients rhinostomy was closed and in another four patients bony stump was preventing drainage of tears because of inadequate removal of bone. Revision endonasal DCR was performed in above 4 patients.

### Complications

No major complications occurred intraoperatively. 3 patients developed oedema of eye lids and one patient developed congestion of cornea, 4 cases of latero-septal synechia which however, did not interfere with functional outcome or require further treatment. All four patients with epiphora after surgery improved on conservative treatment.

## DISCUSSION

McDonogh and Meiring were the first modern surgeons credited with introducing endoscopic transnasal DCR in the late 1980s.<sup>3</sup>

ED DCR has a success rate of 83-94% and has been demonstrated to offer similar outcomes when compared to EX DCR, with low complication rates.<sup>10-14</sup> ED DCR a good option for the treatment of primary nasolacrimal duct obstruction but it is also considered an acceptable procedure for the treatment of failure of EX DCR.<sup>15</sup>

The advantages of ED DCR with respect to EX DCR include less interference on the lacrimal pump mechanism and the possibility to treat sino-nasal disorders and anatomical abnormalities in the same operation in the present series, we performed 14 ancillary procedures (5 septoplasty, 7 middle turbinoplasty, and 2 middle meatal antrostomies) that would not have been possible if an EX DCR had been performed.<sup>16</sup>

The posterior mucosal flap offers the best possibility for easy access to the bone over-lying the sac, allowing wide and complete exposure of the medial wall of the sac that can thus be marsupialised. This represents a key point in the procedure that assists in the creation of a large rhinostomy that obviates the need for silicone stenting. Inadequate bone removal is also a common cause of failure.<sup>9</sup>

Various instruments can be used to remove the bone. Kerrison punch is a safe and effective tool to obtain a wide DCR although, in some instances, it is not adequate, for the easy removal of the superior aspect of the frontal process of the maxillary bone for anatomical reasons, since the forceps cannot incarcerate the bone in these cases we would favour powered drills. These instruments prevent inadequate bone removal and failure of Surgery.<sup>17,18</sup>

The size of the lacrimal sac, at the time of the surgery, has a direct influence on the success of the procedure as described in the literature in a group of 49 patients undergoing endonasal DCR, Mann reported that the neo-ostium was reduced in size in the first 4 weeks after surgery, thereafter, the ostium dimensions appear to be stable.<sup>15,19</sup>

The use of silicone stents is considered routine in many institutions. Although controversial, silicone stents are used to keep the neo-ostium open after the procedure and are thought to maintain the patency of the ostium but prolonged silicone intubation adds to the risk of granulation tissue formation at the neo-ostium, and has been described as a cause of failure.<sup>20,21</sup>

In recent years, a number of Authors have described endonasal DCR without silicone stenting.<sup>10,22,23</sup> Smirnov demonstrated in a prospective randomized trial of patients undergoing primary ED DCR that silicone stenting is unnecessary, giving an overall success rate with and without silicon tubes of 78% and 100% respectively.<sup>10</sup> This trial showed statistically significant results favouring non-stenting. This has been confirmed recently in another randomised trial by Unlu et al, showing results in the stented and non-stented groups of 84.2% and 94.7%. Although there was no statistical difference showing one technique to be superior to another, the authors recommended that silicone intubation was not a mandatory requirement following ED DCR.<sup>23</sup> In the present series, the silicone stents were not used thus allowing the opportunity of reducing the costs of the procedure and minimizing the discomfort for the patient, without negatively affecting the outcome.

## CONCLUSION

Our results confirm that endonasal DCR without stenting is effective for the treatment of naso-lacrimal duct obstruction. This procedure gives good anatomic and functional results, with low complication rates. The

endonasal endoscopic approach allows simultaneous treatment of associated anatomic anomalies and sino-nasal pathology. In the present series of 46 consecutive procedures, a functionally patent dacryocystorhinostomy was achieved without the need for nasolacrimal stent insertion.

## ACKNOWLEDGMENTS

The authors submit their sincere thanks to the Department of ENT and management for their support.

*Funding: No funding sources*

*Conflict of interest: None declared*

*Ethical approval: The study was approved by the Institutional Ethics Committee*

## REFERENCES

1. Toti A. Nuovo metodo conservatore di cura radicale delle suppurazioni croniche del sacco lacrimale. *Clinica Moderna.* 1904;10:385.
2. Caldwell G. Two new operations for obstruction of the nasal duct, with preservation of the canaliculi, and with an incidental of a new lacrymal probe. *Am J ophthalmol.* 1893;10:189-93.
3. McDonogh M, Meiring JH. Endoscopic transnasal dacryocystorhinostomy. *Laryngolotol.* 1989;100:585-7.
4. Massaro BM, Gonnering RS, Harris GJ. Endonasal laser dacryocystorhinostomy. A new approach to nasolacrimal duct obstruction. *Arch Ophthalmol* 1990;108(8):1172-6.
5. Gonnering RS, Lyon DB, Fisher JC. Endoscopic laser-assisted lacrimal surgery. *Am J Ophthalmol* 1991;111(2):152-7.
6. Patel BC, Phillips B, McLeish WM, Flaharty P, Anderson RL. Transcanalicular neodmium: YAG laser for revision of dacryocystorhinostomy. *Ophthalmology.* 1997;104(7):1191-7.
7. Mntynen J, Yoshitsugu M, Rautiainen M. Results of dacryocystorhinostomy in 96 patients. *Acta Otolaryngol Suppl.* 1997;529:187-9.
8. Reifler DM. Results of endoscopic KTP laser-assisted dacryocystorhinostomy. *Ophthal Plast Reconstr Surg.* 1993;9(4):231-6.
9. Allen K, Berlin AJ. Dacryocystorhinostomy failure: association with nasolacrimal silicone intubation. *Ophthalmic Surg.* 1989;20(7):486-9.
10. Anderson RL, Edwards JJ. Indications, complications and results with silicone stents. *Ophthalmology.* 1979;86(8):1474-87.
11. Onerci M, Orhan M, Ogretmenoğlu O, Irkeç M. Long-term results and reasons for failure of intranasal endoscopic dacryocystorhinostomy. *Acta otolaryngol.* 2000;120:319-22.
12. Smirnov G, Tuomilehto H, Teräsivirta M, Nuutinen J, Seppä J. Silicone tubing is not necessary after primary endoscopic dacryocystorhinostomy: A prospective randomized study. *Am J Rhinol.* 2008;22:214-7.
13. Yigit O, Samancioglu M, Taskin U, Ceylan S, Eltutar K, Yener M. External and endoscopic dacryocystorhinostomy in chronic dacryocystitis: comparison of results. *Eur Arch Otorhinolaryngol.* 2007;264:879-85.
14. Feretis M, Newton JR, Ram B, Green F. Comparison of external and endonasal dacryocystorhinostomy. *J laryngol Otol.* 2009;123:315-9.
15. Demarco R, Strose A, Araújo M, Valera FC, Moribe I, Anselmo-Lima WT. Endoscopic revision of external dacryocystorhinostomy. *Otolaryngol head neck Surg.* 2007;137:497-9.
16. Nussbaumer M, Schreiber S, Yung MW. Concomitant nasal procedures in endoscopic dacryocystorhinostomy. *J Laryngol Otol.* 2004;118:267-9.
17. Umopathy N, Kalra S, Skinner DW, Dapling RB. Long-term result of endonasal laser dacryocystorhinostomy. *Otolaryngol Head Neck Surg.* 2006;135:81-4.
18. Ajalloueyan M, Fartookzadeh M, Parhizgar H. Use of laser for dacryocystorhinostomy. *Arch Otolaryng Head Neck Surg.* 2007;133:340-3.
19. Mann BS, Wormald PJ. Endoscopic assessment of the dacryo-cystorhinostomy ostium after endoscopic surgery. *Laryngoscope.* 2006;116:1172-4.
20. Allen K, Berlin AJ. Dacryocystorhinostomy failure: association with nasolacrimal silicone intubation. *Ophthalmic Surg.* 1989;20:486-9.
21. Kim NJ, Kim JH, Hwang SW, Choung HK, Lee YJ, Khwarg SI. Lacrimal silicone intubation for anatomically successful but functionally failed external dacryocystorhinostomy. *Kor J Ophthalmol.* 2007;21:70-3.
22. Unlu HH, Gunhan K, Baser EF, Songu M. Long-term results in endoscopic dacryocystorhinostomy: Is intubation really re-quired? *Otolaryngol Head Neck Surg.* 2009;140:589-95.
23. Unlu HH, Toprak B, Aslan A, Guler C. Comparison of surgical outcomes in primary ndoscopic dacryocystorhinostomy with and without silicone intubation. *Ann Otolrhinol Laryngol.* 2002;111:704-9.

**Cite this article as:** Raga PS, Waghre AL. Endonasal dacryocystorhinostomy without stents: our experience. *Int J Otorhinolaryngol Head Neck Surg* 2017;3:932-5.