

Original Research Article

Mandibular bone invasion in oral squamous cell carcinoma: diagnostic concordance between radiology and histopathology

Prathamesh S. Karande¹, Aditi Saha^{1*}, Ashwini Mane¹, Navnath Dhone²,
Parag Watve¹, Chaitanya Patil³, Prathamesh Pawar⁴

¹Department of Head and Neck Oncology, Kolhapur Cancer Centre, Kolhapur, Maharashtra, India

²Department of Radiology, Kolhapur Cancer Centre, Kolhapur, Maharashtra, India

³Department of Pain and Palliative Oncology, Kolhapur Cancer Centre, Kolhapur, Maharashtra, India

⁴Department of Oncopathology, Kolhapur Cancer Centre, Kolhapur, Maharashtra, India

Received: 12 November 2025

Accepted: 07 May 2026

*Correspondence:

Dr. Aditi Saha,

E-mail: dr.aditisaha28@gmail.com

Copyright: © the author(s), publisher and licensee Medip Academy. This is an open-access article distributed under the terms of the Creative Commons Attribution Non-Commercial License, which permits unrestricted non-commercial use, distribution, and reproduction in any medium, provided the original work is properly cited.

ABSTRACT

Background: Oral squamous cell carcinoma (OSCC), constituting 90% of oral cancers, frequently invades the mandible, complicating staging, prognosis, and surgical planning. Contrast-enhanced CT (CECT) is vital for detecting bone invasion and guiding management.

Methods: A retrospective study was conducted on patients diagnosed with OSCC who showed radiological evidence of bone involvement and subsequently underwent surgical intervention between January 2020 and December 2023. Parameters assessed included patient demographics, surgical approach, radiological and histopathological bone involvement, tumor and nodal staging, recurrence patterns, distant metastasis, and adjuvant therapy received.

Results: The study included 74 patients, with a male predominance (65 males, 87.83%; 9 females, 12.16%). The mean age was 54.66±0.49 years, and the median follow-up period was 6 months. In 66 out of 74 patients (89.28%), radiological findings were consistent with histopathological confirmation, supporting the diagnostic reliability of contrast-enhanced computed tomography (CECT). Among the 55 patients who received radiotherapy, local recurrence occurred in 16.4%, while regional and loco-regional recurrences were comparatively lower.

Conclusions: This study highlights a strong agreement between radiological and pathological evaluations in identifying bone involvement in oral carcinoma, affirming the utility of CECT as an effective, non-invasive diagnostic tool.

Keywords: Radiological bone assessment, Oral squamous cell carcinoma, Adjuvant therapy, Loco-regional recurrence, Pathological bone invasion

INTRODUCTION

Oral cancer continues to pose a major global health burden, with oral squamous cell carcinoma (OSCC) accounting for nearly 90% of all malignant lesions within the oral cavity.^{1,2} A substantial proportion of these cases involve the mandible, making the assessment of bone invasion a crucial component in the clinical management of the disease. The presence of mandibular bone involvement significantly affects tumor staging,

influences surgical planning, and impacts overall patient prognosis. OSCC is known for its aggressive behavior, often progressing with minimal or subtle clinical signs, underscoring need for detailed diagnostic evaluation.³⁻⁵ Radiological imaging plays a vital role in supplementing clinical examination by providing critical information on tumor size, depth of infiltration, and the extent of osseous involvement.⁶ Advanced imaging modalities, particularly contrast-enhanced computed tomography (CECT), offer high-resolution visualization of mandibular structures,

aiding in accurate staging and facilitating optimal surgical and therapeutic decisions.⁷⁻⁹ For surgeons, especially when planning procedures such as mandibulectomy, understanding the precise extent of bone invasion is essential to achieving clear surgical margins while maintaining functional outcomes.^{5,6,9,10}

This retrospective study aims to explore the correlation between radiological findings and histopathological confirmation of mandibular bone invasion in OSCC. By comparing preoperative imaging results with postoperative pathological assessments, the study evaluates the diagnostic reliability of radiological modalities, thereby contributing valuable insights toward enhanced diagnostic accuracy and improved treatment planning.

METHODS

This retrospective study was carried out at the Kolhapur Cancer Centre, Kolhapur, and included patients diagnosed with oral squamous cell carcinoma (OSCC) who demonstrated radiological evidence of mandibular bone invasion and subsequently underwent curative surgical resection between January 2020 and December 2023. Patient information was obtained from the Medical Records Department (MRD), and only cases with complete clinical, radiological, and histopathological documentation were considered for inclusion.

Inclusion and exclusion criteria

Eligible patients were between 18 and 75 years of age with histologically confirmed OSCC and corresponding radiological findings indicating bone marrow invasion. The exclusion criteria for this study included histopathological types other than squamous cell carcinoma, isolated cortical erosion without evidence of marrow involvement, patients who were medically unfit for surgery, and those with inoperable tumors. Additional exclusions were cases with incomplete documentation, such as missing computed tomography (CT) reports, patients with prior exposure to radiotherapy, and individuals presenting with recurrent or residual disease at the time of evaluation.

Radiological and pathological evaluation

All radiological evaluations were performed using CECT. Bone invasion was defined by the presence of marrow infiltration or bone destruction. Only definitive radiological interpretations—either positive or negative—were included, with equivocal findings excluded. Surgical excision with bone resection was conducted when imaging indicated bone involvement. Histopathological analysis was performed independently by an experienced oncopathologist blinded to the imaging results. Bone involvement was confirmed histologically when the tumor extended beyond the cortical boundary

into the medullary cavity. Absence of such findings classified the case as negative for bone invasion.

Tumor attributes such as anatomical location and histological grade were documented. Tumor differentiation was categorized as well, moderately, or poorly differentiated. Bone invasion patterns were further classified into erosive or infiltrative types. Radiological and histopathological findings were compared to determine the diagnostic accuracy of CECT in detecting mandibular bone involvement.

Statistical analysis plan

Descriptive statistics were employed to summarize the study data. Patient demographics—including age, sex, and follow-up duration—were expressed as frequencies, percentages, means, and medians. Tumor-related characteristics (site, stage, and grade) were also described using frequency distributions.

A cross-tabulation analysis was performed to evaluate the agreement between radiological and histopathological findings, with the concordance rate presented as a percentage. Recurrence patterns—categorized as local, regional, loco-regional, or distant—were compared across patients who did and did not receive adjuvant radiation therapy. The results were presented using tables and visual aids such as bar graphs, pie charts, and donut charts to enhance interpretability.

RESULTS

We have included 74 cases in the present study. Table 1 presents the demographic characteristics of the study population (n=74), with 65 males (87.83%) and 9 females (12.16%). The median follow-up duration was 6 months. Table 2 outlines the tumour characteristics of the study cohort (n=74), with the lower gingivo-buccal sulcus (40.54%) being the most common tumour site, followed by the alveolus (27.03%) and buccal mucosa (20.27%).

Tumours located in the retromolar trigone accounted for 12.16% of cases. Histologically, most tumours were moderately differentiated (51.35%), while 29.73% were well differentiated and 18.92% poorly differentiated.

Table 1: Demographic characteristics of the study population (n=74).

Characteristic	Value
Total patients	74
Males (%)	65 (87.83)
Females (%)	9 (12.16)
Mean age (years)	54.66±0.4925
Median follow-up (months)	6

Table 3 outlines the relationship between radiological and pathological bone marrow involvement in the study

cohort of 74 patients. All patients (100%) showed radiological evidence of marrow involvement on CECT, while pathological confirmation of bone involvement was found in 66 patients (89.18%). Notably, 8 patients (10.81%) exhibited radiological involvement without corresponding pathological confirmation, suggesting the potential false positives or non-malignant marrow

changes. The concordance rate between radiological and pathological bone marrow involvement in this study was notably high, with 66 out of 74 patients (89.18%) showing agreement between CECT findings and pathological confirmation. This strong concordance underscores the diagnostic reliability of CECT in detecting true bone marrow involvement.

Table 2: Tumour characteristics of study cohort (n=74).

Characteristic	Sub-category	Number of patients	Percentage (%)
Tumour location (oral cavity)	Lower GBS	30	40.54
	Alveolus	20	27.03
	Buccal mucosa	15	20.27
	Retromolar trigone	9	12.16
Tumour differentiation	Well differentiated	22	29.73
	Moderately differentiated	38	51.35
	Poorly differentiated	14	18.92

Table 3: Radiological vs. Pathological bone marrow involvement (n=74).

Finding	Number of patients	Percentage (%)
Radiological marrow involvement (on CECT)	74	100
Pathological bone involvement (confirmed)	66	89.18
Radiological involvement without pathology	8	10.81
Pathological involvement without radiological	0	0
No involvement (radiological or pathological)	0	0

Figure 2 presents a comparison of recurrence patterns between patients who received adjuvant radiation therapy and those who did not, expressed as percentages.

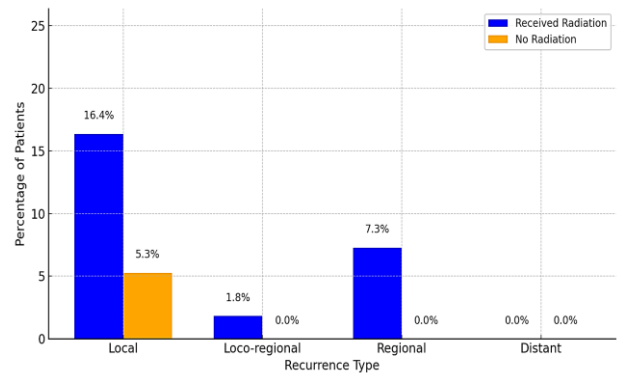


Figure 2: Recurrence patterns of the present cohort.

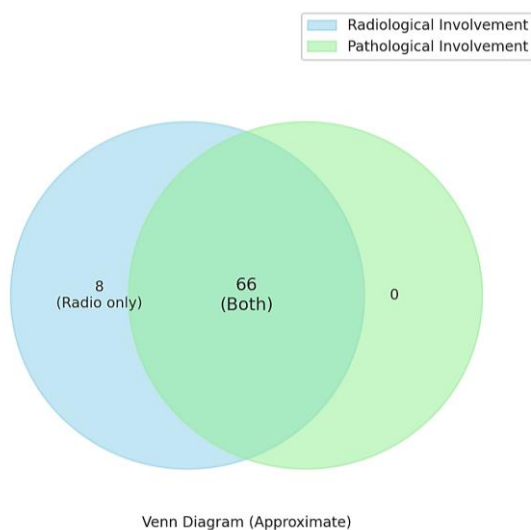


Figure 1: VENN diagram showing the concordance of radiological and pathological bone marrow.

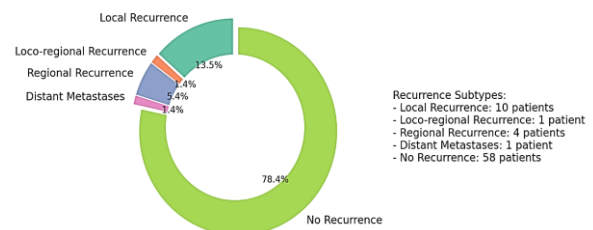


Figure 3: Overall recurrence pattern of the present cohort (n=74).

While local (16.4%) and regional (7.3%) recurrences were observed among the 55 patients who received radiation, only one local recurrence (5.3%) occurred in the 19 patients without radiation, suggesting that radiation reduces but does not eliminate recurrence risk, potentially.

The split donut chart (Figure 3) shows that 78.4% of patients had no recurrence during follow-up, indicating favorable short-term outcomes.

Among the 16 recurrences, local was most common (13.5%), followed by regional (5.4%), loco-regional (1.4%), and distant metastasis (1.4%), underscoring the importance of vigilant post-treatment surveillance.

DISCUSSION

This retrospective analysis of 74 patients with OSCC examined the concordance between radiological evidence of bone marrow invasion, identified through CECT, and histopathological confirmation. Additionally, it evaluated recurrence patterns in relation to the administration of adjuvant radiation therapy. The study observed a high diagnostic agreement of 89.18% between imaging and pathology, reinforcing the clinical utility of radiological assessment. Furthermore, it provided valuable insight into recurrence dynamics, particularly in patients receiving adjuvant radiation.

Radiological-pathological correlation of bone marrow involvement

All patients in the study showed marrow involvement on preoperative CECT, with 89.18% confirmed on histopathology. This high concordance is consistent with previous findings, such as those reported by Kouketsu et al, who found MRI to be highly sensitive (88.9%) and to have a strong negative predictive value (92.3%) for detecting marrow invasion in oral cancers. Similarly, Qiao et al demonstrated that both CT and MRI are effective in assessing mandibular bone invasion, with pooled sensitivities of 85% and 93% and specificities of 86% (CT) and 84% (MRI), respectively.^{10,11}

Dinter et al further highlighted MRI's superior performance over FDG-PET in identifying marrow infiltration, particularly in axial skeleton malignancies.¹² Although CECT was the modality used in the present study, its high concordance with histopathology supports its diagnostic reliability in head and neck oncology. Despite this, 10.81% of cases demonstrated false-positive radiological findings, where marrow invasion on CECT was not pathologically confirmed. This aligns with concerns raised by El-Galaly et al, who emphasized the risk of false positives due to reactive or inflammatory changes mimicking tumor infiltration.¹³ These findings underscore the necessity of correlating imaging with histology for definitive diagnosis.

Adjuvant radiation therapy and recurrence patterns

A key objective of the study was to explore how adjuvant radiation therapy influenced recurrence. Among the 55 patients who received radiation, local recurrence occurred in 16.4%, while regional and loco-regional recurrences were less common. Conversely, among the 19 patients

who did not undergo radiation, only a single case of local recurrence (5.3%) was noted, with no regional or distant failures. These findings are consistent with Tsai et al, who observed that adjuvant radiotherapy in early-stage oral cancer significantly lowered neck recurrence and improved survival.¹¹ Likewise, Faraji et al reported that delays in initiating postoperative radiotherapy beyond six weeks adversely affected both recurrence-free and overall survival in head and neck squamous cell carcinoma.¹² Lee et al also found high recurrence rates (~60%) among patients who failed to comply with recommended adjuvant therapy, with recurrences occurring on average within 8 months.¹² Though recurrence rates in our study were lower, this could be attributed to differences in tumor stage, follow-up duration, or treatment compliance.

Recurrence timing and pattern

Most recurrences observed in our cohort were local, followed by regional and combined loco-regional types. This mirrors findings by Trosman et al, who noted that the majority of recurrences in head and neck cancers occur within the initial six months post-treatment and are primarily local failures.¹⁴ This trend supports the necessity for intensive surveillance during the early follow-up period and justifies the study's 6-month median follow-up window.

Diagnostic considerations in marrow involvement

In the context of marrow involvement detection, previous studies in hematological malignancies further reinforce the value of advanced imaging. Ibrahim et al reported a high diagnostic yield for PET/CT in detecting bone marrow involvement in lymphoma, often eliminating the need for biopsy.¹⁵ Zamagni et al highlighted MRI's superior sensitivity in identifying marrow lesions in multiple myeloma, emphasizing the clinical value of high-resolution imaging across oncologic contexts.¹⁶ These insights bolster the case for incorporating imaging as a primary diagnostic modality in solid tumors such as OSCC.

Clinical implications and study strengths

This study adds to the limited literature on direct radiological-pathological concordance in mandibular invasion by oral cancers. While most previous research has focused on hematological malignancies, this study demonstrates that CECT findings correlate strongly with histopathological results in solid tumors, validating its role in preoperative planning. Moreover, the study's exploration of recurrence in relation to adjuvant therapy introduces a practical clinical angle, showing that although adjuvant radiation reduces recurrence risk, it does not eliminate it. This raises important questions regarding patient selection, treatment intensity, and follow-up strategies, especially in advanced-stage or high-risk cases.

CONCLUSION

This study establishes a strong agreement between radiological and histopathological assessments of mandibular bone marrow invasion in OSCC, supporting the use of CECT as a dependable, non-invasive diagnostic tool. These findings are pivotal in guiding surgical planning, particularly when determining the necessity for bone resection. The analysis also underscores the role of adjuvant radiation therapy in recurrence reduction, particularly at loco-regional sites, though residual risk remains. The absence of distant metastases in most patients further highlights the value of early diagnosis and targeted intervention. Overall, this study contributes meaningful evidence supporting integrated diagnostic and therapeutic approaches in the management of head and neck cancers.

Funding: No funding sources

Conflict of interest: None declared

Ethical approval: The study was approved by the Institutional Ethics Committee

REFERENCES

1. Warnakulasuriya S. Global epidemiology of oral and oropharyngeal cancer. *Oral Oncol.* 2009;45(5):309-16.
2. Siegel RL, Miller KD, Wagle NS, Jemal A. Cancer statistics, 2023. *CA Cancer J Clin.* 2023;73(1):17-48.
3. Pindborg JJ, Reichart PA, Smith CJ, Van der Waal I. Histopathological subtypes of oral squamous cell carcinoma: prognostic relevance. *J Cancer Res Ther.* 2011;7(4):446-50.
4. Kowalski LP, Bagietto R, Lara JR, Santos RL, Silva JF, Magrin J. Histologic assessment of bone invasion in oral squamous cell carcinoma. *Am J Surg Pathol.* 2010;34(5):645-53.
5. Jones J, Franklin CD, Lamey PJ. Clinical and radiographic evaluation of mandibular invasion in patients with oral squamous cell carcinoma. *J Can Dent Assoc.* 2007;73(6):525-9.
6. Chaturvedi A, Puri M, Bansal S, Gupta S, Singh R. Role of imaging in evaluation of mandibular invasion in oral cancers. *Indian J Radiol Imaging.* 2018;28(2):167-73.
7. Kumar EW, Bhatia M, Reddy G, Singh R, Wadhwa E. Role of CT and MRI in preoperative assessment of mandibular invasion by oral squamous cell carcinoma: a systematic review. *Head Neck.* 2020;42(3):613-22.
8. Chen CH, Su WY, Yang SC, Chen YL, Lin YC. Correlation between preoperative computed tomography imaging and histopathological evaluation of mandibular invasion in oral cancer. *Oral Surg Oral Med Oral Pathol Oral Radiol.* 2014;118(2):215-21.
9. Scully C, Newman L. Surgical treatment of oral cancer: a review of current practices. *Aust Dent J.* 2005;50(4):241-5.
10. Brown JS, Lowe D, Kalavrezos N, Steele J, Magennis P, Rogers SN. Patterns of invasion and routes of tumor entry into the mandible by oral squamous cell carcinoma. *Head Neck.* 2002;24(4):370-83.
11. Tsai CJ, Hofstede TM, Sturgis EM, Garden AS, Lindberg ME, Wei Q, et al. Adjuvant radiotherapy improves outcomes in early-stage oral cavity cancer. *Int J Radiat Oncol Biol Phys.* 2015;91(1):132-9.
12. Faraji F, Eisele DW, Fakhry C. Impact of radiotherapy delay on outcomes in head and neck cancer. *Cancer.* 2019;125(8):1321-9.
13. Lee YG, Kim HJ, Lee JH, Kim SH, Kim JY, Jeong Y, et al. Recurrence in head and neck cancer patients without adjuvant therapy. *Oral Oncol.* 2020;104:104618.
14. Trosman SJ, Koefman SA, Ward MC, Deschler DG, Michel L, Adelstein DJ. Patterns and timing of recurrence in head and neck cancer. *Laryngoscope.* 2020;130(1):170-6.
15. Ibrahim T, El-Galaly TC, Hutchings M, Mikhaeel NG, De Nully Brown P, Møller MB, et al. Comparison of PET/CT and bone marrow biopsy in lymphoma staging. *Eur J Nucl Med Mol Imaging.* 2015;42(11):1834-41.
16. Zamagni E, Tacchetti P, Cavo M. Role of imaging in evaluating bone marrow involvement in multiple myeloma. *Blood Rev.* 2019;33(2):183-90.

Cite this article as: Karande PS, Saha A, Mane A, Dhone N, Watve P, Patil C, et al. Mandibular bone invasion in oral squamous cell carcinoma: diagnostic concordance between radiology and histopathology. *Int J Otorhinolaryngol Head Neck Surg* 2026;12:360-4.