

Case Report

Follicular carcinoma thyroid presenting as skull metastasis: a rare case report

Manju P. Antony¹, Meer M. Chisthi^{2*}, Tessy P. Joseph³

¹Department of General Surgery, Government Medical College, Ernakulam, Kerala, India

²Department of General Surgery, Government Medical College, Trivandrum, Kerala, India

³Department of Pathology, Government Medical College, Ernakulam, Kerala, India

Received: 31 May 2015

Accepted: 24 June 2015

*Correspondence:

Dr. Meer M. Chisthi,

E-mail: meerschisthi@gmail.com

Copyright: © the author(s), publisher and licensee Medip Academy. This is an open-access article distributed under the terms of the Creative Commons Attribution Non-Commercial License, which permits unrestricted non-commercial use, distribution, and reproduction in any medium, provided the original work is properly cited.

ABSTRACT

Follicular cancer is the second commonest form of differentiated thyroid malignancy. Unlike papillary cancer which has a predilection for lymph node metastases, it spreads more often by the hematological route. Even when they have spread to various organs, differentiated thyroid cancers have excellent prognosis if they can be resected completely. One of the presentation of metastases from follicular cancer is with pulsatile skull metastases. Here, we are reporting the clinical details of an elderly lady who presented with a swelling in the skull of 1 month duration. She had an otherwise asymptomatic thyroid swelling of 18 years duration also. Radiology revealed a lytic lesion on the skull. Cytological confirmation was done to diagnose follicular cancer with skull bone metastasis. After total thyroidectomy surgery, she was sent for radio-active iodine ablation and levothyroxine suppression. We are presenting this case as it is not a common form of presentation of this disease.

Keywords: Differentiated thyroid cancer, Follicular thyroid cancer, Metastasis, Osteolytic

INTRODUCTION

Thyroid cancers account for around 0.5% of all cancers in males and 1.5% of all cancers in females. Follicular thyroid carcinoma is the second most frequent malignancy of the thyroid gland after papillary carcinoma. These are usually slow growing tumours and have a high propensity for blood borne metastasis. Distant spread may occur to bones, lungs, brain, skin and sometimes kidneys and adrenal glands. According to literature, the reported incidence of distant metastasis is between 10% and 25%, but it is very uncommon for the disease to present with distant metastasis at initial presentation itself.¹ Skull metastases are often from primaries of lung, breast and prostate malignancies but are rare from thyroid carcinomas. From available data, around 2.5% to 5% of cases of thyroid cancers may spread to the skull.² In almost all the reported cases of follicular thyroid carcinoma metastasizing to the skull,

metastases occurred long after the diagnosis and institution of treatment for primary cancer, and there have been only a handful of cases in the literature in which solitary skull metastasis was the presenting feature of a follicular thyroid cancer. We report such a case of a patient who presented as skull swelling and was diagnosed as metastatic lesion from follicular thyroid carcinoma. After undergoing successful treatment at our institution, she is under follow-up and doing well.

CASE REPORT

The patient, a 60 years old female hailing from rural part of South India presented to the Surgical out-patient department with complaints of swelling in the left side of head of 1 month duration. The patient complained that the swelling was rapidly growing in size but not causing pain or any other distressing symptom. On taking a detailed history, she revealed that she was having a

swelling in the neck for about 18 years. Since she did not have any symptom associated with the swelling, she had not undergone any evaluation for the same and was not under any medication for the same. Also, she had not noticed any recent increase in the size of the neck swelling. Apart from these, the patient had no symptoms suggestive of pressure on neck structures, no features of toxicity and no features of any swellings elsewhere in the body. As for comorbidities, the patient was on medications for diabetes mellitus and psychiatric illness, both of which were under adequate control.

On examination, the patient was found to have a spherical shaped, well circumscribed swelling in the left frontal region of skull, of about 20 x 20 cm size and with smooth surface (Figure 1). The swelling was found to be hard, immobile and fixed to underlying bone. There was no appreciable pulsations or cough impulse over the swelling. On examining the neck, a 10 x 7 cm sized goiter was found. The gland was multinodular in morphology and there was a discrete area measuring 4 x 4 cm on the left side which was hard in consistency and had restricted mobility. There was no sign of any retrosternal extension. There were no palpable regional lymph nodes. The trachea was found shifted to the right side. There were no features of carotid compression. All the other systems including the respiratory and central nervous systems were found to be normal.

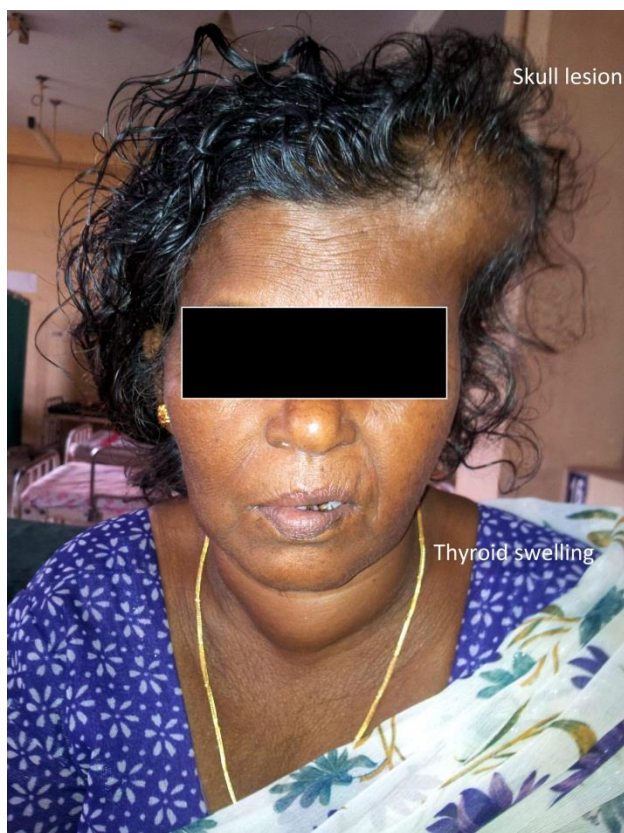

Figure 1: Photo showing the skull lesion and thyroid swelling.

The patient underwent thyroid function test which revealed normal values and euthyroid status. An X-ray of the skull was done and revealed a discrete osteolytic lesion in the frontal bone on the left side (Figure 2). CT scan revealed no dural defects or intracranial lesions. Lateral view x-ray of the neck showed tracheal shift to the right side (Figure 3). An ultrasound of the neck was done and the report was given as 'Multi-nodular goiter involving both lobes of the thyroid gland, with a hypo-echoic area suspicious area of differentiated thyroid malignancy in the left lobe'. There were no detectable lymph nodes in the neck. A Fine Needle Aspiration Cytology (FNAC) of the nodule was requested and was reported with a diagnosis of Follicular neoplasm (Figure 4). FNAC of the skull lesion suggested a possibility of metastases from differentiated thyroid neoplasm (Figure 5). Chest X-ray and other routine investigations were all within normal limits. Based on these findings, the patient was diagnosed as Follicular thyroid carcinoma with skull metastases.

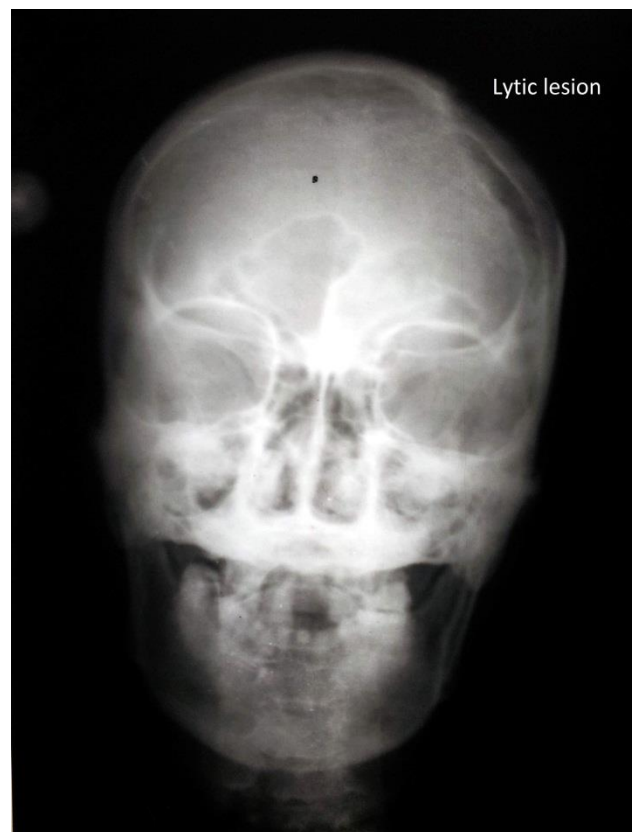

Figure 2: X-ray skull showing lytic lesion.

After discussing with the radiation oncologist, the patient was taken up for thyroidectomy. Intra-operatively the gland was found to have multiple nodules, with a 3 x 3 cm hard nodule in the left lobe. There were no features of infiltration to adjacent neck structures nor were there any lymph nodes. Total thyroidectomy was done and the post-operative period was uneventful. Following suture removal she was sent with levo-thyroxine suppression. Later nuclear iodine scan was done and picked up the

area of iodine-avid metastasis in the left frontal skull. Hence the patient was subjected to ablation with radioactive iodine. She was kept under follow up and serially assessed with clinical examination and serial thyroglobulin estimation.

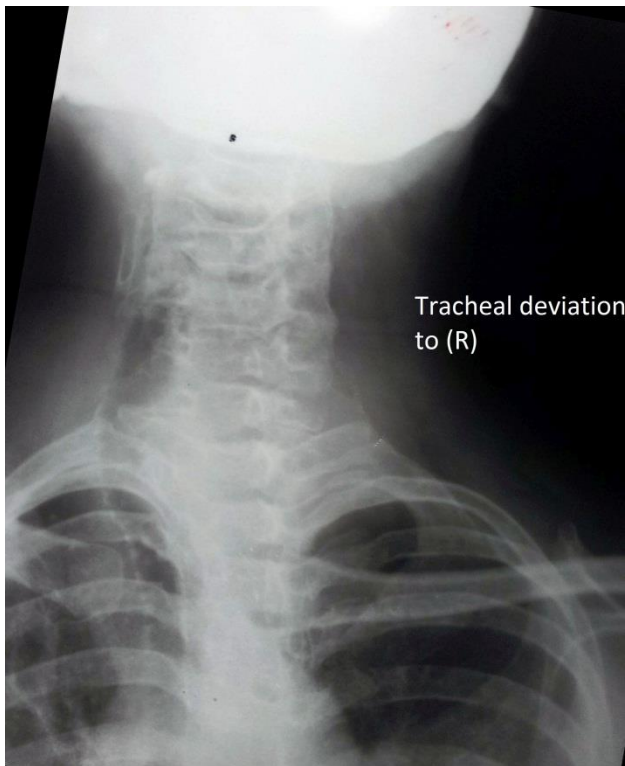


Figure 3: X-ray neck showing tracheal deviation.

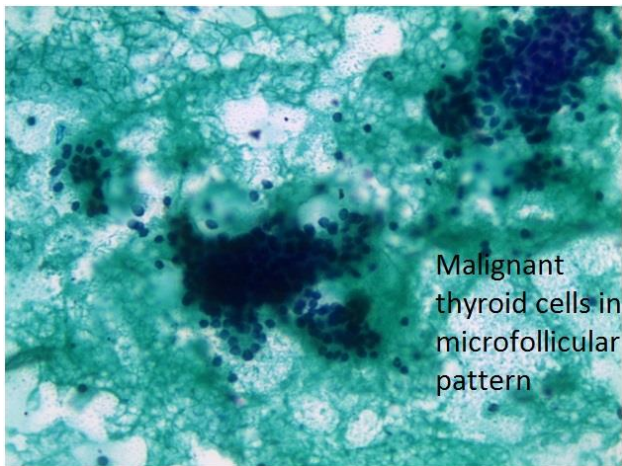


Figure 4: FNAC thyroid showing malignant follicular cells.

While she was on follow up, there were no features of local or distant disease recurrence. At 1 year of follow up she was found to be asymptomatic, the neck showing no signs of local recurrence. Also, the skull lesion was found to be abating in size. Hence she is being continued on the same treatment protocol.

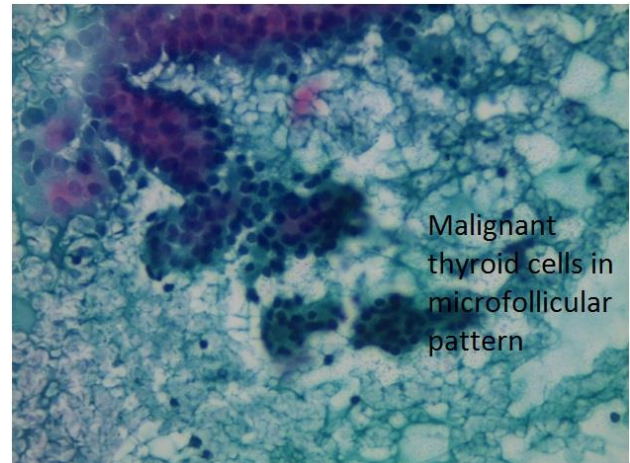


Figure 5: FNAC skull swelling showing metastatic thyroid cells.

DISCUSSION

Thyroid tumours are more prevalent in females with a female to male ratio of 2.6:1. Among the various subtypes, follicular carcinoma is the second most frequent malignancy of thyroid gland after papillary carcinoma. Follicular thyroid carcinoma occurs in much older age group than papillary i.e. in the 40 to 60 years of age group.³ This carcinoma is generally seen in elderly females, primarily having longstanding non-toxic multinodular goitre (50.2%), solitary thyroid nodule (44.2%) and rarely in patients with endemic goitre.⁴ This type of neoplasm is probably induced by chronically elevated Thyroid-Stimulating Hormone (TSH) levels. Follicular cancers are slow growing tumours. Unlike papillary cancers, FTC metastasizes to lymph nodes in very few patients, with only 5% to 10% of patients having nodal metastasis at the time of diagnosis.

Hematogenous spread is however much more common in FTC with almost 20% of patients having distant hematogenous metastasis at the time of presentation. Although lungs and bones are commonly involved sites by metastasis, the brain, skin, liver, adrenal gland and even mediastinum may also be involved by thyroid cancers.⁵ There are reported cases of metastases from follicular carcinoma to the kidneys and even the choroid of the eye.⁶ Among bones, skull is a rare site for metastasis. There is a report of metastasis to pituitary from follicular carcinoma, which required trans-sphenoidal surgical decompression.⁷ Interestingly, there is a rather unique report of tumour-to-tumour metastasis in which skull metastasis from follicular carcinoma thyroid was secondarily involved with diffuse large B-cell lymphoma.⁸

The largest case series of skull metastases from all types of thyroid cancers consists of 12 cases reported by Nagamine et al.² In this series, mean time from the diagnosis of thyroid tumour until discovery of skull metastasis was 23.3 years. Skull metastases from thyroid

cancers are usually soft, hemispheric tumours resting on the skull. These tumours are usually highly vascular, with evident osteolytic changes in the skull. The commonest mode of presentation of skull metastases from follicular cancer is as pulsatile skull swellings. Very rarely, there can be features of cranial nerve dysfunction, focal brain symptoms or symptoms due to increased intracranial pressure. Histologically these lesions can demonstrate well differentiated follicular adenocarcinoma. Immunohistochemical studies of Thyroid Transcription Factor-1 (TTF-1) and thyroglobulin (TG) are useful for distinguishing between metastasis from thyroid carcinoma and other adenocarcinomas.⁹ These lesions are osteolytic on skull X-ray and CT scan and highly vascular on angiographic assessment.¹⁰

One of the significant problems in skull metastases is the bone defect which may require bone resection and cranioplasty. Most of these tumours are highly vascular, and there is potential for significant morbidity and mortality associated with surgical resection. As per general recommendations, histo-pathologic tissue diagnosis should always be attempted, followed by total thyroidectomy, radioiodine ablation, or external beam radiation, and chronic thyroid stimulating hormone suppression. However, experts recommend that surgical resection of the metastatic lesion should only be performed in carefully selected cases because of the associated morbidity.¹¹

The effectiveness of Iodine-131 (I-131) in bone metastases treatment is suboptimal. Even in patients who have bone metastases that avidly take up I-131, only a very small proportion is able to achieve complete response following I-131 therapy. Bone metastases associated with radiographic changes are particularly known not to respond well to I-131 therapy. Also, high doses of radioactive iodine have been linked to an increased risk of leukaemias as well as bone, soft tissue, colorectal, and salivary gland cancers.¹² Radiation induced pulmonary fibrosis in patients with pulmonary metastases after repeated I-131 doses is also a potential risk, albeit rarely reported. In addition to thyroidectomy and I-131 treatment, studies also support the use of external beam radiation therapy (EBRT) for loco-regional control of inoperable metastases.¹³ Bisphosphonates which have been used widely to control bone metastasis of solid tumours such as breast and prostate cancers, have also been reported in some patients with skull metastases from thyroid cancers.¹⁴

Although the incidence of papillary thyroid carcinoma is much higher than of follicular carcinoma, the latter accounts for more deaths.¹⁵ The prognosis of FTC is not as extremely favourable as papillary, but much better than anaplastic thyroid cancer or other cancers in the body. Prognosis commonly depends on the presence and extent of distant metastatic disease. In locally limited disease, 90% ten year survival can be expected, whereas with distant disease that value drops to below 50%. Thus

aggressiveness of FTC varies widely and metastatic disease is touted to be the primary cause of death. In summary, metastasis from differentiated thyroid malignancy should always be suspected in patients who present with suspicious skull metastases. After confirmation such patients should undergo thyroidectomy and radio-iodine ablation or external irradiation for the metastases as they can have a good prognosis.

ACKNOWLEDGMENTS

The authors would like to thank the General Surgery departments of Government Medical College, Ernakulam and Government Medical College, Trivandrum and all the faculty, for their support in reporting this observation.

Funding: No funding sources

Conflict of interest: None declared

Ethical approval: Not required

REFERENCES

1. Shaha AR, Shah JP, Loree TR. Differentiated thyroid cancer presenting initially with distant metastasis. *Am J Surg.* 1997;174:474-6.
2. Nagamine Y, Suzuki J, Katakura R, Yoshimoto T, Matoba N, Takaya K. Skull metastasis of thyroid carcinoma. Study of 12 cases. *J Neurosurg.* 1985;63:526-31.
3. Shah S, Muzaffar S, Soomro I, Hasan S. Morphological pattern and frequency of thyroid tumours. *J Pak Med Assoc.* 1999;49:131-3.
4. Rao RS, Parikh HK. Prognostic factors in well-differentiated carcinoma of thyroid. In: Shah DH, Samuel AM, Rao RS, eds. *Thyroid Cancer - An Indian Perspective.* 1st ed. Mumbai, India: Quest Publications; 1998: 443-450.
5. Schlumberger M, Tubiana M, De Vathaire F, Hill C, Gardet P, Travagli JP, et al. Long term results of treatment of 283 patients with lung and bone metastases from differentiated thyroid carcinoma. *J Clin Endocrinol Metab.* 1986;63:960-7.
6. Guignier B, Naoun O, Subilia A, Schneegans O. Choroidal metastasis from follicular thyroid carcinoma: a rare case. *J Fr Ophtalmol.* 2011 May;34(5):329.e1-5.
7. Prodham F, Pagano L, Belcastro S, Golisano G, Busti A, Samà M, et al. Pituitary metastases from follicular thyroid carcinoma. *Thyroid.* 2010 Jul;20(7):823-30.
8. Ji Lu, John L. Frater, Friederike H. Kreisel, Joseph N. Marcus, Anjum Hassan. Secondary lymphoma involving metastatic follicular thyroid carcinoma to the skull: a unique example of tumour-to-tumour metastasis. *Head Neck Pathol.* 2008;2:209-12.
9. Sathiyamoorthy S, Maleki Z. Cytomorphologic overlap of differentiated thyroid carcinoma and lung adenocarcinoma and diagnostic value of TTF-1 and TGB on cytologic material. *Diagn Cytopathol.* 2014 Jan;42(1):5-10.

10. Akdemir I, Erol FS, Akpolat N, Ozveren MF, Akfirat M, Yahsi S. Skull metastasis from thyroid follicular carcinoma with difficult diagnosis of the primary lesion. *Neurol Med Chir (Tokyo)*. 2005;45:205-8.
11. Mydlarz WK, Wu J, Aygun N, Olivi A, Carey JP, Westra WH, et al. Management considerations for differentiated thyroid carcinoma presenting as a metastasis to the skull base. *Laryngoscope*. 2007 Jul;117(7):1146-52.
12. de Vathaire F, Schlumberger M, Delisle MJ, Francesc C, Challeton C, de la Genardiére E, et al. Leukaemias and cancers following iodine-131 administration for thyroid cancer. *Br J Cancer*. 1997;75:734-9.
13. Meadows KM, Amdur RJ, Morris CG, Villaret DB, Mazzaferri EL, Mendenhall WM. External beam radiotherapy for differentiated thyroid cancer. *Am J Otolaryngol*. 2006;27:24-8.
14. Tassinari D, Poggi B, Nicoletti S, Fantini M, Tamburini E, Possenti C, et al. Zoledronic acid treatment at home: safety data from an observational prospective trial. *J Palliat Med*. 2007;10:352-8.
15. Grebe SK, Hay ID. Follicular thyroid cancer. *Endocrinol Metab Clin North Am*. 1995;24:761-801.

Cite this article as: Antony MP, Chisthi MM, Joseph TP. Follicular carcinoma thyroid presenting as skull metastasis: a rare case report. *Int J Otorhinolaryngol Head Neck Surg* 2015;1:40-4.