International Journal of Otorhinolaryngology and Head and Neck Surgery
Fathima MAM et al. Int J Otorhinolaryngol Head Neck Surg. 2026 Dec;12(6):1028-1030
https://www.ijorl.com
pISSN 2454-5929 | eISSN 2454-5937

DOI: https://dx.doi.org/10.18203/issn.2454-5929.ijohns20264287

Case Report

Fungus cerebri presenting as tegmen defect in chronic otitis media: a case report

Mishal Fathima M. A.*, Amol Anandrao Patil, Jaini Lodha Bhandari

Department of Otorhinolaryngology, Nanavati Max Super Speciality Hospital, Mumbai, Maharashtra, India

Received: 12 May 2026
Revised: 05 July 2026
Accepted: 23 September 2026

***Correspondence:**
Dr. Mishal Fathima M. A.,
E-mail: mishalfathima@icloud.com

Copyright: © the author(s), publisher and licensee Medip Academy. This is an open-access article distributed under the terms of the Creative Commons Attribution Non-Commercial License, which permits unrestricted non-commercial use, distribution, and reproduction in any medium, provided the original work is properly cited.

ABSTRACT

Meningoencephalic herniation into the middle ear and mastoid cavity, historically termed fungus cerebri, is a rare but potentially serious otologic condition. It may arise secondary to chronic otitis media, cholesteatoma, trauma, congenital skull base defects, or previous otologic surgery. Delayed diagnosis can lead to cerebrospinal fluid (CSF) leak, meningitis, intracranial abscess, seizures, and hearing loss. We report the case of a 43-year-old female who presented with left ear discharge, tinnitus, and conductive hearing loss. High-resolution computed tomography (HRCT) temporal bone revealed soft tissue disease in the middle ear and mastoid with a 5 mm tegmen tympani defect and exposed temporal lobe dura. The patient underwent transmastoid exploration and cortical mastoidectomy. No active CSF leak or brain prolapse was identified intraoperatively. The tegmen defect was repaired using periosteum. Recovery was uneventful, and the patient remained symptom-free without recurrence at 6-month follow-up. Early imaging, high clinical suspicion, and timely surgical repair are essential to prevent life-threatening complications.

Keywords: Fungus cerebri, Meningoencephalocele, Tegmen defect, Chronic otitis media, Mastoidectomy

INTRODUCTION

Temporal bone meningoencephalocele refers to herniation of meninges with or without brain tissue through a defect in the skull base into the middle ear or mastoid cavity. Historically, the term fungus cerebri has been used for such protrusions of cerebral tissue through cranial defects. Although uncommon, it is an important entity in otology because of the risk of meningitis, CSF otorrhea, conductive hearing loss, seizures, and intracranial infection.[1,2]

Common etiologies include chronic suppurative otitis media (CSOM), cholesteatoma, trauma, congenital tegmen dehiscence, raised intracranial pressure, and previous otologic surgery such as mastoidectomy.[3] The most frequent sites are the tegmen tympani and tegmen antri. Imaging with HRCT and magnetic resonance imaging (MRI) plays a central role in diagnosis and surgical planning.

Here a case of tegmen defect with exposed temporal lobe dura in a patient with chronic ear disease managed successfully by transmastoid repair has been presented.

CASE REPORT

A 43-year-old female presented on 16 January 2024 with complaints of left ear discharge for 6 months. The discharge was insidious in onset, scanty, mucopurulent, non-foul smelling, and non-blood stained. She also complained of decreased hearing and tinnitus in the left ear. There was associated history of cold and bilateral nasal obstruction.

On admission, the patient was afebrile, with stable pulse and blood pressure. Otoscopic examination of the left ear revealed a small perforation in the posteroinferior quadrant with a retraction pocket. No signs suggestive of intracranial complications were present. Tuning fork tests suggested left-sided conductive hearing loss with negative fistula test. Right ear examination was normal. Bilateral facial nerve function was intact. The remainder of ENT and head and neck examination was unremarkable.

Pure tone audiometry demonstrated moderate conductive hearing loss in the left ear.

HRCT temporal bone showed abnormal soft tissue in the left middle ear cavity involving Prussak's space and left mastoid air cells with loss of mastoid air cell trabeculae. The left tympanic membrane was thickened and retracted with suggestion of a small perforation. A large bony defect measuring approximately 5 mm was noted in the left tegmen tympani/roof of the middle ear cavity, through which temporal lobe dura appeared exposed.

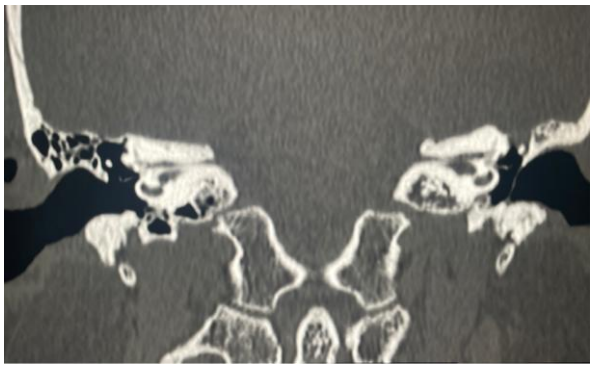

Figure 1: ???????????



Figure 2: ???????????

Based on clinical and radiological findings, a diagnosis of tegmen defect with impending meningoencephalic herniation (fungus cerebri) was made.

The patient underwent surgery under general anesthesia through a postaural transmastoid approach. Cortical mastoidectomy was performed. The tegmen defect was identified and assessed. No active CSF leak or obvious brain prolapse was noted intraoperatively. Neurosurgical opinion was obtained intraoperatively. The defect was repaired using autologous periosteum.

The postoperative period was uneventful. The patient was discharged on postoperative day 3 with mastoid dressing, which was removed on postoperative day 7. At 6-month follow-up, she remained asymptomatic with no evidence of recurrence.

DISCUSSION

Temporal bone meningoencephaloceles require both a bony defect and dural breach to permit herniation of intracranial contents into the temporal bone. Defects involving the middle cranial fossa floor are more common than posterior cranial fossa lesions.[4]

In chronic otitis media with cholesteatoma, tegmen erosion may occur due to pressure necrosis, osteoclastic activity, inflammatory mediators, and enzymatic bone destruction.[5] Previous mastoid surgery is another recognized cause due to iatrogenic dural or bony injury.

Patients may present with hearing loss, persistent otorrhea, aural polyp, pulsatile middle ear mass, CSF leak, recurrent meningitis, seizures, or headache.[6] In our patient, presentation was relatively subtle, consisting mainly of chronic ear discharge and conductive hearing loss.

HRCT accurately demonstrates tegmen defects and associated mastoid disease, while MRI is useful to differentiate meningoencephalocele from cholesteatoma or granulation tissue.[7]

The choice of surgical approach depends on size and location of the defect. Small lateral or posterior tegmen defects may be repaired by transmastoid approach, while anterior, medial, multiple, or large (>2 cm) defects may require middle cranial fossa or combined approach.[8] Repair materials include temporalis fascia, cartilage, bone pate, muscle, periosteum, hydroxyapatite cement, titanium mesh, and fibrin glue.

In our case, the defect was small (5 mm) and laterally accessible, making transmastoid repair appropriate. No postoperative complications such as CSF leak, seizures, sensorineural hearing loss, or infection were observed.

CONCLUSION

Fungus cerebri or temporal bone meningoencephalocele is a rare but significant complication of chronic ear disease or prior otologic surgery. A high index of suspicion, appropriate imaging, and timely surgical

intervention are necessary to prevent potentially life-threatening intracranial complications. Transmastoid repair remains an effective option for selected small tegmen defects.

Funding: No funding sources
Conflict of interest: None declared
Ethical approval: Not required

REFERENCES

1. Neely JG. Cerebrospinal fluid otorrhea and meningoencephalocele of the temporal bone. Laryngoscope. 1983;93(3):314-21.
2. Gacek RR, Leipzig B. Meningoencephalocele of the temporal bone. Ann Otol Rhinol Laryngol. 1979;88(4):490-6.
3. Sanna M, Falcioni M, Russo A, Taibah A. Management of meningoencephalic herniation of the temporal bone. Otol Neurotol. 2001;22(3):330-5.
4. Biscione GL, de Souza RP, et al. Temporal bone encephaloceles: diagnosis and treatment. Int Arch Otorhinolaryngol. 2015;19(2):178-83.
5. Sudhoff H, Tos M. Pathogenesis of sinus cholesteatoma. Eur Arch Otorhinolaryngol. 2007;264(10):1137-43.
6. Isaacson B, Kutz JW Jr, Roland PS. Transmastoid repair of spontaneous temporal bone encephaloceles. Otol Neurotol. 2011;32(4):629-33.
7. Brackmann DE, Shelton C, Arriaga MA. Otologic skull base defects and encephaloceles. Am J Otol. 1994;15(1):38-42.
8. Marchioni D, Alicandri-Ciufelli M, et al. Combined transmastoid-middle cranial fossa approach for tegmen defects. Acta Otorhinolaryngol Ital. 2014;34(5):336-42.

Cite this article as: Fathima MAM, Patil AA, Bhandari JL. Fungus cerebri presenting as tegmen defect in chronic otitis media: a case report. Int J Otorhinolaryngol Head Neck Surg 2026;12:1028-30.