

Original Research Article

Malignant external otitis: about 50 cases at Fann hospital center

Mame Sanou Diouf^{1*}, Mouhamed Barry¹, Moustapha Ndiaye¹, Abdourahmane Tall²,
Ciré Ndiaye², Malick Ndiaye², Fallou Niang², Cheikh Diene Niang², Faty Fall¹

¹Department of ENT, HOGIP Hospital Center, Dakar, Senegal

²Department of ENT, Fann Hospital Center, Dakar, Senegal

Received: 01 November 2023

Revised: 20 December 2023

Accepted: 30 December 2023

***Correspondence:**

Mame Sanou Diouf,

E-mail: sanou29@hotmail.com

Copyright: © the author(s), publisher and licensee Medip Academy. This is an open-access article distributed under the terms of the Creative Commons Attribution Non-Commercial License, which permits unrestricted non-commercial use, distribution, and reproduction in any medium, provided the original work is properly cited.

ABSTRACT

Background: Malignant external otitis (MEO) is an osteitis of the skull base, originating in the external auditory canal. It is most common in elderly and diabetic patients. Early management prevents complications. The objective of the study is to provide an epidemiological, clinical, paraclinical, therapeutic and evolutionary profile.

Methods: From January 2010 to January 2021, we carried out a retrospective study in the ENT department of Fann hospital, selecting the patients hospitalized and suffering from malignant external otitis

Results: Fifty patients were included in this study. The mean age was 65, with a sex ratio (M/F) of 1.5. Forty-six patients were diabetic; 2 patients had leukemia and 2 had no previous history. The average length of hospital stay was 3 months. The reasons for consultation were otalgia, otorrhea and deafness in 96%, 80% and 32% respectively. Examination revealed otorrhea in 58%, peripheral facial paralysis in 54% and a polyp in 80%. Ear swab analysis isolated *Pseudomonas aeruginosa* in 28%. CT scan showed ear cavity filling in 40 cases and bone lysis in 26. Antibiotic treatment was based on ciprofloxacin or ofloxacin in 44% of cases, and the combination of ceftriaxone-ciprofloxacin or ofloxacin in 44%. The average duration of treatment was 3 months. There were 12% recurrences and 2 cases of death after an average follow-up of 10 months.

Conclusions: MEO is a rare pathology that occurs more frequently in elderly subjects with immunodepressive backgrounds. Antibiotic therapy has proved effective in treating this condition.

Keywords: Malignant otitis, Diabetes, External ear

INTRODUCTION

Malignant external otitis (MEO) is an osteitis of the skull base, starting as an infection of the external acoustic meatus with contiguous infection of the temporal bone that can spread to the skull base, causing progressive bone erosion, cranial nerve damage, venous thrombosis, abscess and even death.¹ It is more common in immunocompromised or elderly diabetic subjects. The most common germ is *Pseudomonas aeruginosa*.^{1,2} Other germs may be involved, such as *Staphylococcus aureus*,

Staphylococcus epidermidis, *Proteus mirabilis*, *Klebsiella oxytoca* and fungi.² The diagnosis of MEO should be suspected on the basis of clinical, biological and radiological evidence. Diagnostic criteria have been established by some authors.^{3,4} Initially managed surgically, MEO can now be treated effectively with antibiotics, with surgery reserved for biopsy and local debridement.^{2,5} Although MEO has been known since the work of Chandler et al in 1968, to date there is no consensus on the diagnostic criteria and duration of antibiotic therapy.⁶

Aim and objectives

The main aim of our study is to investigate the epidemiological, clinical, paraclinical and therapeutic profile of MEO in the ENT department of Fann hospital center.

METHODS

From January 2010 to January 2021, we conducted a retrospective, monocentric, descriptive study in the ENT department of Fann hospital center. All patients hospitalized for MEO with supporting CT scan and bacteriological examination were included, and patients with incomplete or untraceable records were excluded. The parameters studied were age, sex, reason for and delay in consultation, history, clinical and paraclinical examination data, treatment and course. Data analysis was carried out with SPSS software version 23. Microbial samples were taken with a swab.

RESULTS

Fifty cases were included in this study. The mean age of the patients was 65 years, with extremes of 20 and 86 years. They were predominantly male, with a sex ratio of 1.5 (M/F).

Table 1: Physical examination.

Physical examination	N	%
Otorrhea	29	58
Peripheric facial paralysis	27	54
External ear canal polyp	40	80
Inflammatory external ear canal	13	26
Paralysis of IX, X et XII	2	4
lockjaw	1	2
Foreign body	1	2
Swelling	Temporo-zygomatic	4 8
	Pre-auricular	5 10
	Retro-auricular	2 4
	Parotid region	1 2
	Hemiface	1 2
Tympan	Normal	3 6
	Inflammatory	9 18
	Not seen	36 72
	Perforated	2 4

Forty-six patients were diabetic, 2 had leukemia and the other 2 had no history of diabetes. The average consultation time was 3 months. Otagia was present in 96% of cases, followed by otorrhea in 80% (Figure 1).

On examination, otorrhea was noted in 58%, peripheral facial palsy (PFP) in 54% and a polyp in 80% (Table 1). CT scan showed filling in 80% of cases and bone lysis in 60% (Table 2). Ear swab analysis isolated *Pseudomonas aeruginosa* in 28% (Table 3).

Table 2: TDM scan.

TDM	N	%
Filling image	Mastoid	16 32
	External ear	10 20
	Middle ear	14 28
Lysis image	Tympanal	11 22
	Mastoid	7 14
	Temporal bone	5 10
	Middle ear wall	3 6
	External auditory canal bone walls	4 8

Table 3: Germs.

Germs	N	%
<i>Pseudomonas aeruginosa</i>	14	28
Fungi	<i>Candida Albicans</i>	4 8
	<i>Candida Tropicalis</i>	1 2
	<i>Candida parapsilosis</i>	1 2
	<i>Aspergillus sp</i>	1 2
	Autres levures (other fungi)	2 4
Other bacteria	<i>Streptococcus D</i>	1 2
	<i>Escherichia coli</i>	1 2
	<i>Klebsiella pneumoniae</i>	3 6
	<i>Enterobacter</i>	2 4
	<i>Staphylococcus aureus</i>	4 8
Absence of germs	16	32

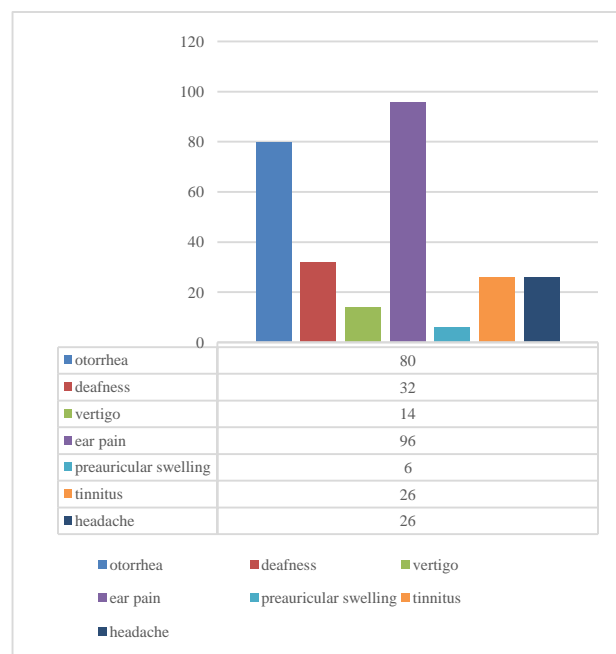


Figure 1: Reasons for consultation.

A non-specific biological inflammatory syndrome was found in 42% of cases. Medical treatment was based on ciprofloxacin or ofloxacin in 44%, and the combination of ceftriaxone and ciprofloxacin (or ofloxacin) in 44% of cases (Table 4).

Table 4: Treatment.

Treatment	N	%	
IV Antibiotics	Ciprofloxacin	20	40
	Ofloxacin	2	4
	Ciprofloxacin + ceftriaxone	16	32
	Ofloxacin + ceftriaxone	6	12
	Imipenem	1	2
	ceftriaxone + metronidazole + gentamycin	1	2
	Lincomycin + amykacin	1	2
	Ciprofloxacin + amykacin	1	2
Analgesics	Paraceamol	35	70
	Paracetamol + nefopam	8	16
	Paracetamol + tramadol	4	8
Polyp excision	10	20	
Calibration of external auditory canal	13	26	
Ear drops	37	74	
Kinesitherapy	12	24	
Antifungal (fluconazole tablet)	6	12	

The average duration of parenteral antibiotic treatment was 25 days. Oral antibiotic relay extended the total duration of treatment to an average of 3 months. After an average follow-up of 10 months, there were 6 cases of recurrence, 11 cases of PFP, 21 patients lost to follow-up, 3 cases of cophosis, 7 cases of cure and 2 cases of death. The circumstances of death were sepsis in 1 patient. The other patient died at home after hospitalization.

DISCUSSION

MEO has long been dismissed as a disease of the elderly or diabetics. Our results are in agreement (mean age 65, 92% diabetic patients). Otagia and purulent otorrhea are the main symptoms of this condition.^{7,8,9} There are also cases of nerve damage. The most common is facial nerve damage, which ranges from 7 to 46%.¹⁰ Nerve damage is more frequent in the paediatric population, at around 53%.¹¹ This factor increased mortality by 50%.¹² In our series, facial paralysis was found in 54% of cases. This high proportion may be correlated with the delay in diagnosis in our context. On physical examination, a polyp was found in the external ear canal (EEC) in 80% of cases. For Mahdyoun the sentinel polyp at the osteocartilaginous junction is pathognomonic of this condition, but for Long D.A, it may be absent at the onset of the disease, or in immunocompromised patients.^{10,13} If the eardrum is seen, it has a normal appearance in the majority of cases, as was the case in our study, where the eardrum was seen in 28% of cases, normal in 6% and inflammatory in 18%.^{10,13} Involvement of other cranial nerves (IX, X, XI, XII) is found in between 14% and 35% of cases, and indicates extension of the infection to the base of the skull.¹⁴ In our series, such involvement was found in 2 cases. *Pseudomonas aeruginosa* was the germ most frequently found in our series, as in several other studies.⁸ In our study, the low proportion of *P. aeruginosa* was related to the absence of germs in the

samples. Indeed, many patients had been treated with several antibiotics before coming for consultation. Long D.A have found that *P. aeruginosa* in this condition is declining in favour of other bacteria and fungi.^{10,15-18} In our series, fungi accounted for 18% of cases, and other bacteria for 22%. Fungal MEO in immunocompromised subjects, particularly diabetics, is serious, even fatal.¹⁹ Aspergillus and Candida are the fungal species most commonly implicated.¹⁰ A fungal origin should be considered in the event of failure of a 6-8 week course of antibiotics.¹⁰

CT scans may show bone lysis of the mastoid cortex or tympanum, associated with swelling of the soft tissues of the EEC.¹⁴ These lytic aspects were found in 26 cases in our series. MRI is the examination of choice for determining the extent of lesions, particularly in the soft tissues and bone marrow, and is useful in advanced forms.¹⁴ It was performed twice in our series and is not available in routine practice. *P. aeruginosa* is sensitive to fluoroquinolones, and the latter have excellent bone penetration, making them the usual first-line treatment.^{20,21} Ciprofloxacin is the most commonly used fluoroquinolone, used as monotherapy for 6 to 8 weeks.²² However, treatment of 4 to 6 weeks may be insufficient for patients at high risk of recurrent infections, such as those infected with methicillin-resistant *Staphylococcus aureus* (MRSA) and in end-stage renal disease.¹² *P. aeruginosa* resistance to fluoroquinolones varies considerably from one clinical context to another, with resistance rates as high as 30-33% in some settings.^{23,24} For fungal MEO, amphotericin B is the most commonly used, given its potential toxicity.¹⁰ In our series, we did not use this molecule as it was not available. Instead, we used oral fluconazole. External ear canal carcinoma is the main differential diagnosis, hence the need for systematic biopsies, especially in the event of failure of a well-administered course of antibiotics.²⁴ Sedimentation rate (SV) and CRP can be used to monitor response to treatment.¹⁰ Clinical criteria were pain sedation and disappearance of all inflammatory signs. CT and MRI scans were not used, as recommended in the literature. The mortality rate in our series was 4%. It varied from 3.1% to 8% depending on the series.^{3,4,17,20} Overall mortality has fallen from 30% to 40% in the past to less than 20% today, with rates close to 0% since the use of quinolones.¹⁴ Stevens SM have identified factors associated with a poor prognosis.²⁴ Nerve damage, especially multiple nerve damage, is evidence of an advanced form of the disease, which was virtually always fatal in the past, but still has a poor prognosis, particularly in Aspergillus forms or in AIDS patients.¹⁴

Limitations

Limitations of current study were; the negative microbial samples are due to the fact that the patients took antibiotics before their hospitalization. The samples may be contaminated and the germs found may be wrongly found.

CONCLUSION

In our study, MEO occurs mainly in diabetic subjects aged over 60 years. The main germ found is *Pseudomonas aeruginosa*. We also found other bacteria as well as fungi, hence the interest in systematically taking 2 samples for cytobacteriological and mycological examination. A multicenter study involving more patients could validate the results of this study.

Funding: No funding sources

Conflict of interest: None declared

Ethical approval: The study was approved by the Institutional Ethics Committee

REFERENCES

1. Bonfils P, Laccorre O, Couloigner V. Le livre de l'interne; ORL. 2nd ed. France: Lavoisier Médecine sciences; 2014.
2. Bathokedeou A, Essobozou P, Akouda P, Essohanam B, Eyawelohn K. Epidemiological, clinical and therapeutic aspects of otitis externa: about 801 cases. Pan Afr Med J. 2014;17:142.
3. Bruno G, Valentina KM, Santoro R, Cammaroto G, Galletti F, Cascio A. Malignant external otitis. A case series from an Italian Tertiary-Care Hospital. Acta Med Mediter. 2014;30(6):1317-23.
4. Nawas MT, Daruwalla VJ, Spierer D, Micco GA, Alan G, Nemeth AJ. Complicated necrotizing otitis externa. Am J Otolaryngol Head Neck Med Surg. 2013;34: 706-9.
5. Rubin GJ, Branstetter BF, Yu VL. The changing face of malignant (necrotizing) external otitis: clinical, radiological, and anatomic correlations. Lancet Infect Dis. 2004;4(1):34-9.
6. Chandler JR. Malignant external otitis. Laryngoscope. 1968;78(8):1257-94.
7. Sellem A, Cherif H, Ajmi W, Ben MR, Zgolli S, Akkari K, et al. Place des explorations isotopiques dans les otites externes nécrosantes. Méd Nucl. 2012; 45(1):40-5.
8. Gassab E, Krifa N, Sayah N, Khairredine N, Koubaa J, Gassab A. L'otite externe nécrosante progressive: à propos de 36 cas. Latunisie Med. 2011;89(2):151-6.
9. Abdeljelil M, Kooli I, Marrakchi W, Aouam A, Loussaief C, Toumi A, et al. Otite externe nécrosante chez le diabétique: aspects cliniques, thérapeutiques et évolutifs. Ann Endocrinol. 2020;81(4):4266.
10. Long DA, Koyfman A, Long B. An emergency medicine-focused review of malignant otitis externa. Am J Emerg Med. 2020;38(8):1671-8.
11. Rubin J, Yu VL, Stool SE. Malignant external otitis in children. J Pediatr. 1998;113(6):965-70.
12. Treviño GJL, Reyes SLL, Hernández de LJE. Malignant otitis externa: An updated review. Am J Otolaryngol. 2021;42(2):102894.
13. Mahdyoun P, Pulcini C, Raffaelli C. Necrotizing otitis externa: a systematic review. Otol Neurotol. 2013; 34(4):620-9.
14. Martel J, Guyo TM, Darrouzet V. Otites externes "malignes" ou nécrosantes progressives. Revue Lacomén. 1999;5(4):405-15.
15. Salit IE, Miller B, Wigmore M, Smith JA. Bacterial flora of the external canal in diabetics and non-diabetics. Laryngoscope. 1982;92(6):672-3.
16. Hobson CE, Moy JD, Byers KE, et al. Malignant otitis externa: evolving pathogens and implications for diagnosis and treatment. Otolaryngol Head Neck Surg. 2014;151(1):112-6.
17. Jacobsen LM, Antonelli PJ. Errors in the diagnosis and management of necrotizing otitis externa. Otolaryngol Head Neck Surg. 2010;143:506-9.
18. Lee SK, Lee SA, Seon SW. Analysis of prognostic factors in malignant external otitis. Clin Exp Otorhinolaryngol. 2017;10(3):228-35.
19. Halwani C, Zoghalmi I, Zgolli C, Harhira R, Akkari K, Ben Mhamed R, et al. Les otites externes nécrosantes fongiques chez le diabétique. Ann Endocrinol. 2017;78(4):420-1.
20. Nadol JB. Histopathology of pseudomonas osteomyelitis of the temporal bones starting as malignant external otitis. Am J Otolaryngol. 198;1: 359-71.
21. Glikson E, Sagiv D, Wolf M, Shapira Y. Necrotizing otitis externa: diagnosis, treatment, and outcome in a case series. Diagn Microbiol Infect Dis. 2017;87(1): 74-8.
22. Levenson JM, Parisier SC, Dolitsky J, Bindra G. Ciprofloxacin: drug of choice in the treatment of malignant external otitis (MEO). Laryngoscope. 1991; 101:821-4.
23. Berenholz L, Katzenell U, Harell M. Evolving resistant pseudomonas to ciprofloxacin in malignant otitis externa. Laryngoscope. 2002;112:1619-22.
24. Stevens SM, Lambert PR, Baker AB, Meyer TA. Malignant otitis externa: A novel stratification protocol for predicting treatment outcomes. Otol Neurotol. 2015;36(9):1492-8.

Cite this article as: Diouf MS, Barry M, Ndiaye M, Tall A, Ndiaye C, Ndiaye M, et al. Malignant external otitis: about 50 cases at Fann hospital center. Int J Otorhinolaryngol Head Neck Surg 2024;10:8-11.