

Original Research Article

Effect of myringotomy as an office procedure on the clinical course of acute otitis media: a retrospective study

Chakramakal Joseph Andrews*, Raveendran Krishnan Rahul

Department of ENT, Amala Institute of Medical Sciences, Thrissur, Kerala, India

Received: 06 April 2017

Accepted: 19 May 2017

*Correspondence:

Dr. Chakramakal Joseph Andrews,
E-mail: andchakra@gmail.com

Copyright: © the author(s), publisher and licensee Medip Academy. This is an open-access article distributed under the terms of the Creative Commons Attribution Non-Commercial License, which permits unrestricted non-commercial use, distribution, and reproduction in any medium, provided the original work is properly cited.

ABSTRACT

Background: A retrospective study was conducted to find out the effect of office myringotomy on clinical course of acute otitis media (AOM).

Methods: Patients with signs and symptoms of AOM who underwent office myringotomy were included in the study. The clinical course such as pain, blocked sensation, relief of blocked feeling, hearing improvement, fever, discharge and residual perforation (5 and 14 days) were evaluated after the office myringotomy and compared.

Results: Total 20 patients (10 females and 10 males of age between 5 to 30) were included in study. Among the total patients 12 were below <18 years age and remaining were above 18 years. The overall morbidity of these patients such as pain, blocked sensation and discharge was reduced after the office myringotomy. Furthermore, the residual perforation was absent during the end of 2nd week of post myringotomy. No discharge was found after the myringotomy.

Conclusions: Simple myringotomy with five day course of antibiotic provides more symptomatic relief. The overall morbidity was less after the procedure. This indicates the requirement of myringotomy as an outpatient procedure in suitable patients.

Keywords: Myringotomy, Acute otitis media, Otitis media with effusion

INTRODUCTION

Otitis media is among the most common issues faced by clinicians doing ENT procedure. Approximately 80% of children will have at least one episode of acute otitis media (AOM), and between 80% and 90% will have at least one episode of otitis media with effusion (OME) before their school age.^{1,2} AOM may be defined clinic-pathologically as an inflammation of the middle ear cleft of rapid onset and infective origin, associated with a middle ear effusion and a varied collection of clinical symptoms and signs. It is synonymous with acute suppurative otitis media. It normally develops behind the intact tympanic membrane, but may include acute infections arising in the presence of ventilation tubes or

existing tympanic membrane perforations.^{3,4} This article was aimed to evaluate the clinical features after the office myringotomy.

METHODS

Selection patients

A retrospective study was designed in patients (age 6-30 years) who were presented with acute otitis media with bulged tympanic membrane and agreed for myringotomy under local anesthesia in the department of ENT, Amala institute of medical sciences, Amala Nagar, Thrissur, Kerala, India during the period of 6 months were included. A detailed clinical examination and history had

been taken. Patients below 6 years and above 40 years were excluded from the study. Patients with chronic adenotonsillitis, hypertension and diabetic mellitus were also excluded. Consent was obtained from patient or their relatives and study design was approved by Institutional Ethics Committee for Research and followed the guidelines of Helsinki Declaration.

Myringotomy was done after phenol cauterization of the tympanic membrane. The procedure was carried out using an operating microscope, and with full aseptic procedures. The patient is placed supine on the operating table with the head turned to one side. Using an aural speculum and angled myringotome, a radial incision is made in the posteroinferior segment; the maximum bulging is posterior in acute suppurative otitis media, and the inferior incision avoids the risk of damaging the ossicular chain, chorda tympani and facial nerve. Pus/fluid then gushes out under pressure, and a swab is taken and sent for culture and sensitivities. Residual pus is gently sucked out. The incision should be about 3-4 mm in length; tiny incisions tend to heal too quickly and allow us to reaccumulate in the middle ear cleft. In all cases, fluid which passively exuded from the incision site was processed using standard microbiological methods. The clinical manifestations such as fever, blocked feeling, pain and discharge were taken after the surgery.

RESULTS

Total 20 patients were included in the study. There were 10 males and 10 females. The clinical manifestations presented were fever, blocked feeling, ear ache, and discharge. Among the total, 12 patients were presented with severe ear ache (7 females and 5 males); 11 patients had severe ear blocked feeling and 4 patients had fever (Figure 1 and 3). Office myringotomy was done, 5 days antibiotics were given to all patients and 9 patients had excellent relief of pain and blocked feeling immediately. After office myringotomy, 11 patients had excellent hearing improvement, 7 moderate and 2 mild improvement, 2 patients had discharge, 4 patients had residual perforation after 5 days and none after 14 days (Figure 2 and 4). The overall morbidity was better after the myringotomy (Table 1).

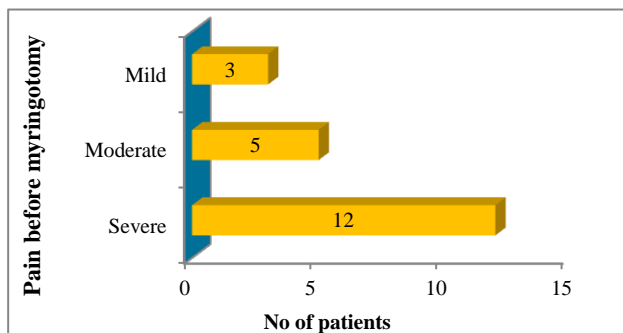


Figure 1: Distribution of pain in patients before office myringotomy.

Table 1: Frequency of clinical presentations of patients underwent office myringotomy.

Clinical presentations (n = 20)	Grading	Frequency of presentations
	Yes	9
Fever	No	11
Discharge	Yes	2
	No	18
Residual perforation (After 5 days)	Yes	4
	No	16
Residual perforation (After 2 weeks)	Yes	0
	No	20
Morbidity	Severe	1
	Moderate	9
	Mild	10

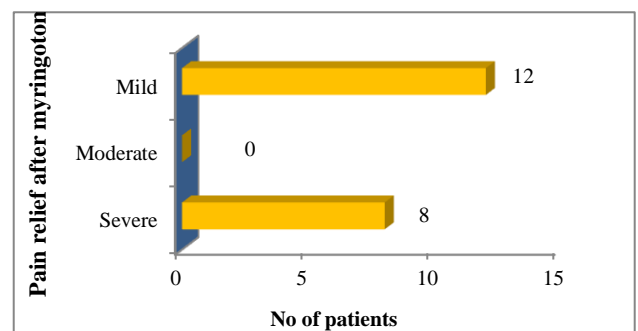


Figure 2: Distribution of pain in patients after office myringotomy.

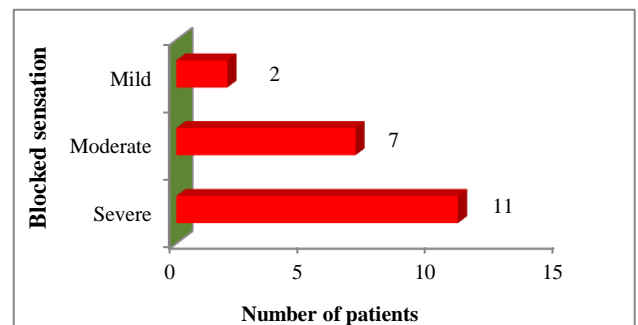


Figure 3: Distribution of blocked sensation in patients before office myringotomy.

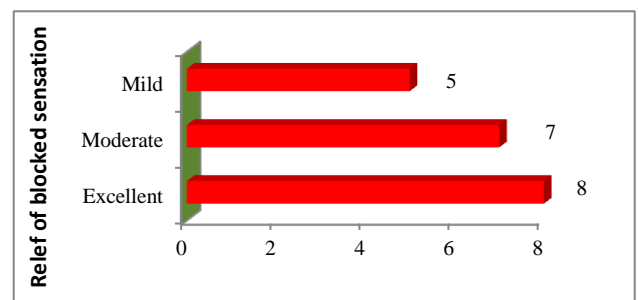


Figure 4: Distribution of relief of blocked sensation in patients after office myringotomy.

DISCUSSION

The result of the study revealed that the frequency of patients with pain, blocked sensation and was reduced after the office myringotomy with improved hearing. Furthermore, the residual perforation was absent during the end of 2nd week of post myringotomy.

The pathophysiology of AOM is complex and multifactorial. The literature supports four broadly defined subgroups of AOM are 1) Sporadic episodes occurring as infrequent isolated events, typically occurring with upper respiratory tract infections; resistant AOM: 2) Persistence of symptoms and signs of middle ear infection beyond three to five days of antibiotic treatment; 3) Persistent AOM: persistence or recurrence of symptoms and signs of AOM within six days of finishing a course of antibiotics and 4) Recurrent AOM: either three or more episodes of AOM occurring within a six-month period, or at least four or six episodes within a 12 month. Some of the epidemiological evidence is also relatively 'soft', since it is based on the flawed premise that AOM can accurately be diagnosed from the history and otoscopy alone, unsupported by tympanometry or tympanocentesis.

AOM is characterized by inflammation of the middle ear with an infiltration of leukocytes, macrophages and mast cells. The resulting effusion contains a large amount of inflammatory mediators, among which are cytokines. Bacteria can be isolated from the middle ear fluid cultures in 50% to 90% of cases of AOM and OME. *Streptococcus pneumoniae*, *Haemophilus influenzae* (non typable), and *Moraxella catarrhalis* are the most common organisms.^{5,6} Among these, *H. influenzae* has become the most prevalent organism in children with severe or refractory AOM following the introduction of the pneumococcal conjugate vaccine.⁷⁻⁹ We found in this study that 5 days of antibiotic treatment can effectively prevent the progress of infection.

Myringotomy by incision of the pars tensa of the tympanic membrane is indicated for acute suppurative otitis media with exudate under pressure in the tympanic cavity (When otalgia and fever are mild, a 24-hour trial of antibiotic therapy is warranted, and in many cases, the infection clears without myringotomy).^{10,11} Most of the cases will present with blocked feeling, residual fluid in middle ear which gets occasionally reactivated. In severe infections (i.e., those with a bulging drum, severe otalgia, high fever, and mastoid tenderness), as well as in persistent or reactivated recurrent infections that fail to resolve with antibiotic therapy, a myringotomy should be done. Myringotomy was undertaken with a view to releasing the pus accumulating pressure and to equalize the middle ear pressure with the atmospheric pressure.

CONCLUSION

Acute otitis media was treated with office myringotomy with course of antibiotic. This provides more

symptomatic relief than antibiotic alone and the practice can be followed routinely since the outpatient procedure will decrease the suffering, hospital stay and patient can get back into his routine activities at an early stage.

ACKNOWLEDGMENTS

The authors gratefully acknowledge the valuable help of Dr. Ajith TA, Professor of Biochemistry, Department of Biochemistry, Amala Institute of Medical Sciences during the preparation of the manuscript.

Funding: No funding sources

Conflict of interest: None declared

Ethical approval: The study was approved by the Institutional Ethics Committee

REFERENCES

1. Tos M. Epidemiology and natural history of secretory otitis. *Am J Otol.* 1984;5(6):459-62.
2. Midgley EJ, Dewey C, Pryce K, Maw AR. The frequency of otitis media with effusion in British pre-school children: a guide for treatment. ALSPAC Study Team. *Clin Otolaryngol Allied Sci.* 2000;25(6):485-91.
3. Itoh M. Practice guideline for pediatric secretory otitis. *Nihon Jibiinkoka Gakkai Kaiho.* 2015;118(9):1166-7.
4. Appleman CIM, van Balen FAM, van de Lisdonk EH, vanWeert HCLM, Eizinga WH. NHG Practice Guideline 'Acute otitis media'. *Huisartsen Wetenschap.* 1999;42:362-6.
5. Jacobs MR, Dagan R, Appelbaum PC, Burch DJ. Prevalence of antimicrobial-resistant pathogens in middle ear fluid. *Antimicrob Agents Chemother.* 1998;42:589-95.
6. Arrieta A, Singh J. Management of recurrent and persistent acute otitis media: new options with familiar antibiotics. *Pediatr Infect Dis J.* 2004;23:S115-24.
7. Block SL, Hedrick J, Harrison CJ, Tyler R, Smith A, Findlay R, Keegan E. Community-wide vaccination with the heptavalent pneumococcal conjugate significantly alters the microbiology of acute otitis media. *Pediatr Infect Dis J.* 2004;23(9):829-33.
8. McEllistrem MC, Adams JM, Patel K, Mendelsohn AB, Kaplan SL, Bradley JS, et al. Acute otitis media due to penicillin-nonsusceptible *Streptococcus pneumoniae* before and after the introduction of the pneumococcal conjugate vaccine. *Clin Infect Dis.* 2005;40:1738-44.
9. Coker TR, Chan LS, Newberry SJ, Limbos MA, Suttrop MJ, Shekelle PG, et al. Diagnosis, microbial epidemiology, and antibiotic treatment of acute otitis media in children: a systematic review. *JAMA.* 2010;304:2161-9.
10. Schwartz R, Rodriguez W, Khan W, Ross S. The increasing incidence of ampicillin resistant

Hemophilus Influenza: a cause of otitis media. *JAMA.* 1978;239:320-3.

11. Barzilaia A, Dekel B, Dagan R, Leibovitz E. Middle ear effusion IL-6 concentration in bacterial and non-bacterial acute otitis media. *Acta Paediatr.* 2000;89(9):1068-71.

Cite this article as: Andrews CJ, Rahul RK. Effect of myringotomy as an office procedure on the clinical course of acute otitis media: a retrospective study. *Int J Otorhinolaryngol Head Neck Surg* 2017;3:646-9.