

Case Report

Intracochlear schwannoma: about a case

Victor Mercado Martínez¹, Francisco Torres Moyano², Carlos Pino Urrutia¹,
Constanza Fuentealba Bassaletti³, Vijaya Prakash Krishnan Muthaiah⁴,
Ignacio Novoa Cornejo^{4*}

¹Instituto de Neurorehabilitación y Balance, Av. Libertad 798 oficina 901, Viña del Mar, Chile

²Hospital Carlos Van Buren, Facultad de Medicina, Universidad de Valparaíso, Valparaíso, Chile

³Department of Otorhinolaryngology and Head and Neck Surgery, Leiden University Medical Center, Leiden, Netherlands

⁴Department of Rehabilitation Sciences, School of Public Health and Health Professions, State University of New York at Buffalo, Buffalo, NY, United States

Received: 15 June 2023

Accepted: 15 July 2023

*Correspondence:

Ignacio Novoa Cornejo,

E-mail: ignacio.novoa.c@gmail.com

Copyright: © the author(s), publisher and licensee Medip Academy. This is an open-access article distributed under the terms of the Creative Commons Attribution Non-Commercial License, which permits unrestricted non-commercial use, distribution, and reproduction in any medium, provided the original work is properly cited.

ABSTRACT

Vestibular schwannoma is a benign tumor that originates from Schwann cells. It is most often found in the internal auditory meatus or cerebellopontine angle. Less frequently, intralabyrinthine localization (IL) can be found. These benign lesions usually present with progressive sensorineural hearing loss, tinnitus, and vertigo. Magnetic resonance imaging (MRI) allows a precise diagnosis of these tumors, also defining their exact location within the labyrinth. Currently, the treatment of IL may require radiosurgery, tumor removal surgery, and tumor follow-up with MRI. We will present a clinical case of a patient with intracochlear schwannoma (ICS) of the left ear.

Keyword: ICS, Intralabyrinthine schwannoma, Primary ear schwannoma, Hearing loss, Benign tumor

INTRODUCTION

Vestibular schwannoma is a benign tumor that originates from Schwann cells within internal auditory canal (IAC). However, these Schwann cells can also be found beyond IAC, giving rise to "intralabyrinthine schwannoma" (IL)/also called "primary inner ear schwannoma."

IL is infrequent benign lesion of small size and slow extradural growth arising from perineural Schwann cells surrounding vestibular and cochlear nerves. It is defined as tumor originating mainly within membranous labyrinth of cochlea, vestibule and semicircular canals.¹ Before introducing MRI techniques, IL unexpected surgical/autopsy findings.² Systematic use of MRI in studying patients with hearing loss and balance disorders has allowed more significant diagnosis of this type of tumor.² Within different published series, IL presents clinically with progressive and sudden sensorineural

hearing loss, mixed asymmetric hearing loss, vertigo, imbalance, and symptoms similar to Ménière's disease (MD).^{3,4} Kennedy et al classified IL as intra-vestibular, intracochlear, intra-vestibulocochlear, transmodiolar, trans-macular, transotic, and tympanolabyrinthine.⁵ This classification makes it possible to establish excellent clinical relationship with diagnostic MRI and tumor follow-up, thus allowing choice of appropriate therapeutic strategy according to location and behavior of IL.¹ Literature confirms that IL is infrequent and underdiagnosed, which is why thorough MRI and neurotologist study in presence of patient with unilateral sensorineural hearing loss and vestibular symptoms.

CASE REPORT

For first time, a 35-year-old female consults in July 2022 at Instituto de neurorehabilitación y Balance (INB), Viña del Mar, Chile. She reports having presented dizziness,

unsteadiness at rest, and hearing loss in left ear 5 years ago. She consulted with specialist physicians, ENT, and neurologists, who indicated tonal audiometry, confirming progressive sensory neural hearing loss with predominant involvement of medium and high frequencies. In addition, MRI of brain is reported without alterations. Clinical exam of ENT performed in INB shows no alterations. Therefore, evaluation with neurootologist and MRI of ears requested. Audiometry confirmed profound hearing loss in all frequencies studied and 0% speech discrimination in left ear (Figure 1). videoculography does not present alterations in tests performed (spontaneous nystagmus study with and without ocular fixation, optokinetic nystagmus, smooth pursuit and saccades and positional tests). Horizontal canal measured with video head impulse test (v-HIT) expected in its qualitative and quantitative parameters, with 1% asymmetry in its gain. MRI showed lesion in middle of left cochlea compatible with an IL, specifically ICS (Figure 2). Brain MRI performed 5 years ago is reviewed, showing lesion compatible with ICS (Figure 3).

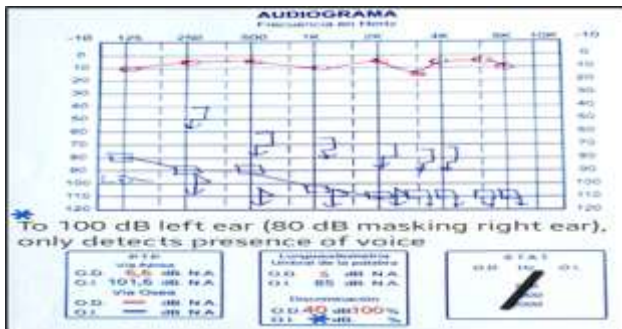


Figure 1: Audiometry, to 100 dB left ear (80 dB masking right ear), only detects the presence of voice.

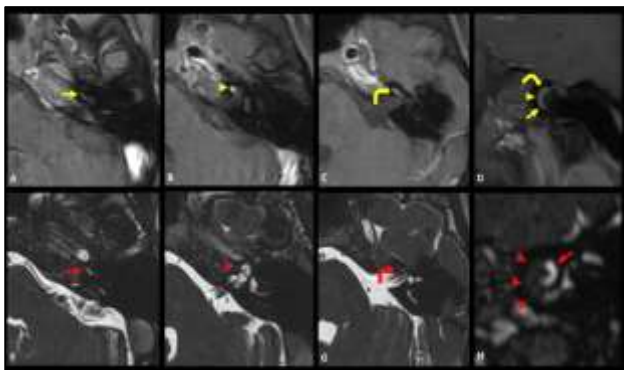


Figure 2 (A-H): ICS in left cochlea after 5-year MR follow-up. Axial fat-saturated gadolinium-enhanced T1-weighted images and balanced fast field-echo images coronal fat-saturated gadolinium-enhanced T1-weighted image and parasagittal balanced fast field-echo reconstruction through left cochlea. Enhancing schwannoma anteriorly in basal turn (yellow arrows), second turn (yellow arrowheads), and upper part of (curved yellow arrows). Normal signal intensity.

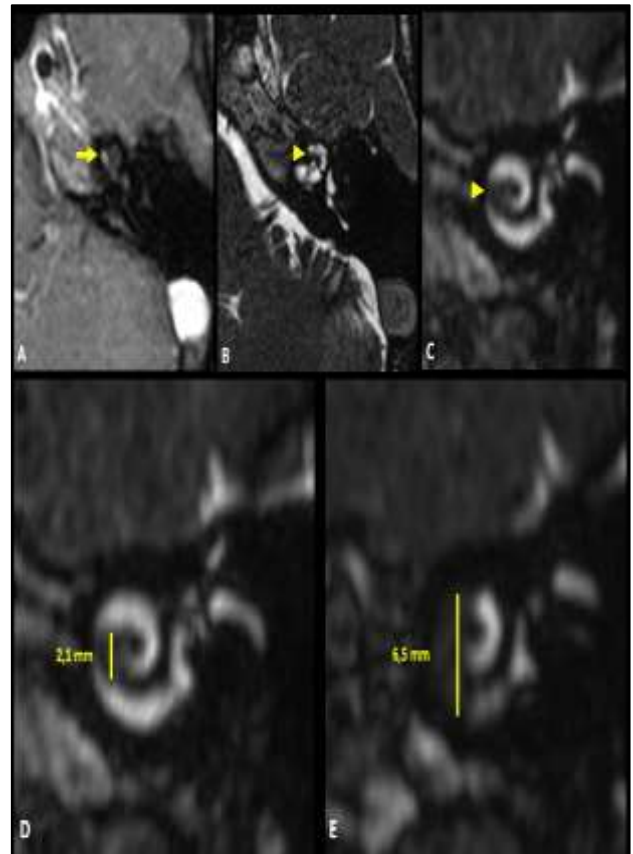


Figure 3 (A-E): Intracochlear schwannoma in second turn of left cochlea. Axial fat-saturated gadolinium-enhanced T1-weighted image and balanced fast field-echo image through the scala tympani and parasagittal balanced fast field-echo reconstruction. Enhancing schwannoma in scala tympani (yellow arrow). Normal hyperintense fluid signal intensity inside scala vestibuli and obliteration of scala tympani in anterior part of second turn (yellow arrowhead). Inside scala vestibuli in basal turn (red arrow). Invasion of scala tympani and scala vestibuli in anterior part of second turn (red arrowhead). Obliteration of scala tympani in upper part of second turn and mainly of scala vestibuli (curved red arrow), without extension to vestibule. Schwannoma in basal turn and anterior part of second turn (red arrowheads). Fluid signal intensity is still present in posterior part of scala tympani (red arrow). Intracochlear schwannoma with a 5-year MR follow-up. Parasagittal balanced fast field-echo reconstruction images through left cochlea. Initial image with small 2.1 mm schwannoma in scala tympani anterior part of second turn. After 5 years, further growth (6.5 mm) to basal turn, scala vestibuli, and anterior part of second turn.

DISCUSSION

The infrequency of these tumors is known; with improved imaging techniques and a high index of suspicion, we believe that the incidence of these

Schwannomas has been previously underestimated.^{1,3,5,6} In the published series, it is transversal that progressive hearing loss is the most frequent clinical sign, followed by tinnitus, sudden hearing loss, vertigo, and ear fullness.⁷ Mixed asymmetric hearing loss and symptoms similar to MS have also been described as forms of presentation of IL.⁴ Studies show that this putative "inner ear conductive loss" is caused by the tumor's loss of sound conduction through blockage of inner ear fluid movement.⁴

Vestibular physiological studies such as v-HIT, caloric stimulation test, and vestibular evoked myogenic potentials (VEMP) and examinations of structures such as images directed to the ears allow differential diagnosis of IL with other forms of presentation.⁷

As mentioned above, the diagnosis of IL is essentially based on MRI.^{1,5} Recent advances in MRI allow ILS to be detected and located with a precision of less than 2 mm.⁷ On T1-weighted images, they appear as well-defined lesions with an intermediate signal. On high-resolution T2-weighted images, a blurring of normal fluid on T1, with contrast as intense and homogeneous uptake.^{1,7} A differential diagnosis should be made with labyrinthine hemorrhage, infectious labyrinthitis, and labyrinthine ossification.¹ The report presented corresponds to an ICS; published studies say it is the most frequent IL.^{1,3} Neff et al suggested that the basal turn of the cochlea is the most frequent location of IL.⁶ When comparing both MR images, it can be seen that the ICS grew more than 4 mm in 5 years (Figure 3, D-E). All expressed before ratifying what is stated in the literature is that the diagnosis of ICS is always a challenge and must be supported by a strong clinical suspicion added to an MRI of the ears.³

Currently, the treatment options for IL are microsurgery, radiation therapy, and observational MRI. In the case of the patient presented, the indication for treatment was based on tumor growth, measured by MRI. Due to hearing impairment induced by IL, most patients opt not only for tumor treatment but also for cochlear implant hearing rehabilitation, which has shown good functional results with different techniques and surgical times.⁷ Surgical resection was proposed to our patient, and at the time of writing this article, this option was not yet decided.

CONCLUSION

The strong clinical suspicion added to the MRI will allow an early diagnosis of ICS, this could be very useful for clinicians and researchers. The patient will be operated on to extract the schwannoma.

Funding: No funding sources

Conflict of interest: None declared

Ethical approval: Not required

REFERENCES

1. Salzman KL, Childs AM, Davidson HC, Kennedy RJ, Shelton C, Harnsberger HR. Intralabyrinthine schwannomas: imaging diagnosis and classification. *Am J Neuroradiol.* 2012;33(1):104-9.
2. Montague ML, Kishore A, Hadley DM, O'Reilly BF. MR findings in intralabyrinthine schwannomas. *Clin Radiol.* 2002;57(5):355-8.
3. Reda JD, West N, Cayé-Thomasen P. Intracochlear Vestibular Schwannoma Presenting with Mixed Hearing Loss. *J Int Adv Otol.* 2021;17(3):265-8.
4. Kennedy RJ, Shelton C, Salzman KL, Davidson HC, Harnsberger HR. Intralabyrinthine schwannomas: diagnosis, management, and a new classification system. *Otol Neurotol.* 2000;25(2):160-67.
5. Neff BA, Willcox TO Jr, Sataloff RT. Intralabyrinthine schwannomas. *Otol Neurotol.* 2003;24(2):299-307.
6. Gosselin É, Maniakas A, Saliba I. Meta-analysis on the clinical outcomes in patients with intralabyrinthine schwannomas: conservative management vs. microsurgery. *Eur Arch Oto-rhino-laryngol.* 2016;273(6):1357-67.
7. Häussler SM, Szczepek AJ, Gräbel S, Olze H. Challenges of Cochlear Implantation in Intralabyrinthine Schwannoma Patients: Surgical Procedures and Auditory Outcome. *J Clin Med.* 2021;10(17):3899.

Cite this article as: Martinez VM, Moyano FT, Urrutia CP, Bassaletti CF, Muthaiah VPK, Cornejo IN. Intracochlear schwannoma: about a case. *Int J Otorhinolaryngol Head Neck Surg* 2023;9:665-7.