

Original Research Article

Retrospective audit of sinonasal inverted papilloma at a tertiary care centre

Somu L.*, Prasanna Kumar S., Urvashi Singh

Department of Otorhinolaryngology, Head and Neck Surgery, Sri Ramachandra Medical College and Research Institute, Chennai, Tamil Nadu, India

Received: 08 April 2017

Accepted: 24 April 2017

*Correspondence:

Dr. Somu L.,

E-mail: somu_11496@yahoo.com

Copyright: © the author(s), publisher and licensee Medip Academy. This is an open-access article distributed under the terms of the Creative Commons Attribution Non-Commercial License, which permits unrestricted non-commercial use, distribution, and reproduction in any medium, provided the original work is properly cited.

ABSTRACT

Background: Inverted Papilloma of the sinonasal tract is a benign neoplasm with unique locally destructive capacity, tendency to recur and a propensity for malignant change. Despite varied studies, there seems to be a lack in consensus with regards to its etiology, predictors of recurrence and malignant transformation. The aim of our study is to analyse the clinical profile, management and outcome of histopathologically proven Inverted Papilloma of the nose and paranasal sinus at our institute.

Methods: Retrospective chart review of 17 patients of histologically proven Sinonasal Inverted Papilloma over a period of 2 years from May 2013 to May 2015.

Results: The majority were in their 5th and 6th decade of life (47%) with a male to female ratio of 15:2. All had been managed surgically with 10 patients undergoing endoscopic assisted polypectomy, 6 requiring partial maxillectomy & 1 requiring total maxillectomy for complete surgical clearance. All patients had been followed up for a minimum duration of 1 year and recurrence was found in 41%. 2 patients had been diagnosed with malignant transformation during follow-up, out of which 1 underwent right partial maxillectomy along with concurrent chemotherapy and other patient underwent left total maxillectomy with concurrent chemotherapy and intensity modulated radiation therapy.

Conclusions: Inverted Papilloma of the sinonasal tract is a locally aggressive disease requiring careful endoscopic and radiological assessment. Adequate surgical management can ensure complete clearance of disease. A strict long term follow-up protocol will facilitate identifying recurrence and malignant transformation.

Keywords: Inverted papilloma, Maxillectomy, Endoscopic sinus surgery, Management

INTRODUCTION

Inverted papilloma (IP) is a unique neoplasm of the mucosal surface of sinonasal tract. Its locally destructive capacity to surrounding structures, tendency to recur and propensity for malignant change gives it the unique rightful classification as an intermediate neoplasm.^{1,2} Sinonasal IP comprises 0.5-4% of all primary nasal tumours with squamous cell malignant transformation being the most common progression.³⁻⁵ Throughout literature there seems to be varied description of its

aggressive nature, tendency to recur and risk of malignant transformation; however there still remains to be a lack of consensus with regards to multiple factors like etiology, predictors of recurrence or malignant transformation.⁶⁻⁸ Since IPs present with clinically indistinguishable features when compared with sinonasal polyposis, a high index of suspicion in high risk individuals prompts a differential diagnosis of IP. Histopathological confirmation remains to be the only tool for definitive diagnosis. The rising trend of endoscopic surgeries has led to surgeons venturing towards a relatively

conservative endoscopic approach for surgical resection. This study aims at reviewing retrospectively histologically proven cases of Sinonasal Inverted Papilloma and analyse the varied clinical presentation, radiological correlation, and outline a suitable management protocol.

METHODS

A retrospective audit of 17 histologically proven cases of sinonasal inverted papilloma in the Department of Otorhinolaryngology, Head and Neck in Sri Ramachandra University, during a period of 2 years from May 2013 to May 2015 with a minimum one year follow-up.

The clinical profile, radiological assessment, and surgical approach for adequate clearance of disease were assessed. The correlation between initial clinical suspicions with histological confirmation was also noted.

RESULTS

During the two year period between May 2013 to May 2015, 691 patients had been surgically managed for sinonasal disease. Following histopathological confirmation, 17 (2.4%) out of the 691 had been diagnosed with IP.

The ‘at-risk’ age group in the study was between the 5th and 6th decade, with 47% (8 patients) incidence and mean age of 49 years (Figure 1). There was a significant male predominance with 15 out of 17 patients (Table 1).

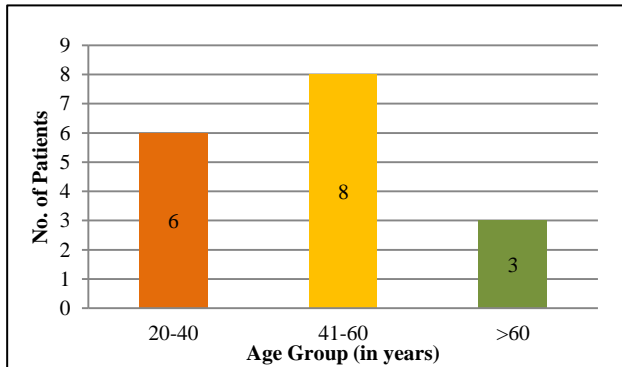


Figure 1: Age distribution.

Table 1: Gender distribution.

Gender	No. of patients	Percentage (%)
Male	15	88
Female	2	12

An assessment of their clinical presentation on admission was done (Table 2). All patients had presented with a gradually progressive nasal block; 14 patients (82%) presented with nasal discharge; 7 patients (41%) with

recurrent nasal bleed and 6 patients (35%) with decreased smell perception.

Table 2: Clinical profile.

Symptoms at presentation	No. of patients	Percentage (%)
Nasal block	17	100
Nasal discharge	14	82
Nasal bleed	7	41
Decreased smell perception	6	35
Hemifacial swelling	2	12

Anterior rhinoscopy for all revealed multiple pale pedunculated mass arising from the lateral wall of the nose into the middle meatus, which were insensitive to touch and did not bleed on probing; 2 patients had proptosis of the eye; 2 had hemi-facial swelling obliterating the nasolabial fold with extensive Sinonasal mass (Figure 2).

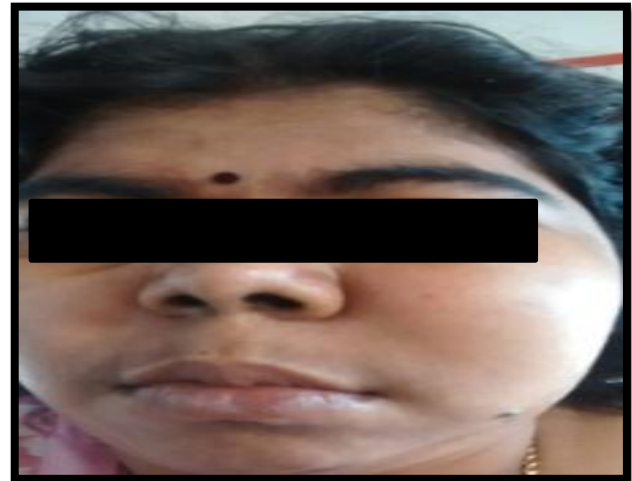

Figure 2: Clinical presentation of 46 year old female with 4 cm x 3 cm diffuse firm swelling of the left cheek extending from the dorsum of the nose to left zygomatic arch.

The disease was found to be unilateral in 16 patients (94%) and bilateral in one patient (6%) as given in Table 3.

Table 3: No. of patients with unilateral/bilateral involvement.

	No. of patients	Percentage (%)
Unilateral	16	94
Bilateral	1	6

The initial diagnosis was - sinonasal polyposis in 5 patients, neoplastic sinonasal mass in 10 and suspected malignant sinonasal mass in 2 patients.

Plain computed tomography of paranasal sinus (CT-PNS) of all patients had been done to determine the extent of the disease and involvement of surrounding structures. Radiological assessment revealed involvement of maxillary sinus in all; ethmoidal sinus involvement in 41% and frontal sinus involvement in 18% (Table 4). Widening of the maxillary ostium with expansion of surrounding bone was also noted in 41% of patients.

Table 4: Involvement of paranasal sinuses based on plain CT-PNS.

Extent of involvement	No. of patients	Percentage (%)
Maxilla only	9	53
Maxilla + Ethmoid	4	24
Maxilla + Ethmoid + Frontal	3	18
All	1	5

One patient presented with sinonasal mass extending to the periorbita and erosion of the lamina papyracea. Another patient presented with lesion in the left maxillary region with extensive erosion of floor of the orbit extending into extraconal part of orbit; anteriorly eroding the left zygoma with periosteal reaction; eroding the inferolateral wall of the maxillary sinus with extension into the buccal space and involving the zygomaticus major muscle; posteriorly and inferiorly extending to involve the left masticator muscle (Figure 3).

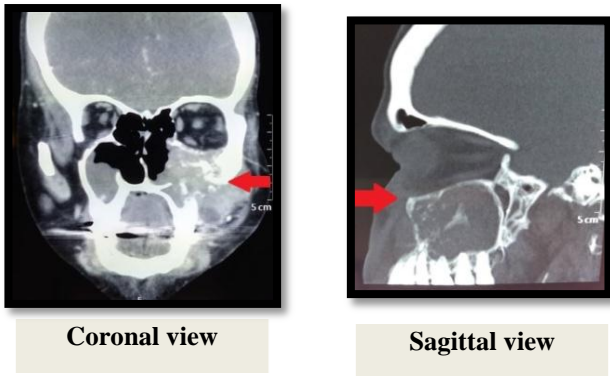


Figure 3: Coronal and sagittal view of contrast enhanced CT-PNS showing large 6.4x4.1 cm hypodense heterogeneously intensely enhancing soft tissue lesion involving the left maxillary region. The red arrow in coronal view shows infero-laterally extension into buccal space. The red arrow in sagittal view shows erosion of the anterior maxillary wall with extension into the premaxillary space.

All high risk individuals had been managed surgically with histopathological assessment of tissue specimen (Figure 4) confirming the diagnosis.

10 patients had undergone endoscopic assisted sinus surgery with polypectomy, out of which 2 later

underwent endoscopic assisted medial maxillectomy and 1 underwent right partial maxillectomy in view of malignant transformation. 4 patients had undergone endoscopic assisted medial maxillectomy as part of initial surgical management; 1 patient with periorbital extension and erosion of lamina papyracea underwent endoscopic assisted medial maxillectomy with removal of tumour from orbital extension by orbital decompression; 2 patients underwent total maxillectomy in view of squamous cell carcinoma in background of inverted papilloma (Table 5).

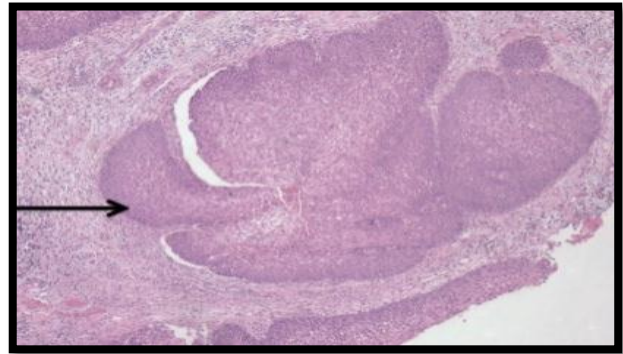


Figure 4: H and E histological image of inverted papilloma.

Table 5: Surgical Profile of patients.

Surgical procedure	No. of patients	Percentage (%)
Endoscopic sinus surgery only (no further intervention required)	7	41
Endoscopic assisted medial maxillectomy	6	35
Endoscopic assisted medial maxillectomy with orbital decompression	1	6
Partial maxillectomy	1	6
Total maxillectomy	2	12

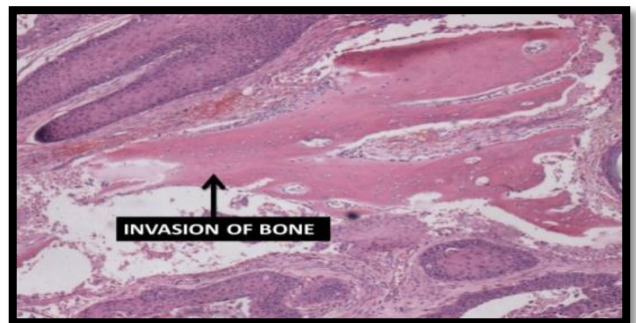

Figure 5: H and E histopathological image showing malignant transformation of inverted papilloma into moderately differentiated squamous cell carcinoma with invasion of underlying bone.

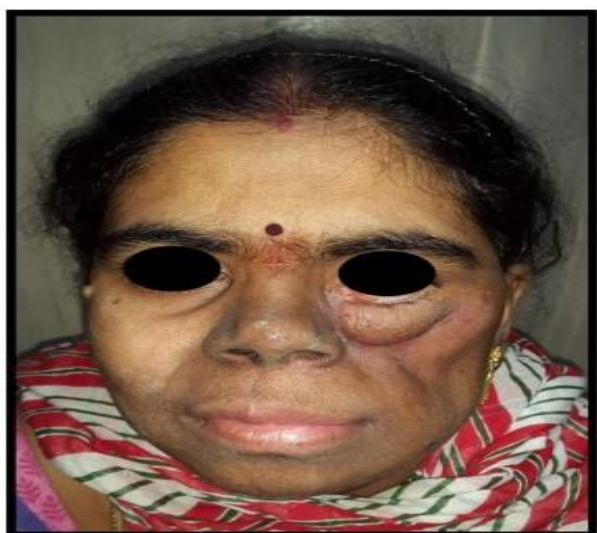

Figure 6: Postoperative 6 months follow-up.

At the end of one year postoperative follow-up, out of the 7 patients who had undergone only endoscopic sinus surgery, 3 had recurrence, of these HPE of 1 patient showed malignant transformation to moderately differentiated squamous cell carcinoma (pT4a cN0 cM0) requiring total left maxillectomy via Weber Fergusson approach along with concurrent chemotherapy with intensity modulated radiotherapy with no recurrence (Figure 5 and 6). The remaining 2 patients underwent revision surgery with endoscopic assisted medial maxillectomy.

DISCUSSION

Sinonasal inverted papilloma is a rare tumour of the nose and paranasal sinuses comprising only 0.5% – 4% of all head and neck tumours.⁵ It has a higher incidence in males than females (3:1) and commonly occurs between the 5th-7th decade.⁹ We found a similar result with majority belonging between the ages of 40 years to 60 years with high predominance amongst male individuals (88%).

The etiology remains unconfirmed, with multiple theories involving secondary to allergies, chronic sinusitis, exposure to airborne pollutants and possible viral etiology.¹⁰ Association between malignant inverted papilloma and HPV type 6 and 11 remains to be confirmed. All patients had an underlying chronic inflammatory disease of the sinonasal tract and 15% with co-existing allergic predisposition.

Inverted papilloma has a tendency to occur unilaterally and involve the maxillary and ethmoid sinuses. In our study 94% of patients had a unilateral disease. 53% of the patients had isolated maxillary sinus involvement and 24% with both maxillary and ethmoid sinus. On radiological examination with plain CT-PNS we noted majority of the patients had bony erosion with widening

of the maxillary ostium (41%); 1 patient had extensive disease causing erosion of the lamina papyracea and extension into the orbit. Sukenik and Casiano (2000) in their study compared CT imaging versus endoscopic examination in diagnosing Inverted Papilloma and recurrence following surgical management. They found CT imaging to be useful in screening and endoscopy more reliable in identifying recurrences.¹¹

Woodson and Neilsen did a clinicopathological assessment of specimens of inverted papilloma and proposed degree of mitotic activity as one predictor of recurrence.^{12,13} However Christensen and Smith in their analysis of 67 specimens found no histopathological factor significant of recurrence.¹⁴

The risk of malignant transformation is variable according to literature, with an average of 10% and incidence of squamous cell carcinoma being 5%.¹⁵ Individuals may present with synchronous malignancy coexisting with inverted papilloma or as similar to ours, with metachronous malignancy i.e. malignancy recurring later at the site of resection of this benign tumour.¹⁶ Some studies believe that due to overestimation of such transformations, the true invasiveness is only prevalent in less than 2% of those with inverted papilloma.¹⁷ Failure to achieve an accurate histological diagnosis and failed follow-ups may explain such disagreement. During follow-up, 2 patients (11%) had recurrence with no dysplasia and 1 patient had recurrence with malignant transformation.

The definite treatment of a malignant inverted papilloma is to provide a complete surgical clearance, followed by postoperative radiotherapy with/without chemotherapy.^{15,16,18} The main considerations to be made by the surgeon are factors that may limit the patient's quality of life as a result of a constrained nasal function and orbital or intracranial extension. We had encountered 4 patients (23%) who were diagnosed with malignant transformation to squamous cell carcinoma either on presentation or during follow-up period requiring more radical surgical clearance. Mendenhall et al noted the likelihood of cure is 50% in malignant inverted papilloma and better benefits with postoperative radiotherapy.¹⁹ All 4 patients have undergone concurrent chemo radiotherapy with no recurrence on follow-up.

Due to the overlapping clinical presentation of sinonasal inverted papilloma and sinonasal polyposis, the possibility of inverted papilloma should be kept in mind especially amongst high risk groups' i.e. male patients between 4th – 6th decades. Radiological assessment with CT-PNS proves to be a useful tool in screening, determining extent of disease and identification of bony involvement while considering surgical approach for adequate clearance. Histopathology remains to be the only reliable confirmatory diagnostic tool. Due to the local aggressiveness and malignant potential of this benign tumour, timely diagnosis and an adequate

clearance at initial surgical intervention is required to limit subsequent recurrence. In our study we found all patients with history of a chronic inflammatory process of the sinonasal tract and 15% with associated allergic predisposition. A preoperative biopsy of all patients diagnosed with sinonasal polyposis done as part of outpatient assessment can be useful in reducing missed cases. Adjuvant radiotherapy can be employed following a complete surgical clearance of malignant inverted papillomas to decrease recurrence and improve survival of the patient. A lifelong follow-up is mandatory.

Funding: No funding sources

Conflict of interest: None declared

Ethical approval: Not required

REFERENCES

1. Ridder GJ, Behringer S, Kayser G, Pfeiffer J. Malignancies arising in sinonasal inverted papillomas. *Laryngorhinootologie.* 2008;87(11):783-90.
2. Mirza S, Bradley PJ, Acharya A, Stacey M, Jones NS. Sinonasal inverted papillomas: recurrence, and synchronous and metachronous malignancy. *J Laryngol Otol.* 2007;121(09):857-64.
3. Woodruff WW, Vrabec DP. Inverted papilloma of the nasal vault and paranasal sinuses: spectrum of CT findings. *AJR. Am J Roentgenol.* 1994;162(2):419-23.
4. Batsakis JG, Suarez P. Schneiderian papillomas and carcinomas: a review. *Adv Anat Pathol.* 2001;8(2):53-64.
5. Nudell J, Chiosea S, Thompson LD. Carcinoma ex-Schneiderian papilloma (malignant transformation): a clinicopathologic and immunophenotypic study of 20 cases combined with a comprehensive review of the literature. *Head Neck Pathol.* 2014;8(3):269-86.
6. Stoddard DG, Keeney MG, Garcia JJ, O'Brien EK. Transcriptional Activity of HPV in Inverted Papilloma Demonstrated by In Situ Hybridization of HPV mRNA. *Otolaryngol Head Neck Surg.* 2015;152(4):752-8.
7. Kramer R, Som ML. True papilloma of the nasal cavity. *Arch Otolaryngol.* 1935;22(1):22-43.
8. Ringertz N. Pathology of malignant tumors arising in the nasal and paranasal cavities and sinuses. *Acta Otolaryngologica (Stockholm).* 1938;27.
9. Bielamowicz S, Calcaterra TC, Watson D. Inverting papilloma of the head and neck: the UCLA update. *Otolaryngol Head Neck Surg.* 1993;109(1):71-6.
10. Mirza S, Bradley PJ, Acharya A, Stacey M, Jones NS. Sinonasal inverted papillomas: recurrence, and synchronous and metachronous malignancy. *J Laryngol Otol.* 2007;121(09):857-64.
11. Sukenik MA, Casiano R. Endoscopic medial maxillectomy for inverted papillomas of the paranasal sinuses: value of the intraoperative endoscopic examination. *Laryngoscope.* 2000;110(1):39-42.
12. Woodson GE, Robbins KT, Michaels L. Inverted papilloma: considerations in treatment. *Archives Otolaryngol.* 1985;111(12):806-11.
13. Nielsen PL, Buchwald C, Nielsen LH, Tos M. Inverted papilloma of the nasal cavity: Pathological aspects in a follow-up study. *Laryngoscope.* 1991;101(10):1094-101.
14. Christensen WN, Smith RR. Schneiderian papillomas: a clinicopathologic study of 67 cases. *Human Pathol.* 1986;17(4):393-400.
15. Batsakis JG, Suarez P. Schneiderian papillomas and carcinomas: a review. *Adv Anat Pathol.* 2001;8(2):53-64.
16. von Buchwald C, Bradley PJ. Risks of malignancy in inverted papilloma of the nose and paranasal sinuses. Current opinion in otolaryngology and head and neck surgery. 2007;15(2):95-8.
17. Karkos PD, Fyrmpas G, Carrie SC, Swift AC. Endoscopic versus open surgical interventions for inverted nasal papilloma: a systematic review. *Clin Otolaryngol.* 2006;31(6):499-503.
18. Strojjan P, Jereb S, Borsos I, But-Hadzic J, Zidar N. Radiotherapy for inverted papilloma: a case report and review of the literature. *Radiology and oncology.* 2013;47(1):71-6.
19. Mendenhall WM, Hinerman RW, Malyapa RS, Werning JW, Amdur RJ, Villaret DB, et al. Inverted papilloma of the nasal cavity and paranasal sinuses. *Am J Clin Oncol.* 2007;30(5):560-3.

Cite this article as: Somu L, Kumar PS, Singh U. Retrospective audit of sinonasal inverted papilloma at a tertiary care centre. *Int J Otorhinolaryngol Head Neck Surg* 2017;3:517-21.