

## Case Report

# Extra-oral approach to iatrogenic temporomandibular joint dislocation-case report

Manish Munjal\*, Shubham Munjal, Salony Sharma, Hardeep Kaur, Deeksha Chawla, Loveleen Sandhu, Dhruv Gupta, Mehneet Sawhney, Anjana Pillai

Department of ENT and HNS, Dayanand Medical College, Ludhiana, Punjab, India

**Received:** 14 July 2022

**Accepted:** 10 August 2022

**\*Correspondence:**

Dr. Manish Munjal,

E-mail: manishmunjaldr@yahoo.com

**Copyright:** © the author(s), publisher and licensee Medip Academy. This is an open-access article distributed under the terms of the Creative Commons Attribution Non-Commercial License, which permits unrestricted non-commercial use, distribution, and reproduction in any medium, provided the original work is properly cited.

### ABSTRACT

We discuss an intriguing patient whose temporo-mandibular joint got dislocated following, a per oral sialodochotomy. The reduction was undertaken using an external approach rather than the conventional internal without sedation. The approach is quick, painless, easy to perform, reproducible and least expensive. This technique is based on the following principles i.e., in the anteriorly dislocated mandible, the coronoid process and anterior border of the ramus can be palpated easily over the cheek on the affected side and thus steady pressure application on the cheek over the coronoid process and anterior aspect of the mandibular ramus, easily reduce the dislocation. In the undislocated mandible, the coronoid process and anterior border of the ramus are not palpable as they are located posterior to the body of the zygoma

**Keywords:** Temporomandibular joint. Dislocation, Reduction, Intraoral, Extra oral approach

### INTRODUCTION

The human temporomandibular joint (TMJ) i.e., the jaw joint, is the masticator synovial joint facilitating a set of complex movements. This specialized joint lies between the mandible and the temporal bone of the skull; precisely between condylar head of the mandible superiorly and the mandibular fossa of the temporal bone inferiorly. The triad, of the TM Joint, dentition and the ligamento-muscular soft tissue, play a vital role in breathing, eating and speech.<sup>1</sup>

Due to its capability of rotational movement in the sagittal plane and a translational movement on its own axis this joint is classified as a ginglymoarthrodial joint. The translation movement generates more movement.<sup>2</sup> The movements are restricted by passive factors, as well as passive tension of the ligaments and muscles.<sup>4</sup>

A variety of movements occur at the TMJ. These movements are mandibular depression, elevation, lateral deviation (which occurs to both the right and left sides), retrusion and protrusion. Each of these movements are performed by a number of muscles working together to perform the movement while controlling the position of the condyle within the mandibular fossa.

Chewing and talking require a combination of jaw movements in a number of directions.<sup>6</sup>

The resting position of the TMJ is with the mouth slightly open, the lips together and the teeth not in contact. This is in contrast to the closed-pack position in which the teeth are tightly clenched.<sup>7</sup>

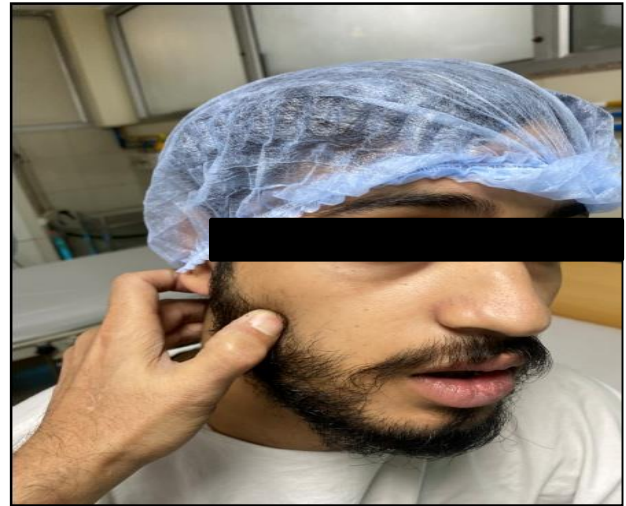An anterior dislocation of the TM joint in a young male with reduction using the extra-oral technique is being discussed.

## CASE REPORT

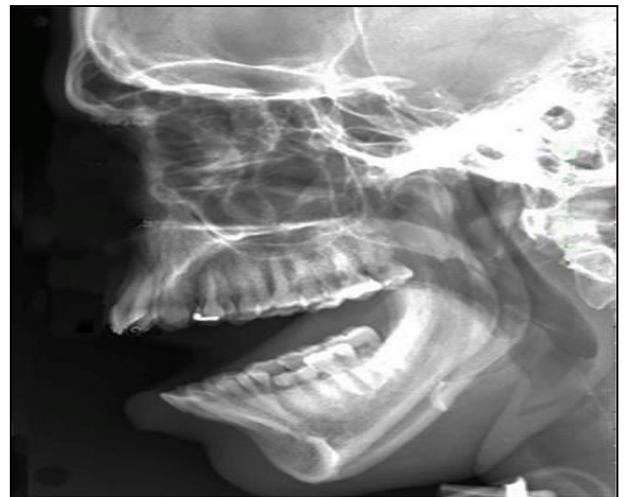A robust 25-year male underwent a per-oral sialodochotomy for Wharton's duct sialolithiasis. The stone was at the junction of the duct with the gland; thus, the procedure was undertaken under general anaesthesia utilizing naso-tracheal intubation. Moreover, wide access was obtained with a Molt mouth retractor, juxtaposed on the maxillary and mandibular second pre-molars. The retractor blades were placed on the left side i.e., side of the surgical intervention. The procedure was uneventful with adequate homeostasis and a wide marsuplication of the duct. He was extubated and shifted to the recovery, with oral intake initiated in the evening. At that time, the resident on call noticed that he was keeping his mouth open with inability in closing when asked to do so, (Figure 1) Moreover there was pain on attempted mouth closure. On digital palpation a hollow area in front of the right ear canal was felt while the condyle was in its normal position on the left side. The coronoid process was protruding on the right side (Figure 2).

A clinical diagnosis of unilateral, i.e., right sided TMJ dislocation was made and he was planned for reduction under sedation. A lateral radiograph of the TM joint confirmed the diagnosis (Figure 3).

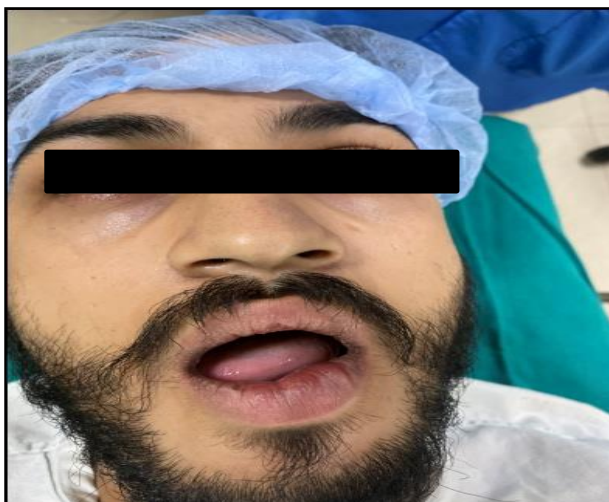Under xylocaine 10% spray, the pre auricular area and the cheek was palpated and the ascending ramus of the right side was encircled between the left thumb, placed on the coronoid process and the other fingers on the posterior border, A similar placement was carried on the other side. A clockwise torque was applied, with more force on the left coronoid process. Thereby the left condyle slid over the articular eminence into the glenoid fossa with a 'click', thereby completing the reduction. The joint on the other side was at its normal articulation. The mouth could be easily closed with proper occlusion of the incisors; with the prominence of the coronoid process becoming imperceptible (Figure 4 and 5).



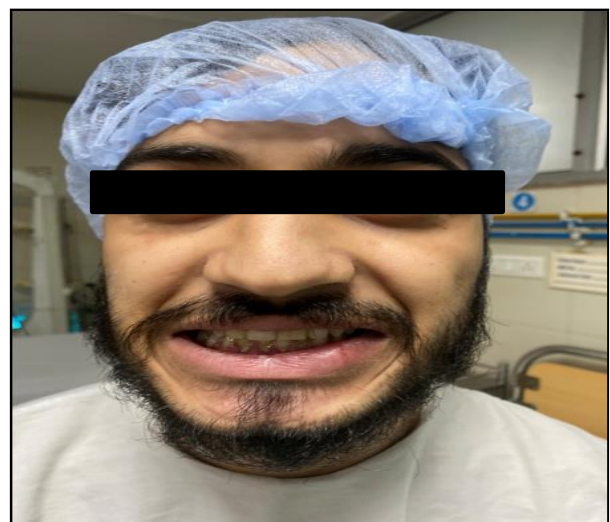**Figure 2: Coronoid process protruding on right side.**



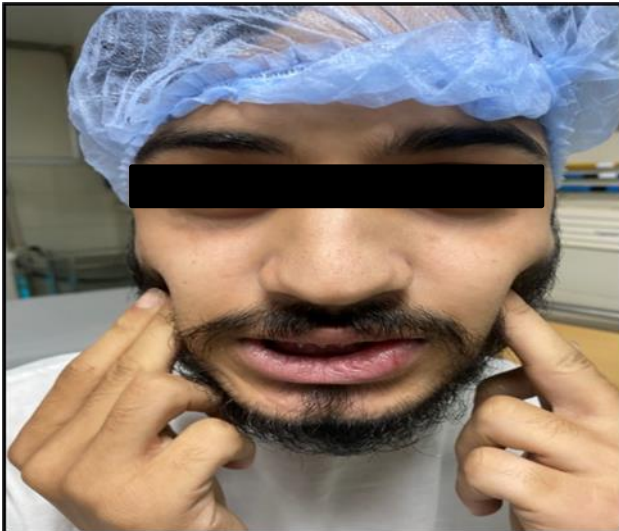**Figure 3: Lateral radiograph of TMJ confirmed diagnosis.**



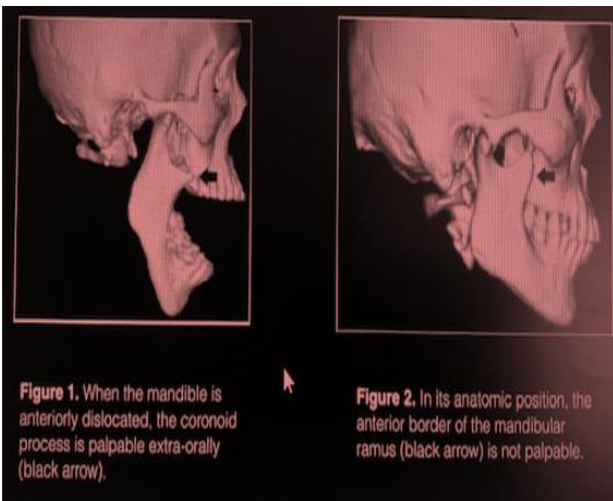
**Figure 1: Patient keeping his mouth open and difficulty in closing when asked to do so.**



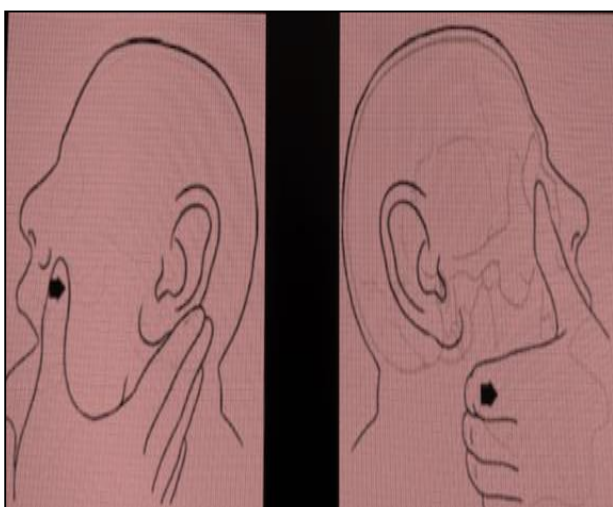
**Figure 4: Post reduction the mouth could be easily closed with proper occlusion of the incisors.**



**Figure 5: The prominence of the coronoid process was imperceptible.**



**Figure 6: Anterior dislocated and normal positioned mandible.**



**Figure 7: The Chen et al technique of TMJ reduction.**

## DISCUSSION

Neuromuscular control, determines the biomechanics of the TMJ. This includes the muscles of mastication, and the ligaments in its proximity, as well as the neural transmission carried by the V3 or the mandibular division of the trigeminal nerve.

The pathophysiology of dislocation of this masticator joint is the anterior movement of the condylar process over the articular eminence to lie in front of it, and inability to descend back to its normal glenoidal position. This stretches the ligaments and muscles, provoking intense local orofacial pain.

The TMJ dislocation might be partial (subluxation) or complete (luxation), bilateral or unilateral, acute, and chronic, protracted or chronic recurrent.<sup>8-10</sup>

Anterior dislocation being the predominant. The medial, lateral, superior, into the middle cranial fossa, and the posterior into the ear canal are rare and are mostly secondary to trauma.<sup>11, 12</sup>

Anatomical alterations and in-coordinated neuromuscular mechanics are the likely etiologies that may lead to dislocation of the TMJ.

Un coordinated neuromuscular mechanics are consequent to spasm of the lateral pterygoid muscles, lax articular disc as well as the capsular ligament, and not in frequently long-standing intra-articular derangements.

Anatomical alterations recorded are, arthritic changes in the condyle, i.e., a flattened or narrowed condyle, reduced height of the articular eminence, morphological changes of the glenoid fossa, zygomatic arch, and the squamotympanic fissure.<sup>13,14</sup>

Age and changes in the dentition do contribute to dislocation of this joint.<sup>13,15</sup>

Interventions, diagnostic or therapeutic like Mackintosh laryngoscopy, oro-endotracheal intubation, trans oral fiber optic bronchoscopy, tracheoscopy, oesophagoscopy and dental treatments like third molar extractions or root canal treatments, all may lead to this unexpected complication<sup>16-20</sup>

Forceful wide opening of the mouth while yawning, laughing, vomiting, or seizures are other routine causes.

Certain antipsychotic medications may also lead to dislocation. Ehlers-Danlos syndrome, orofacial dystonia, and the Marfan syndrome have this entity sometimes associated with it.<sup>15,21</sup>

Meticulous history and clinical examination are vital tools in diagnosing TMJ dislocation. Other confirmatory diagnostic aids include plain and panoramic radiographs,

demonstrating the location of the condylar head anterior to the articular eminence. 3D computed tomography is ideal in terms of its perfection to show this entity.

On the basis of the clinico-radiological evaluation, Akinbami classified TMJ dislocation into the following three types: Type I-the head of the condyle is directly below the tip of the eminence, type II-the head of the condyle is in front of the tip of the eminence and type III-the head of the condyle is high-up in front of the base of the eminence.<sup>23</sup>

This clinical entity though painful is easy to manage. Conservative therapeutic modalities include symptomatic pain relief with analgesics and the manual reduction maneuvers.

The Hippocrates maneuver of manual reduction is performed by first pressing the mandible downward, then backward, and finally upward.

The 1981, Lewis modification, is making the patient sit down and the clinician should stand in front of him/her or at 11 o' clock position. Then, the thumb should be pressed down on the occlusal surface of the lower molar teeth. At the same time, the chin should be elevated with the fingers and the entire mandible should be pushed posterior.<sup>23</sup>

Howe GL modified the technique by changing the position of the thumb from the occlusal surface of the teeth to the anterior border of the ramus.<sup>24</sup>

Chen et al advocated a simple, effective, and novel technique to reduce the anteriorly displaced mandible.<sup>25</sup> They did not use sedation as used earlier for any of their cases.

Sometimes, the manual reduction is complicated by the secondary reflex spasm of the lateral pterygoid muscle, followed by painful stimuli from the joint capsule.

As the condition is very painful, it is always better to perform manual reduction under local anesthesia by giving auriculotemporal nerve block or local infiltration in the joint space. Role of the muscle relaxants in controlling the reflex muscle spasm is still debatable.

In 1987, Awang described another simple, safe, and rapid method in managing acute dislocation. According to him, induction of the gag reflex by probing the soft palate creates a reflex neuromuscular action that resulted in the reduction.<sup>3,26</sup>

We adopted the Howe GL and the Chen et al technique in our patient to reduce the dislocation.

Anterior dislocation of the mandible is a clinical scenario that is not infrequently encountered and requires prompt intervention. The classic technique for reduction of the

mandible requires the surgeon to place his/her thumbs or fingers into the patient's mouth along the lower molars and apply force inferiorly and posteriorly. However, this technique is fraught with difficulties and inefficiencies including the following: It requires a surprising amount of force, the patient usually has to be sedated, possibly under procedural sedation, which usurps valuable resources, the physician has to incur the risk of personal injury and possible disease transmission by placing their hands into one of the most bacteria-ridden surfaces on this earth: the human mouth and the dynamics of this technique rests upon the under mentioned principles: 1. In the anteriorly dislocated mandible, the coronoid process and anterior border of the ramus can be palpated easily over the cheek on the affected side (Figure 6). 2. Steady pressure application on the cheek over the coronoid process and anterior aspect of the mandibular ramus, easily reduce the dislocation. 3. In the undislocated mandible, the coronoid process and anterior border of the ramus are not palpable as they are located posterior to the body of the zygoma

## CONCLUSION

The management of TMJ dislocation is customized as per the underlying cause. Manual reduction is sufficient in case of acute dislocation. We utilized a unique technique on a patient with anterior TMJ dislocations, without sedation, with an excellent outcome. The force required compared to the classical technique was much less.

*Funding: No funding sources*

*Conflict of interest: None declared*

*Ethical approval: Not required*

## REFERENCES

1. Di Fabio RP. Physical therapy for patients with TMD: a descriptive study of treatment, disability, and health status. *J Orofacial pain.* 1998;12(2).
2. Maini K, Dua A. Temporomandibular joint syndrome. In: *StatPearls*, Stat Pearls Publishing. 2021.
3. Jinbao W, Xiaoming X, Jingen S. Analysis of the open-closing movement of the human temporomandibular joint. *Cells Tissues Organs.* 1988;133(3):213-6.
4. Abdi AH, Sagl B, Srungarapu VP, Stavness I, Prisman E, Abolmaesumi P et al. Characterizing Motor Control of Mastication With Soft Actor-Critic. *Frontiers Human Neurosci.* 2020;14:188.
5. Saladin KS. *Human anatomy.* Rex Bookstore, Inc. 2005.
6. Horan F. *Gray's Anatomy: the anatomical basis of clinical practice:* Edited by Susan Standring. Illinois: Churchill Livingstone Elsevier, 2008;1551.
7. Magee DJ. *Orthopedic physical assessment.* St. Louis, Mo. Saunders Elsevier. 2008.
8. Landes CA, Lipphardt R. Prospective evaluation of a pragmatic treatment rationale: open reduction and internal fixation of displaced and dislocated condyle

- and condylar head fractures and closed reduction of non-displaced, non-dislocated fractures: Part I: condyle and subcondylar fractures. *Int J Oral Maxillofacial Surg.* 2005;34(8):859-70.
9. Caminiti MF, Weinberg S. Chronic mandibular dislocation: the role of non-surgical and surgical treatment. *J Can Dental Asso.* 1998; 64(7):484-91.
  10. Do Egito Vasconcelos BC, Porto GG. Treatment of chronic mandibular dislocations: a comparison between eminectomy and miniplates. *J Oral Maxillofacial Surg.* 2009;67(12):2599-604.
  11. Hoard MA, Tadge JP, Gampper TJ, Edlich RF. Traumatic chronic TMJ dislocation: report of an unusual case and discussion of management. *J Cranio-maxillofacial Trauma.* 1998; 4(4):44-7.
  12. Harstall R, Gratz KW, Zwahlen RA. Mandibular condyle dislocation into the middle cranial fossa: a case report and review of literature. *J Trauma Acute Care Surg.* 2005;59(6):1495-503.
  13. Güven O. Inappropriate treatments in temporomandibular joint chronic recurrent dislocation: A literature review presenting three particular cases. *J Craniofacial Surg.* 2005;16(3):449-52.
  14. Vasconcelos BC, Porto GG, Neto JP, Vasconcelos CF. Treatment of chronic mandibular dislocations by eminectomy: follow-up of 10 cases and literature review. *Medicina Oral Patologia Oral y Cirugia Bucal.* 2009;14(11):e593-6.
  15. Medra AM, Mahrous AM. Glen temporal osteotomy and bone grafting in the management of chronic recurrent dislocation and hypermobility of the temporomandibular joint. *Bri J Oral Maxillofacial Surg.* 2008;46(2):119-22.
  16. Bhandari S, Swain M, Dewoolkar LV. Temporomandibular joint Dislocation after Laryngeal mask airway insertion. *Inte J Anesthesiol.* 2008;16(1):1-4.
  17. Lipp M, Von Domarus H, Daubländer M, Leyser KH, Dick W. Effects of intubation anesthesia on the temporomandibular joint. *Der Anaesthesist.* 1987;36(8):442-5.
  18. Rosemore J, Nikoomanesh P, Lacy IS. Bilateral temporomandibular joint dislocation after PEG tube placement. *Gastrointestinal endoscopy.* 2004;59(1):146-7.
  19. Kepron W. Bilateral dislocations of the temporomandibular joint complicating fiber optic bronchoscopy. *Chest.* 1986;90(3):465.
  20. Baus O, Sadat-Khonsari R, Fenske C, Engelke W, Schwestka-Polly R. Temporomandibular joint dysfunction in Marfan syndrome. *Oral Surg Oral Med Oral Pathol Oral Radiol Endodontol.* 2004; 97(5):592-8.
  21. Thexton A. A case of Ehlers-Danlos syndrome presenting with recurrent dislocation of the temporomandibular joint. *Bri J Oral Surg.* 1964;2:190-3.
  22. Akinbami BO. Evaluation of the mechanism and principles of management of temporomandibular joint dislocation. Systematic review of literature and a proposed new classification of temporomandibular joint dislocation. *Head Face Med.* 2011;7(1):1-9.
  23. Lewis JE. A simple technique for reduction of long-standing dislocation of the mandible. *Bri J Oral Surg.* 1981;19(1):52-6.
  24. Howe GL. *Minor oral surgery*, John Wright. 3<sup>rd</sup> Ed. 1985;393-5.
  25. Chen YC, Chen CT, Lin CH, Chen YR. A safe and effective way for reduction of temporomandibular joint dislocation. *Ann Plastic Surg.* 2007;58(1):105-8.
  26. Awang MN. A new approach to the reduction of acute dislocation of the temporomandibular joint: a report of three cases. *Bri J Oral Maxillofacial Surg.* 1987;25(3):244-9.

**Cite this article as:** Munjal M, Munjal S, Sharma S, Kaur H, Chawla D, Sandhu L et al. Extra-oral approach to iatrogenic temporomandibular joint dislocation-case report. *Int J Otorhinolaryngol Head Neck Surg* 2022;8:765-9.