

Original Research Article

Factors contributing to poor outcome in COVID associated mucormycosis

Kavita Sachdeva, Stephy M. Tom*, Lakshmy V. Raj, Soumya Saini,
Mayur V. Kabade, Amrita Shukla

Department of Otorhinolaryngology and Head and Neck Surgery, Netaji Subhash Chandra Bose Medical College, Jabalpur, Madhya Pradesh, India

Received: 26 February 2022

Accepted: 11 April 2022

***Correspondence:**

Dr. Stephy M. Tom,

E-mail: stephyariatom123@gmail.com

Copyright: © the author(s), publisher and licensee Medip Academy. This is an open-access article distributed under the terms of the Creative Commons Attribution Non-Commercial License, which permits unrestricted non-commercial use, distribution, and reproduction in any medium, provided the original work is properly cited.

ABSTRACT

Background: Mucormycosis is an uncommon but a fatal fungal infection that usually affects patients with altered immunity. Mucormycosis is proven to be a life-threatening condition. This occurred in the delta variant epidemic of coronavirus in India. This prompted us to conduct a systematic review of deaths in mucormycosis to know its temporal associations in relation to comorbidities, association with drugs being used in COVID-19 and overall characteristics of patients with its outcome.

Methods: This retrospective study was conducted over 21 deaths out of 140 mucormycosis patients in the tertiary care centre between time period from May 2021 to July 2021. Based on the detailed history, clinical examination, endoscopic examination, blood investigations and radiological investigations, data was collected and analysed.

Results: In the study 19 patients were post covid and 2 were COVID positive at the time of admission to the hospital. 13 patients were having random blood sugars above 300 and 8 were having below 300 mg/dl. 13 patients had diabetic ketoacidosis. The maximum C-reactive protein (CRP) values was 200 and declined on treatment. The prothrombin time international normalized ratio (PT INR) values range between 0.99 and 1.3. Serum electrolytes were found to be normal in most of the patients. In the present study, 3 patients had electrolyte imbalance not responding to treatment. According to computed tomography/magnetic resonance imaging (CT/MRI) findings, 12 had pansinusitis, 3 had pansinusitis with orbital cellulitis, 5 had pansinusitis with cavernous sinus thrombosis and 1 had pansinusitis with mandibular osteomyelitis.

Conclusions: Early diagnosis, prompt treatment of comorbidities and immediate surgical debridement prevents death in mucormycosis patients.

Keywords: Mucormycosis, Comorbidities, Deaths

INTRODUCTION

Coronavirus disease 2019 (COVID-19) caused by severe acute respiratory syndrome coronavirus 2 (SARS-CoV-2) has been associated with a wide range of opportunistic bacterial and fungal infections.¹ Both *Aspergillus* and *Candida* have been reported as the main fungal pathogens for co-infection in people with COVID-19.² Recently, several cases of mucormycosis in people with COVID-19

have been increasingly reported world-wide, in particular from India. The primary reason that appears to be facilitating mucorales spores to germinate in people with COVID-19 is an ideal environment of low oxygen (hypoxia), high glucose (diabetes, new onset hyperglycemia, steroid-induced hyperglycemia), acidic medium (metabolic acidosis, diabetic ketoacidosis [DKA]), high iron levels (increased ferritins) and decreased phagocytic activity of white blood cells (WBC) due to immunosuppression (SARS-CoV-2 mediated,

steroid-mediated or background comorbidities) coupled with several other shared risk factors including prolonged hospitalization with or without mechanical ventilators. Phycomycosis or zygomycosis was first described in 1885 by Paltauf and later coined as mucormycosis in 1957 by Baker an American pathologist for an aggressive infection caused by *Rhizopus*.^{3,4} Mucormycosis is an uncommon but a fatal fungal infection that usually affects patients with altered immunity. *Mucor* genus *Rhizopus*, *Mucor*, *Rhizomucor*, *Cunninghamella* and *Absidia* of order-mucorales, class-zygomycetes.⁵ The *Rhizopus oryzae* is most common type and responsible for nearly 60% of mucormycosis cases in humans and also accounts for 90% of the rhinoorbital-cerebral (ROCM) form.⁶ Mode of contamination occurs through the inhalation of fungal spores.

The incidence of mucormycosis has risen more rapidly during the second wave compared with the first wave of COVID-19 in India, with at least 14872 cases as of 28 May 2021. The state of Gujarat alone contributed to the highest number of cases, with at least 3726 cases of mucormycosis in patients with active and recovered COVID-19, followed by the state of Maharashtra. Other states such as Rajasthan, Andhra Pradesh, Karnataka, Haryana, Madhya Pradesh, Uttarakhand, and Delhi have also shown a steady rise in the number of mucormycosis cases and deaths related to it; with multiple states already having declared it as an epidemic and a notifiable disease to the national health authorities.⁷ The Indian Council of Medical Research released guidelines for the screening, diagnosis, and management of mucormycosis in patients with COVID-19.⁸ India contributed to approximately 71% of the global cases of mucormycosis in patients with COVID-19.⁹ The intracranial involvement of mucormycosis increases the fatality rate to as high as 90%.¹⁰

Moreover, rapidity of dissemination of mucormycosis is an extraordinary phenomenon and even a delay of 12 hour in the diagnosis could be fatal, the reason 50% of cases of mucormycosis have been historically diagnosed only in the post-mortem autopsy series.¹¹ Mucormycosis is proven to be a life-threatening condition. This occurred in the delta variant epidemic of coronavirus in India.

This prompted us to conduct a systematic review of deaths in mucormycosis to know its temporal associations in relation to comorbidities, association with drugs being used in COVID-19 and overall characteristics of patients with its outcome.

METHODS

Study area and target population

This retrospective study was conducted over 21 deaths out of 140 mucormycosis patients in the tertiary care centre between time period from May 2021 to July 2021.

Study design

The study is a retrospective type of study.

Inclusion criteria

Patients who were diagnosed to have mucormycosis, got admitted in the hospital and death occurred within the hospital stay.

Exclusion criteria

Patients with allergic and nonfungal sinusitis were not included in the study.

Data collection

Based on the detailed history, clinical examination, endoscopic examination, blood investigations and radiological investigations. Data was analysed and was presented in the form of frequency and percentage shown by bar and pie charts.

Ethical approval

Ethical approval was obtained from the ethics committee.

Statistical analysis

The data of 21 patients was collected and entered in Microsoft excel sheet and data were statistically analysed. Findings were noted and presented in the form of pie charts and bar diagrams.

RESULTS

The study was based on the data of 21 deaths out of 140 mucormycosis patients in the tertiary care centre in central India. In the study 19 patients were post COVID and 2 were COVID positive at the time of admission to the hospital (Figure 1).

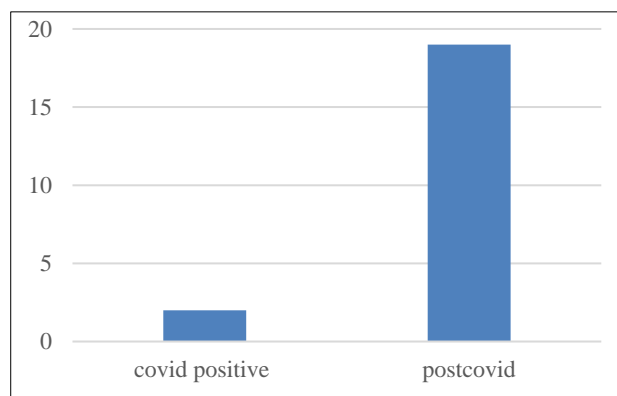


Figure 1: COVID status of patients.

In the study most of the deaths occurred in the age group above 70 years (28.5%), 5 each in the age groups 60-70 years and 50-60 years (23.8%) and 3 in 40-50 years (14.2%) and 2 in 30-40 years (9.5%).

15 out of 21 patients (71.4%) received oxygen supplementation and 17 out of 21 (80.9%) patients received steroid supplementation. Out of 21 patients 20 were males and 1 were female. 13 patients were having random blood sugars above 300 and 8 were having below 300 mg/dl. 13 patients had DKA (Figure 2).

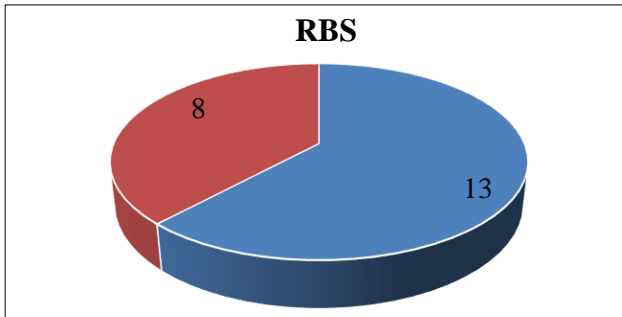


Figure 2: Blood sugar levels in mucormycosis patients.

The CRP values in the patients. It was found that the maximum values was 200 and minimum value was 1.33 (Figure 3).

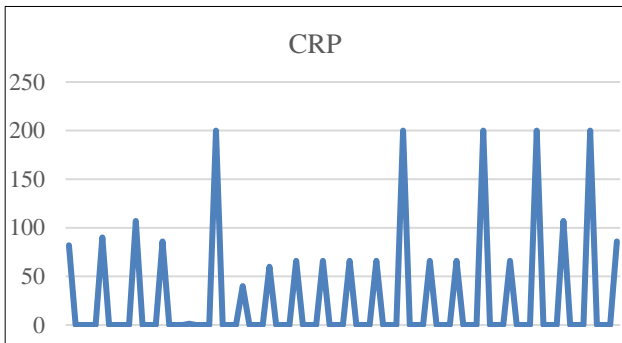


Figure 3: CRP levels in mucormycosis patients.

The PT INR values ranges between 0.99 and 1.3.

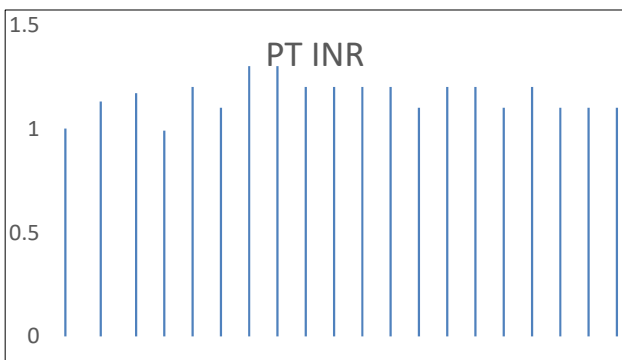


Figure 4: PT INR values in mucormycosis patients.

Serum electrolytes were found to be normal in 18 patients. 3 patients had electrolyte imbalance not responding to treatment. According to CT/MRI findings, 12 had pansinusitis, 3 had pansinusitis with orbital cellulitis, 5 had pansinusitis with cavernous sinus thrombosis and 1 had pansinusitis with mandibular osteomyelitis. The comorbidities were analysed all patients had diabetes mellitus, out of which 5 had both diabetes and hypertension. Out of 21 patients who succumbed to mucormycosis 13 were fit for surgery and were operated .8 were critically ill. Out of 13 operated cases, 10 underwent endoscopic debridement, 2 underwent unilateral maxillectomy and 1 underwent hemimandibulectomy. The cause of death was analysed and was found to have multiple causes. They were sepsis, respiratory failure, sudden cardiac arrest, dyselectrolytemia, systemic mucormycosis, intracranial involvement and cavernous sinus thrombosis.

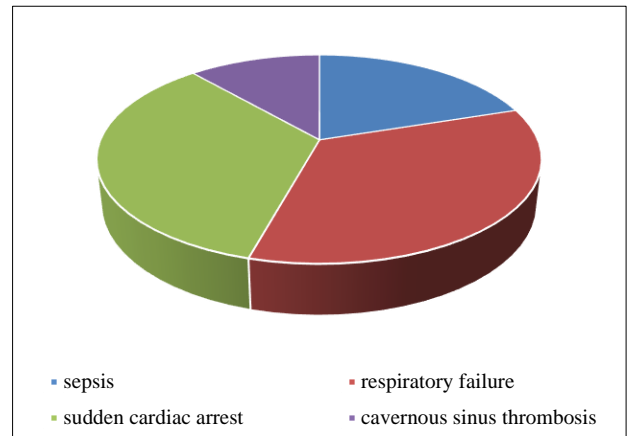


Figure 5: Causes of deaths in mucormycosis patients.

DISCUSSION

Although mucormycosis is an extremely rare in healthy individuals but several immunocompromised conditions predispose it. This includes uncontrolled DM with or without DKA, hematological and other malignancies, organ transplantation, prolonged neutropenia, immunosuppressive and corticosteroid therapy, iron overload or hemochromatosis, deferoxamine or desferrioxamine therapy, voriconazole prophylaxis for transplant recipients, severe burns, intravenous drug abusers, malnutrition and open wound following trauma.¹² Mucormycosis can involve nose, sinuses, orbit, central nervous system (CNS), lung (pulmonary), gastrointestinal tract (GIT), skin, jaw bones, joints, heart, kidney, and mediastinum (invasive type), but ROCM is the commonest variety seen in clinical practice worldwide.¹² It should be noted that term ROCM refers to the entire spectrum ranging from limited sino-nasal disease (sino-nasal tissue invasion), limited rhino-orbital disease (progression to orbits) to rhino-orbital-cerebral disease (CNS involvement).¹³

Giant cell invasion, thrombosis and eosinophilic necrosis of the underlying tissue is the pathological hallmark of mucormycosis. Microbiological identification of the hyphae based on diameter, presence or absence of septa, branching angle (right or acute branching), and pigmentation, differentiates it from other fungal infections.

The 1950 Smith and Krichner criteria for the clinical diagnosis of mucormycosis are still considered to be gold standard and include: black, necrotic turbinate's easily mistaken for dried, crusted blood; blood-tinged nasal discharge and facial pain, both on the same side; soft peri-orbital or peri-nasal swelling with discoloration and induration; ptosis of the eyelid, proptosis of the eyeball and complete ophthalmoplegia and; and multiple cranial nerve palsies unrelated to documented lesions.¹⁴

The study was based on the data of 21 deaths occurred in the mucormycosis patients in the tertiary care centre in central India during the epidemic of delta variant of corona virus in India. In the study 19 patients were post covid and 2 were covid positive. In the study most of the deaths occurred in the age group above 70 years (28.5%), 5 each in the age groups 60-70 years and 50-60 years (23.8%) and 3 in 40-50 years (14.2%) and 2 in 30-40 years (9.5%).

15 out of 21 patients (71.4%) received oxygen supplementation and 17 out of 21 (80.9%) patients received steroid supplementation during their covid treatment. Out of 21 patients 20 were males and 1 was female. Out of 21 patients, 9 were in sepsis and 12 were not in sepsis. 13 patients were having random blood sugars above 300 and 8 were having below 300 mg/dl. The maximum CRP values was 200 and declined on treatment. The PT INR values ranges between 0.99 and 1.3.

Serum electrolytes were found to be normal in most of the patients. In the present study, 3 patients had electrolyte imbalance not responding to treatment.

According to CT/MRI findings, 12 had pansinusitis, 3 had pansinusitis with orbital cellulitis, 5 had pansinusitis with cavernous sinus thrombosis and 1 had pansinusitis with mandibular osteomyelitis. The comorbidities were analysed all patients had diabetes mellitus, 5 had both diabetes and hypertension. A detailed analysis of the causes of preoperative and postoperative deaths was done.

Preoperative deaths

Out of 21 patients who succumbed to mucormycosis 13 were fit for surgery and were operated. 8 were critically ill. These patients in spite of being supplemented with 8-10 litres of oxygen were not able to maintain oxygen saturation above 75-80%. Out of the 8 patients, 2 were on Bipap and these patients were not been able to stepdown into NRM or sustain without oxygen supplementation. Hence surgery could not be done. Out of these 8 critically ill patients, 2 were intubated at the time of admission and

unconscious. They were found to be covid positive and developed signs and symptoms of mucormycosis while they were on oxygen supplementation. Sample collected from nasal cavity of these patients and sent for fungal biopsy and potassium hydroxide (KOH). It was positive for mucormycosis. They were managed with IV amphotericin B. Blood sugars were monitored with HbA1C and RBS monitoring 5 times a day. It was controlled by regular Insulin according to sliding scale, glargine as per opinion of physician. Out of 21 patients, 13 had DKA and were managed as per standard DKA treatment protocol. Renal function tests were done on alternate days. Most of the preoperative deaths were the patients who presented with advanced disease and were unconscious at the time of admission. The lung functions were compromised in these patients. In spite of all the rigorous medical management of complications, these 8 patients succumbed to death. The immediate cause of death in these patients were respiratory failure, sepsis, shock and leading to cardiorespiratory failure as terminal event.

Postoperative deaths

The immediate postop deaths were analysed. These patients who were already on 8-10 litres of oxygen preoperatively, when they were able to sustain without oxygen were taken for surgery, and operated. Depending on the clinical condition, they were operated endoscopically and open surgery was done. They were kept on oxygen for 2-3 days immediate postoperative period. Out of 13 operated cases, 10 underwent endoscopic debridement, 2 underwent unilateral maxillectomy and 1 underwent hemimandibulectomy. Blood sugars and DKA were monitored and managed as per standard treatment protocol. During immediate postoperative period, these patients had fluctuation in oxygen saturation and was kept on 8-10 litres of oxygen. However, patients had gradual decrease in oxygen saturation and was intubated, started on noradrenaline support. These patients developed anuria and serum creatinine were found to be raised upto 2.5 mg/dl. Serum electrolytes found to be deranged. Serum potassium was found to be below 2 mmol/l. Hence amphotericin B was stopped in these patients. One patient developed resistant hypokalemia which was not responding to correction by injection potassium chloride. Nephrology consultation was done for this. Serum magnesium level also found to be low in 1 patient and it was corrected. Two patients had hyponatremia below 125 mmol/l and were corrected. Out of 13 operated patients, one patient had systemic mucormycosis with right parotid involvement along with nasal and orbital involvement. Ultrasonography (USG) abdomen showed liver involvement with multiple chest lesions. This patient was also suspected to have gastrointestinal mucormycosis. The patient general condition was poor at the time of admission. His blood sugars were controlled. Extensive endoscopic debridement of nasal cavity, infratemporal fossa and right frontal lobe. Right parotid abscess was drained. During the postoperative period patient developed

anuria, pulse rate and oxygen saturation started to drop. Patient was kept on noradrenaline support. However, he could not survive more than 3 days postoperatively. Out of 13 postoperative cases, one patient developed hemoptysis postoperatively. He had CO-RAD score of 12 on computed tomography (CT) chest and was suspected to have pulmonary mucormycosis. Sputum was sent for KOH fungal culture and CBNAAT. Sputum was found to be positive for broad nonseptate fungi. He was conscious and was on 6 litres of oxygen and was on IV amphotericin B. This patient was shifted to pulmonary medicine department. This patient had another bout of hemoptysis following which the patient succumbed to death. 2 out of 13 operated patients developed an unusual complaint of loose stools of about 12 episodes per day and abdominal distension which could not be controlled by medication. They developed rapid fall in blood pressure and was suspected to have gastrointestinal mucormycosis which could not be properly investigated as the patient condition deteriorated rapidly. These patients succumbed to death within a day.

Challenges in the management of mucormycosis patients

Critical care management of mucormycosis patients is a big challenge. Most of the mucormycosis patients were presented to the department at the stage of advanced disease with multiple comorbidities like diabetes mellitus, poor lung function, cardiac failure and shock. Hence surgery could not be done. An intensive multidisciplinary approach by otorhinolaryngologist, ophthalmologist, physician, anesthetist, neurosurgeon, radiologist and nephrologist were required so that these patients were operated as soon as possible. Most of the patient received 150-200 mg of amphotericin B per day. The patients were taken for emergency debridement with explained high risk consent of the patient and patient attenders as the disease was rapidly spreading. The time duration between admission of the patient and getting operated ranges from 1-5 days depending on the deranged clinical parameters. 119 patients were successfully treated from the centre. The mucormycosis epidemic was an unexpected event however it was controlled by cooperation of administrative will and all the staff in our centre.

Table 1: Causes of deaths.

Preoperative deaths	Immediate postop deaths	Delayed postop deaths
Case no. 1,2	Case no. 9	Case no. 14
Day 2 after admission: pansinusitis with acute non-hemorrhagic infarct; cavernous sinus; thrombosis; and cardiorespiratory failure	POD 1: resistant hypokalemia; thrombocytopenia; lack of spontaneous respiration postoperatively; and cardiorespiratory failure	POD 6: cavernous sinus thrombosis; cardiorespiratory failure; and respiratory failure
Case no. 3	Case no. 10	Case no. 15
Day 6: intracranial involvement with acute infarct and chronic ischemic changes; and respiratory failure	POD3: parotid involvement; systemic mucormycosis; cavernous sinus thrombosis; sepsis; and respiratory failure	POD7: cerebrovascular accident; loose stools; abdominal distension; and respiratory failure
Case no. 4	Case no. 11	Case no. 16
Day 7: encephalitis and CVA; sepsis; and respiratory failure	POD 4: cardiorespiratory failure	POD 9: cavernous sinus thrombosis; and cardiorespiratory failure
Case no. 5	Case no. 12, 13	Case no. 17
Day 9: sepsis; chronic hyponatremia; and cardiorespiratory failure	POD 5: sepsis; respiratory failure; and cardiorespiratory failure	POD 10: sepsis; abdominal tuberculosis; and cardiorespiratory failure
Case no. 6, 7		Case no. 18
Day 15: sepsis; respiratory failure; COVID positive; and cardiorespiratory failure		POD 13: sepsis; electrolyte imbalance not responding to treatment; and cardiorespiratory failure
Case no. 8		Case no. 19
Day 16: cardiorespiratory failure		POD 15: sepsis; cavernous sinus; thrombosis; cerebrovascular accident
		Case no. 20
		POD 30: loose stools; abdominal distension; and cardiorespiratory failure
		Case no. 21
		POD 64: sepsis; pulmonary tuberculosis; pulmonary mucormycosis; and mandibular osteomyelitis

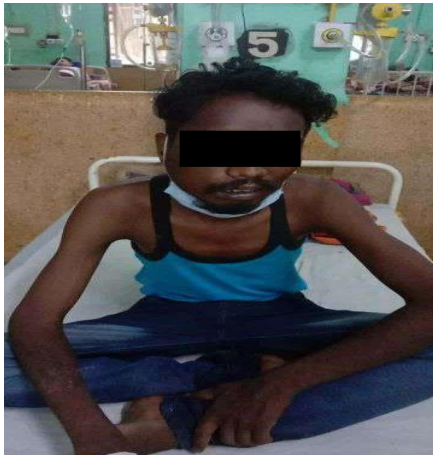

Figure 6: Systemic mucormycosis with right parotid involvement.

CONCLUSION

Mucormycosis is a fatal fungal infection which led to death of many patients among the COVID pandemic. Multiple causes were found to be associated with deaths. They were sepsis, respiratory failure, cardiorespiratory failure, dyselectrolyemia, systemic mucormycosis, and cavernous sinus thrombosis. Hemoptysis, loose stools were alarming signs of systemic mucormycosis which if ignored may lead to death of patient. Early diagnosis, prompt treatment of comorbidities and immediate surgical debridement prevents death in mucormycosis patients. There are many undetermined underlying factors which influence the outcome of treatment modalities in the management of mucormycosis patients.

ACKNOWLEDGEMENTS

Authors would like to express gratitude to Dr. Prof. Kavita Sachdeva, Professor and Head of Department of Otorhinolaryngology and Head and Neck Surgery, N.S.C.B. Medical College and Hospital, Jabalpur under whose guidance and constant encouragement this work has been accomplished. They express their thanks to teachers Dr. Anirudh Shukla, Associate Professor and Dr. Mehmooda Sultana, Assistant Professor, Department of Otorhinolaryngology and Head and Neck Surgery, N.S.C.B. Medical College and Hospital, Jabalpur for their help and guidance throughout their work. They express their gratitude to Dean, N.S.C.B. Medical College and Hospital, Jabalpur for his kind permission to carry out this work.

Funding: No funding sources

Conflict of interest: None declared

Ethical approval: The study was approved by the Institutional Ethics Committee

REFERENCES

1. Kubin CJ, McConville TH, Dietz D, Zucker J, May M, Nelson B, et al. Characterization of Bacterial and Fungal Infections in Hospitalized Patients With Coronavirus Disease 2019 and Factors Associated With Health Care-Associated Infections. *Open Forum Infect Dis*. 2021;8(6):ofab201.
2. Song G, Liang G, Liu W. Fungal Co-infections associated with global COVID-19 pandemic: a clinical and diagnostic perspective from China. *Mycopathologia*. 2020;185(4):599-606.
3. Paltauf A. Mycosis mucorina. *Virchows Arch Pathol Anat Physiol Klin Med*. 1885;102:543-64.
4. Baker RD. Mucormycosis-a new disease? *J Am Med Assoc*. 1957;163:805-8.
5. Eucker J, Sezer O, Graf B, Possinger K. Mucormycoses. *Mycoses*. 2001;44(7):253-60.
6. Sugar AM. In: Mandell GL, Bennett JE, Dolin R, editors. *Mandell, Douglas, and Bennett's principles and practice of infectious diseases*. Fifth ed. New York, USA: Churchill Livingstone. 2000.
7. Singh P. Black fungus: here is a list of states with highest number of mucormycosis cases. *Hindustan Times*. 2021. Available at: <https://www.hindustantimes.com/india-news/blackfungus-states-with-highest-number-ofmucormycosis-cases-101621559394002.html>. Accessed on 28 May 2021.
8. Indian Council of Medical Research. Evidence based advisory in the time of COVID-19 (screening, diagnosis & management of mucormycosis). 2021. Available at: https://www.icmr.gov.in/pdf/covid/techdoc/Mucormycosis_ADVISORY_FROM_ICM_R_In_COVID19_time.pdf. Accessed on 28 May 2021.
9. John TM, Jacob CN, Kontoyiannis DP. When uncontrolled diabetes mellitus and severe COVID-19 converge: the perfect storm for mucormycosis. *J Fungi*. 2021;7:298.
10. Deutsch PG, Whittaker J, Prasad S. Invasive and non-invasive fungal rhinosinusitis: a review and update of the evidence. *Medicina*. 2019;55:1-14.
11. Maartens G, Wood MJ. The clinical presentation and diagnosis of invasive fungal infections. *J Antimicrob Chemother*. 1991;28(13-22):17-44.
12. Sugar AM. Mucormycosis. *Clin Infect Dis*. 1992;14:S126-9.
13. Peterson KL, Wang M, Canalis FR, Abemayor E. Rhinocerebral mucormycosis: evolution of the disease and treatment options. *Laryngoscope*. 1997;107:855-62.
14. Smith HW, Kirchner JA. Cerebral mucor-mycosis: a report of 3 cases. *Arch Otolaryngol*. 1950;68:715-26.

Cite this article as: Sachdeva K, Tom SM, Raj LV, Saini S, Kabade MV, Shukla A. Factors contributing to poor outcome in covid associated mucormycosis. *Int J Otorhinolaryngol Head Neck Surg* 2022;8:453-58.