

Original Research Article

Parapharyngeal space schwannomas: our experience and review of literature

Inderdeep Singh*, Sunil Goyal, Vikas Gupta, Manoj Kumar, Anubhav Singh

Department of ENT, Command Hospital, Armed Forces Medical College, Pune, India

Received: 25 February 2017

Revised: 15 March 2017

Accepted: 18 March 2017

***Correspondence:**

Dr. Inderdeep Singh,

E-mail: dridsingh@hotmail.com

Copyright: © the author(s), publisher and licensee Medip Academy. This is an open-access article distributed under the terms of the Creative Commons Attribution Non-Commercial License, which permits unrestricted non-commercial use, distribution, and reproduction in any medium, provided the original work is properly cited.

ABSTRACT

Background: Tumors of the parapharyngeal space are a rare group of head & neck tumors. Due to their indolent nature they present late with either cranial nerve palsy or lateral neck swelling. The aim of the study was i) to determine the incidence of parapharyngeal space schwannoma among defence personnel's and their dependents presenting to ENT OPD and ii) to study the clinical presentation, management and outcomes of such lesion.

Methods: The study is a retrospective observational study. All new patients referred to ENT OPD at our center were included in the study. Data was collected from our OPD records over two years between Jan 2015 and Dec 2016.

Results: It was found that the incidence rate of parapharyngeal space schwannoma was 0.034% out of all fresh cases reporting to ENT OPD and 0.47% out of all fresh diagnosed cases of head and neck tumours at our centre. Out of the total 5 cases of parapharyngeal space schwannomas, 2 patients had vagal schwannomas and one each had hypoglossal nerve schwannoma, spinal accessory nerve schwannoma and sympathetic chain schwannoma.

Conclusions: Schwannomas of the parapharyngeal region can be very extensive and may require to be removed in a staged procedure involving the head & neck and neurosurgeons. It is important to distinguish these tumors from other head and neck malignancies by detail clinical and radiological examinations. Despite the benign nature of the disease, the surgery can be morbid with cranial nerve palsies in extensive tumors.

Keywords: Parapharyngeal space schwannoma, Management

INTRODUCTION

Tumours of the parapharyngeal space are an interesting group of tumours because of the origin, presentation and management. Most of these tumours are of salivary glands origin (50%, most commonly deep lobe of parotid), followed by tumours of neurogenic origin (20%). The remaining 30% includes lymphoreticular lesions, metastatic lesions and carotid body tumours. Together they account for only about 0.5% of all head and neck tumours.¹ Schwannomas are the most common tumours of neurogenic origin of which vagal schwannoma accounts for 50%.² The clinical presentation of schwannomas depends on the anatomical area involved and nerve of origin.

Accurate diagnosis and management can be very challenging and at times requires a team approach including pathologist and neuro-surgeon. Surgical excision is the standard treatment modality for parapharyngeal schwannomas and recurrence is uncommon.

In this article we present a review of 5 consecutive cases of parapharyngeal space schwannomas which we managed in the last two years.

The aim of the study was i) to determine the incidence of parapharyngeal space schwannoma among defence personnel's and their dependents presenting to otorhinolaryngology out patients department (OPD) and

ii) to study the clinical presentation, management and outcomes of such lesion.

METHODS

Our study is a retrospective study conducted at a tertiary care centre in Western India. All new patients referred to ENT OPD at our center were included in the study. Data was collected from our OPD records. The study was conducted over two years between Jan 2015 to Dec 2016. All old cases and those with an established diagnosis on follow up, patients for periodic medical examination and medical examination of recruits were excluded from the study.

RESULTS

The total number of our OPD work load (old cases and new cases) between Jan 2015 and Dec 2016 was 30,208. Out of which the total number of new cases was 7,367. Out of these only 538 patients had a diagnosis of head and neck lesions. Out of these there were 12 cases of parapharyngeal space tumours which included 6 cases of salivary gland tumours, 5 cases of schwannomas and 1 case of lymphoma. The incidence rate of parapharyngeal space schwannoma was 0.034% out of all fresh cases reporting to otolaryngology OPD and 0.47% out of all fresh diagnosed cases of head and neck lesions at our centre.

Table 1: Clinical presentation of the schwannoma of head and neck.

Sr. No	Age/ Sex	Clinical Features	Imaging	Clinical Diagnosis
1	37 Y/ Male	Insidious onset gradually progressive swelling right side of neck x 2 years. Associated history of cough on touching the swelling. No history of dysphagia, hoarseness, giddiness, palpitation or ptosis of eye. On examination: 6x5 cm size firm swelling on right side of neck extending from thyroid notch to angle of the mandible. The swelling could be moved horizontally but not vertically.	MRI: 5.1cms x 4.2 cms swelling in the right parapharyngeal space displacing the ECA and ICA anteromedially. FNAC was suggestive of schwannoma	Right Vagal schwannoma
2	47 Y/ Male	Insidious onset, gradually progressive swelling over right side of neck x 1 year. No other symptoms. On examination: 3x2 cm size firm swelling over right side of neck in upper third of sternomastoid. Pan endoscopy: NAD	Imaging: 2.6 x 1.8 cm swelling in the right parapharyngeal space lying anterior to the carotid artery and internal jugular vein. FNAC was inconclusive	Carcinoma of unknown primary origin- (right level II lymph node)
3	39 Y/ Female	Insidious onset gradually progressive swelling over right side of neck x 6 months. No other complaints. On examination: 3x2 cm size firm swelling over right side of neck underneath the middle third of Sternomastoid which moved horizontally but not vertically.	MRI: 2.8cms x 1.9 cms swelling in the right parapharyngeal space displacing the common carotid artery anteromedially. FNAC was suggestive of schwannoma	Right Vagal schwannoma
4	42 Y/ Female	Insidious onset and gradually progressive swelling on left side of neck. No history of dysphagia, hoarseness, giddiness, palpitation or ptosis of eye. On examination: 2x2 cm size firm swelling over left side of neck underneath the middle third of Sternomastoid which moved horizontally but not vertically.	MRI: 2.5cms x 2 cms swelling in the left parapharyngeal space displacing the common carotid artery anteromedially. FNAC was suggestive of schwannoma	Left Vagal schwannoma
5	37 Y/ Female	Insidious onset and gradually progressive swelling over right side of upper neck x 3 years. Headache x 3 months & Unsteadiness of gait x 1 month. On examination: 7x4 cm size firm swelling over right side of neck extending from angle of mandible to thyroid notch. It could be moved horizontally but not vertically. Associated with paresis of trigeminal nerve and facial nerve and hypoglossal nerve on right side. Bilateral vocal cords were mobile.	MRI: showed a large mass lesion (solid and cystic component) on right side with intracranial component (2.6cms x2.8cms x2.9cms) compressing brainstem, and extracranial component (3.5cms x3.7cms x 6.1cms) with compression & posterior displacement of internal jugular vein and carotid artery. It is communicating through Hypoglossal canal.(Figure 1)	Right Hypoglossal schwannoma

Out of the total 5 cases of parapharyngeal space schwannomas 2 patients had vagal schwannoma and one each had hypoglossal nerve schwannoma, spinal accessory nerve schwannoma and sympathetic chain schwannoma as depicted in Table 1.

MRI was preoperatively suggestive of origin of schwannoma correctly in 4 out of the 5 cases. The 4th case was diagnosed on imaging to be a vagal nerve schwannoma, however, intraoperatively it was noted that schwannoma was arising from cervical sympathetic chain. 3 out of the 5 cases developed post op complications in the form of nerve palsies of the nerve of origin of the schwannoma. One case of hypoglossal schwannoma which was extensive and presented with both cervical and intracranial component and brain stem compression developed multiple cranial nerve palsy.

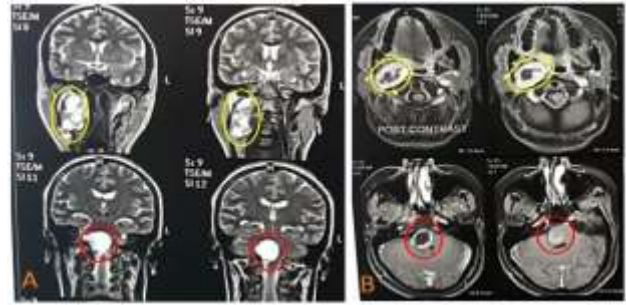


Figure 1: A: T2W images (Coronal sections) showing large hypoglossal schwannoma with solid and cystic component. Intracranial portion marked with red circle can be seen compressing the brainstem. Cervical component is marked with a yellow circle. B: T1W post contrast images (Axial sections) of the same patients.

Table 2: Management, histology, complication and outcomes of schwannoma of head and neck.

Sr No	Management	Final Diagnosis	Complications and Follow up
1	Tumour was excised in toto via a cervical approach under general anaesthesia. Intraoperatively, the tumour was found to be completely engulfing the vagus nerve while the hypoglossal nerve was stretched out over the superior half of the tumour. The nerve was sacrificed during removal of tumour and end to end anastomosis of vagal nerve was attempted.(Figure 2B)	Right Vagal schwannoma	Complete palsy of vagus nerve on right side. Final histopathology (HPE) was consistent with Vagal Schwannoma.
2	Excision biopsy planned under GA via cervical approach. Intraoperative it was seen arising from the spinal accessory nerve above the Erb's point. Excised in toto with preservation of the nerve	Right spinal accessory nerve schwannoma	Uneventful no post op weakness. Final HPE: Spinal accessory nerve schwannoma
3	Tumour was excised in toto via cervical approach under general anesthesia. Tumour was seen arising from cervical sympathetic chain and was stretched out. Nerve was sacrificed during tumour removal	Right Vagal schwannoma	Uneventful with no post op vagus nerve palsy. Final HPE: Vagal Schwannoma.
4	Tumour was excised in toto via cervical approach under general anesthesia. Tumour was seen arising from cervical sympathetic chain which had to be sacrificed.	Left Sympathetic chain schwannoma	Post op patient had Horner's syndrome on left side. Final HPE: Sympathetic chain schwannoma
5	Stage 1: Patient underwent a neurosurgical intervention (far lateral approach) to remove the intracranial component of the tumour under general anaesthesia Stage 2: 3 months later the patient underwent excision of cervical component of the schwannoma via cervical approach under general anesthesia. Lateral tarsorrhaphy (right) was done in view of the facial nerve palsy. (Figure 2A)	Right Hypoglossal schwannoma	Stage 1: Post op patient had CSF collection over the surgical site which was managed conservatively. Patient also developed palsy of right V, VII, IX, X, XI and XII cranial nerve. Tracheostomy was done post operatively in view of prolonged intubation. Stage 2: Post op period uneventful. Patient is now off tracheostomy Under regular follow up in Otolaryngology and Neuro- surgery opd. Final HPE: Hypoglossal schwannoma

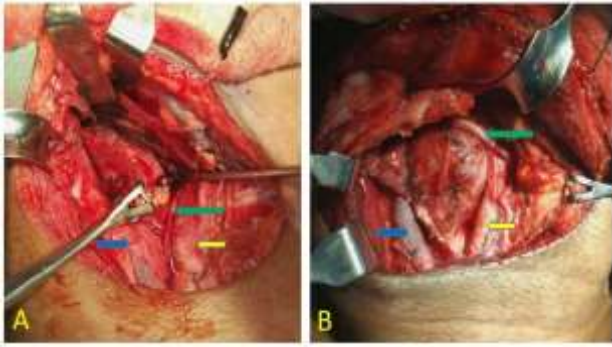


Figure 2: A: intraoperative image showing cervical component of hypoglossal nerve schwannoma. Yellow arrow showing carotid bifurcation; green arrow showing vagus nerve and blue arrow showing internal jugular vein. B: intraoperative image of vagal schwannoma showing stretched out vagus nerve. Yellow arrow showing carotid artery; green arrow showing hypoglossal nerve and blue arrow showing internal jugular vein.

DISCUSSION

Schwannomas are rare tumours of neurogenic origin of which about 30-40% occur in the head and neck region.³ Parapharyngeal space schwannomas are next only to vestibular schwannoma in the head and neck region.

They are usually asymptomatic and presents as a slow growing lateral neck swelling that can be palpated along the sternomastoid muscle. In our series of cases all the 5 patients presented as lateral neck swelling. Clinical diagnosis is difficult because of the rare occurrence and also because most of them do not present with neurological deficit. Often the clinician has a differential diagnosis of metastatic cervical lymphadenopathy, lymphoma, branchial cleft cyst apart from paragangliomas of the parapharyngeal space.⁴

Amongst the symptomatic patients, the most common symptom is hoarseness. Occasionally patient may give a history of paroxysmal cough on pressing the mass, as was seen in one of our patient with vagal schwannoma, which is unique to vagal schwannoma.⁵⁻⁷ Another patient presented with giddiness which was because of intracranial component of hypoglossal schwannoma compressing on the brainstem.

Schwannomas arising from spinal accessory nerve are uncommon tumours which may involve the cisternal, foraminal, and extracranial (spinal or intrasternomastoid) segments of the spinal accessory nerve.⁸ Schwannomas of extracranial segment of the spinal accessory nerve represent rarer forms of tumour.⁹ Our series reports a case of schwannoma of extracranial or cervical segment of spinal accessory nerve which was clinically diagnoses as carcinoma of unknown primary origin. Final diagnosis

was based on intraoperative finding and histopathological report.

MRI plays a very important role pre-operatively in the diagnosis and determining the extent of the lesion. The MRI appearance of a well circumscribed non-enhancing mass should lead to the clinical suspicion of a schwannoma. Furukawa et al had reported in their paper on how to differentiate between schwannoma of the vagus nerve and cervical sympathetic chain.¹⁰ The vagal schwannomas, in fact, displace the internal jugular vein laterally and the carotid artery medially, whereas schwannomas from the cervical sympathetic chain displace both the carotid artery and jugular vein without separating them.¹⁰⁻¹⁴ We had one case of cervical clinical sympathetic chain schwannoma which was diagnosed as vagal nerve schwannoma based on clinical and radiological imaging. However intraoperatively it was seen arising from the sympathetic chain and histopathological report confirmed the diagnosis of schwannoma.

The treatment of these tumours is complete surgical excision. Intraoperative these tumours appear as yellowish-white and well circumscribed masses arising from the nerve of origin and at times the nerve is stretched out and lying on the surface of the tumour. Dissecting the tumour from the nerve and preserving the neural pathway of the nerve should be primary aim of surgery. However at times it is very difficult to do so and the nerve has to be sacrificed and an end to end anastomosis may be performed if possible, especially in vagal nerve schwannoma.⁵

As an alternative to complete surgical excision, patients can be offered stereotactic radiosurgery for both newly diagnosed and residual tumour. Pollock et al in their study concluded that although the reported number of patients having radiosurgery for nonvestibular schwannomas is limited, radiosurgery appears to have less treatment associated morbidity for non-vestibular schwannomas, especially for the schwannomas involving the lower cranial nerves.¹⁵

Although the reported incidence of pre-operative vocal cord palsy is about 10-20 % in cases of vagal schwannoma, hoarseness is almost always present following surgery.⁵ Hence, vocal cord assessment is a must prior to surgery in all neck swellings. Because of the high incidence of associated morbidity and the benign nature of the disease, patient needs to be informed about the possible complications and an option of conservative approach may be given specially in elderly patients. Our entire patients were young adults and opted for surgical excision of the tumour. Only 2 out (40%) of the 5 patients did not have any postoperative cranial nerve deficit. One of the patients had multiple postoperative cranial nerve deficits because of the large size of tumour with both intracranial and cervical component which was removed

in 2 stages first by the neurosurgeon and in second stage by the head and neck surgeon.

CONCLUSIONS

The aim of discussion this case series was to highlight the mode of presentation of schwannomas of parapharyngeal region. At times these lesions can be very extensive with intracranial extension and may require to be removed as a staged procedure involving the Neurosurgeon and Head & Neck surgeon. The surgery carries the risk of cranial nerve palsy and patients should be informed about it preoperatively.

Funding: No funding sources

Conflict of interest: None declared

Ethical approval: The study was approved by the Institutional Ethics Committee

REFERENCES

1. Batsakis JG, Sneige N. Parapharyngeal and retropharyngeal space diseases. *Ann Otol Rhinol Laryngol.* 1986;21:173.
2. Yumoto E, Nakamura K, Mori T, Yanaghiara N. Parapharyngeal vagal neurilemmomas extending to the jugular foramen. *J Laryngol Otol.* 1996;110:485-9.
3. Chang SC, Schi YM. Neurilemmoma of the vagus nerve: a case report and brief literature review. *Laryngoscope.* 1984;94:946-9.
4. Colreavy MP, Lacy PD, Hughes J, Bouchier-Hayes D, Brennan P, O'Dwyer AJ, et al. Head and neck schwannomas – a 10-year review. *J Laryngol Otol.* 2000;114:119-24.
5. Ford LC, Cruz RM, Rumore GJ, Klein J. Cervical cystic schwannoma of the vagus nerve: diagnostic and surgical challenge. *J Otolaryngol.* 2003;32:61-3.
6. Fujino K, Shinohara K, Aoki M, Hashimoto K, Omori K. Intracapsular enucleation of vagus nerve-originated tumours for preservation of neural function. *Otolaryngol Head Neck Surg.* 2000;123:334-6.
7. Gilmer-Hill HS, Kline DG. Neurogenic tumours of the cervical vagus nerve: report of four cases and review of the literature. *Neurosurgery.* 2000;46:1498-503.
8. Agarwal A, Rao KS, Makannavar JH, Shetty L, Raveendra VM. Intrasternomastoid spinal accessory nerve schwannoma: Clinical and radiological correlation. *Neurol India.* 2005;53:347-8.
9. Iwasaki K, Kondo A. Accessory nerve neurinoma manifesting with typical jugular foramen syndrome. *Neurosurgery.* 1991;29:455-9.
10. Furukawa M, Furukawa MK, Katoh K, Tsukuda M. Differentiation between schwannoma of the vagus nerve and schwannoma of the cervical sympathetic chain by imaging diagnosis. *Laryngoscope.* 1996;106:1548-52.
11. Saito DM, Glastonbury CM, El-Sayed I, Eisele DW. Para-pharyngeal space schwannomas. Preoperative imaging determination of the nerve of origin. *Arch Otolaryngol Head Neck Surg.* 2007;133:662-7.
12. Green JD Jr, Olsen KD, De Santo LW, Scheithauer BW. Neoplasm of the vagus nerve. *Laryngoscope.* 1988;98:648-54.
13. Leu YS, Chang KC. Extracranial head and neck schwannomas: A review of 8 years experience. *Acta Otolaryngol.* 2002;122:435-7.
14. Park CS, Suh KW, Kim CK. Neurilemmomas of the cervical vagus nerve. *Head Neck.* 1991;15:439-41.
15. Pollock BE, Foote RL, Stafford SL. Stereotactic radiosurgery: the preferred management for patients with nonvestibular schwannomas? *International Journal of Radiation Oncology Biology Physics.* 2002;52(4):1002-07.

Cite this article as: Singh I, Goyal S, Gupta V, Kumar M, Singh A. Parapharyngeal space schwannomas: our experience and review of literature. *Int J Otorhinolaryngol Head Neck Surg* 2017;3:385-9.