

Original Research Article

Central nervous system manifestations of mucormycosis

Ishita A. Shah*, Niral R. Modi

Department of ENT, G. G. Hospital, Jamnagar, Gujarat, India

Received: 31 October 2021

Revised: 05 December 2021

Accepted: 06 December 2021

***Correspondence:**

Dr. Ishita A. Shah,

E-mail: shah031994@gmail.com

Copyright:© the author(s), publisher and licensee Medip Academy. This is an open-access article distributed under the terms of the Creative Commons Attribution Non-Commercial License, which permits unrestricted non-commercial use, distribution, and reproduction in any medium, provided the original work is properly cited.

ABSTRACT

Background: There has been an unprecedented increase in the number of mucormycosis cases post the second wave of COVID-19 in India, with a variety of clinical manifestations. The central nervous system manifestations have proven to be especially fatal, hence these require special attention. Aims and objectives of current investigation was to study the epidemiology, clinical features, risk factors, diagnostic modalities, management and complications of CNS manifestations of mucormycosis.

Methods: This is a retrospective study, conducted on the mucormycosis patients admitted in G.G. hospital Jamnagar. Patients with clinically and radiologically evident central nervous system involvement were included in the study. The records of the patients were followed for 3 months post the diagnosis. 47 patients were included in the study.

Results: The mean age of the patients was 51 years. 72.34% of patients were males, and 27.65%, were females. The most common clinical feature was headache 100% followed by fever 55%. Most of the patients (97.87%) had history of COVID 19 or had active infection. 63.96% had diabetes Mellitus. The most common radiological finding was cavernous sinus thrombosis (32.60%), 72.34% underwent surgical debridement, and all the patients were administered Amphotericin B. The outcome improved significantly with surgical debridement, with recovery seen in 51.06% patients.

Conclusions: There has been a steep rise in the cases of mucormycosis following the COVID-19 pandemic. It is an extremely virulent infection which spreads rapidly, often causing the involvement of the central nervous system. However, early diagnosis and intervention have been found to alter the prognosis significantly.

Keywords: Mucormycosis, Amphotericin B, Central nervous system.

INTRODUCTION

The second wave of COVID-19 saw an exponential surge in the cases of mucormycosis in India. The state of Gujarat reported the maximum number of cases.¹ Until recently the exact incidence of mucormycosis is not known, as it is an extremely uncommon disease and does not require reporting.² It is estimated to be as low as 0.005 to 1.7 per million population, globally.³ Hence, mucormycosis remains an under investigated disease and poses a dilemma from a diagnostic and therapeutic point of view. This is even more applicable for the Central nervous system manifestations of mucormycosis.

However, the substantial rise in the cases post COVID-19 provides a rare opportunity for further insight into the disease. The organisms causing mucormycosis belong to the group of fungi called mucormycetes, which are ubiquitous in nature. The inhalation of the spores of these fungi is usually the mode of infection.

In rhino-cerebro-orbital mucormycosis the lateral wall of the nasal cavity is the most common site of involvement, followed by nasal septum. From here it rapidly involves the para-nasal sinuses, palate, and the roof of nose. From the sphenopalatine foramen it reaches the pterygopalatine fossa, from here via the foramen rotundum and vidian

canal to the middle cranial fossa.⁴ From the sphenoid sinus the infection spreads to the cavernous sinus and orbital apex. The orbit is also involved by direct spread from the para-nasal sinuses. The anterior cranial fossa involvement is seen via the frontal sinus. The rapidity of the spread of infection is due to the characteristic angio-invasion by the fungi. This is a prospective study of the mucormycosis patients admitted in a tertiary care centre in Jamnagar following the second wave of COVID-19.

METHODS

This is an retrospective observational study of patients, admitted in the mucormycosis ward in G. G. hospital Jamnagar with clinically or radiologically evident central nervous system involvement, were included in the study. The study period was from April to July 2021.

Inclusion criteria

Patients admitted in the mucormycosis ward with clinical or radiological features suggestive of central nervous system involvement. Patients of all ages were included in the study.

Exclusion criteria

Patients admitted in the mucormycosis ward without clinical or radiological findings suggestive of CNS involvement and patients not willing for participation in the study were excluded from the study.

Procedure

Of the total 257 patients diagnosed with mucormycosis, 47 were included in the study. All of these patients had either clinically or radiologically evident involvement of the central nervous system. Written informed consent was taken from all the included patients. In this study we evaluated various predisposing factors, clinical features, investigations and diagnosis and management protocols for patients with mucormycosis with central nervous system involvement.

History and clinical examination

A detailed history of the clinical features, co-morbidities and COVID-19 infection and treatment was taken for all patients. The presenting symptoms were most commonly nasal discharge often bloody, facial pain and swelling, loosening of teeth, visual impairment, limitation of eye movement and palatal ulcers. Complaints of severe headache, irritability, drowsiness, nausea, vomiting, neck stiffness are early indicators of intracranial involvement. Features of irritability, drowsiness, altered sensorium, hemiplegia or hemiparesis, neck stiffness indicates intracranial extension and poor prognosis. The clinical examination shows crusting and necrosis on anterior rhinoscopy, palatal necrosis, ophthalmoplegia, loss of light perception, cellulitis, and necrosis of the overlying

skin. Neck rigidity, hemiplegia or hemiparesis, focal neural deficits, papilledema are seen in intracranial extension.

Investigations and diagnosis

Nasal endoscopy: most of the patients were diagnosed on clinical grounds, with rigid nasal endoscopy proving to be an invaluable tool. Crusting, discharge and frank necrosis can be encountered on nasal endoscopy. The typical finding of blackening over the parts of the lateral nasal wall and septum is a characteristic of mucormycosis. However, in early cases only discharge may be present without frank necrosis. KOH mount and histopathology: Samples for KOH mount were collected from suspicious lesions, usually with endoscopic guidance. The 2 separate samples are sent in normal saline and 10% formalin, for KOH mount and histopathology respectively. The findings of broad, aseptate or sparsely septate hyphae with wide angle branching pattern, is diagnostic.⁵ Radiological investigations were required for the evaluation of the extent of the disease and for identifying diseased areas not visualised on endoscopy. MRI was performed for all the patients who did not have oxygen requirement. Scans of brain, orbit and paranasal sinuses were obtained, in plain and with gadolinium contrast. Computed tomography shows minimally enhancing hypo-intense soft tissue thickening of the involved area. MRI shows soft tissue thickening and heterogeneous post contrast enhancement on T2 weighted images. Commonly seen findings are cavernous sinus thrombosis, intracranial infarcts or thrombosis, intracranial abscess, subdural and epidural abscess, haemorrhages, meningeal enhancement.

Treatment

A combination of medical and surgical management was the patients whenever possible. Injection Amphotericin B (liposomal form) was started empirically on clinical grounds. The liposomal form was preferred as it has better tissue perfusion and less renal toxicity as compared to the conventional deoxycholate form. The dose administered was 5 mg/kg per day, as this dose was well tolerated by most of the patients and had a good efficacy. For the surgical management the main objective is to reduce the fungal load and to remove the devitalised tissue so that the perfusion of the antifungal agents is improved. A variety of methods have been described which can be widely divided into open approaches via lateral rhinotomy by Weber-Fergusson incision, Caldwell Luc's approach, Denker's procedure etc and endoscopic approaches like endoscopic sinus surgery and modified Decker's procedure. Intracranial abscesses may require craniotomy and abscess drainage. Modified Denker's procedure was the preferred method for debridement at our institute. The reason for this is two-fold, first it provides excellent access to the retromaxillary, pterygopalatine and infratemporal regions. The other being the better evaluation, after surgery for any recurrent

disease. CSF leaks which were identified intraoperatively were repaired by using fat grafts from the ear lobes, tissue glue and surgical. This was then covered with antibiotic soaked gel foam. The nasal cavities were packed with antibiotic soaked Merocel. Nasal packing was removed on post op day 2. Alkaline nasal douching and betadine douching was started for all patients thrice a day. Nasal packing for patients with CSF leaks was removed on post on day 4 and douching was withheld. Orbital exenteration, evisceration and partial maxillectomy was carried out in the relevant cases.

RESULTS

The mean age of the patients was 51 years, (28-93 years). 34 (72.34%) patients were males, and 13 (27.65%) females. The most common was headache (100%), followed by fever (55.3%), ophthalmoplegia (29.78%), drowsiness (19.14%), irritability (17.02%), nausea and vomiting (14.89%), photophobia (14.89%), neck rigidity (11.76%), and hemiplegia (11.76%). A majority of the patients had history of COVID-19 infection or had active COVID-19 infection (97.87%). Similarly, most of the patients had a history of diabetes or were recently diagnosed case of diabetes (65.96%), and had received systemic steroids (55.31%).

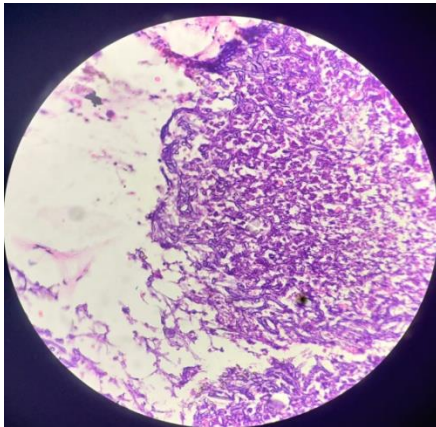


Figure 1: Hematoxylin and eosin staining showing broad aseptate hyphae.

Of the total only 55.53% patients were KOH mount positive, while all the rest were negative, all the patients tested positive on histopathology (100%). Of the total patients 45 had radiological findings suggestive of intracranial involvement. The patients with isolated radiological features had a better clinical prognosis. The most common finding was cavernous sinus thrombosis (32.60%), pachymeningeal enhancement (30.43%), infarcts and haemorrhage (19.5%) and brain abscess (4.25%).

Management

Total 35 of the 47 patients (72.34%) were operated for debridement under general anaesthesia. Modified

Denker's procedure was preferred. Out of these 24 (51.06%) patients were discharged, after completing a course of 28 days of amphotericin B. 4 (8.51%) patients expired postoperatively from mucormycosis related complications and 2 (4.26%) patients from COVID 19 related complications.

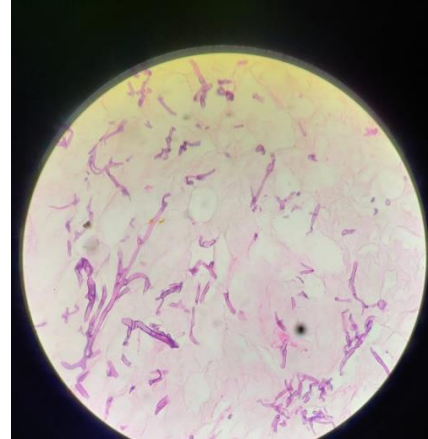


Figure 2: Histopathology specimen showing broad aseptate hyphae.

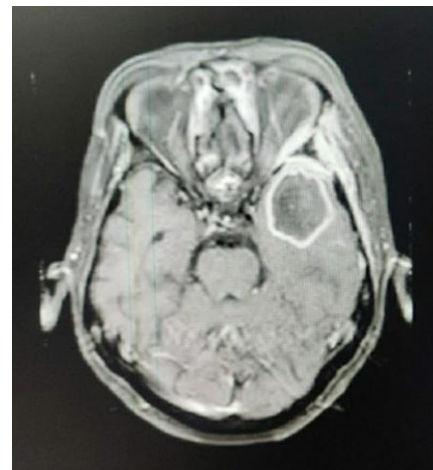


Figure 3: MRI showing temporal lobe abscess.

Complications

Total 5 patients developed CSF leaks. 4 of which were repaired intraoperatively. 1 patient was diagnosed post operatively and managed conservatively. Periorbital edema was the most common post op complication seen in 12.76% patients and was managed conservatively.

Outcome

Total 28 patients 59.57% patients were discharged and showed no recurrence until 3 weeks of follow up. Total 15 patients expired due to COVID-19 and mucormycosis complications, 2 (4.26%) of whom were not operated. 4 (8.51%) patients were referred to higher centre for neurosurgical management.

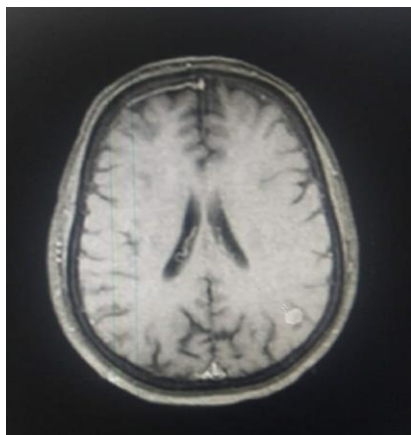


Figure 4: MRI showing pachymeningeal enhancement.

DISCUSSION

The incidence of mucormycosis has increased exponentially following the COVID-19 pandemic. Of the total patients 1/5 had some kind of CNS manifestations. The male population was affected predominantly 72.34%. The mean age affected was 51 years, with 28 years being the youngest and 93 the oldest. Headache was the most common clinical feature seen in all 47 patients. This was followed by cranial nerve involvement, most often CN III, IV, VI leading to ophthalmoplegia, diplopia and ptosis. This was observed in 15 patients. Meningitis and hemiparesis were the next most common features, seen in 6 patients each. The pathophysiology for meningitis is supposed to be via vascular invasion which can cause diffuse vasculitis or direct fungal invasion of the meninges.⁶ The vascular invasion by the fungal hyphae also causes thrombosis leading to ischemia and infarction of the brain. Diffuse vasculitis predisposes to weakening of the vessel wall, which can in turn cause intracranial aneurysms and haemorrhage.^{6,7} Multiple unilateral cranial nerve palsies involving CN II, III, IV, V, VI without involvement of sensory or motor system was seen in 14 patients. This occurs because of direct infiltration of the skull base by the fungus, although certain post-mortem studies have found extensive dural involvement even with intact skull base.^{8,9}

Clinical and radiological features of CNS involvement warrant surgical debridement along with injectable amphotericin. It has been observed that injectable amphotericin alone does not improve the prognosis of the patient, this can be attributed tissue necrosis due to fungal angioinvasion. Therefore, surgical debridement is mandatory to improve the tissue perfusion of amphotericin. It has also been observed that infected bone is more resistant to antifungal therapy, as compared to soft tissue.¹⁰ MRI has a higher sensitivity for diagnosing CNS involvement, and is the imaging modality of choice used in our centre. Certain centres have established a protocol of debriding the areas which show low gadolinium contrast enhancement on MRI¹⁰, as

these areas are considered to be unviable with poor antifungal perfusion. From the management stand-point, medical management alone is not sufficient, early and aggressive surgical debridement is essential, as evidenced by the higher mortality rate in the un-operated patients.¹¹ The CSF leaks occurred following the resection of the diseased tissue which had already invaded the intervening bone, leaving it fragile. Further injury by surgical manipulation led to CSF leaks.¹¹ However, it can be argued that radical removal of the disease even at the cost of a CSF leak gives a better outcome, as opposed to leaving the disease behind for the fear of a CSF leak.

The main associated factors appear to be COVID-19 infection, diabetes mellitus and systemic steroid use, however, a causal relationship is yet to be established. A study by Mehta et al concluded that immune dysregulation in COVID-19 is associated with increased number of secondary infections, which is further augmented by widespread use of steroids, monoclonal antibodies, and broad-spectrum antibiotics.¹² Seasonal variations have also been observed by some authors with a rise in the incidence during summer.¹³

Limitations

Limitations of current study were the patients could not be followed up after 3 months from diagnosis. 4 patients had to be referred to higher centre for further neurosurgical intervention, due to unavailability of neurosurgeons in our institute.

CONCLUSION

Mucormycosis is an extremely virulent disease which has a complicated management protocol. COVID-19 infection has been implicated in the exponential rise in mucormycosis. Associated diabetes and systemic steroids make the patients further susceptible to this opportunistic infection. Also, a significant number of patients had clinical or radiological features of central nervous system involvement. MRI is the most definitive radiological investigation for diagnosis and follow up. Neurosurgical intervention was required in only 4 patients, who had to be referred to a higher centre, the rest were managed endoscopically by ENT surgeon. However early diagnosis and intervention improve the prognosis greatly. Special emphasis needs to be placed on early surgical debridement.

Funding: No funding sources

Conflict of interest: None declared

Ethical approval: The study was approved by the Institutional Ethics Committee

REFERENCES

1. Raut A, Huy NT. Rising incidence of mucormycosis in patients with COVID-19: another challenge for

- India amidst the second wave? *Lancet Respir Med.* 2021;9(8):e77.
2. Prakash H, Chakrabarti A. Global epidemiology of mucormycosis. *J Fungi.* 2019;5(1):26.
 3. Hosseini SM, Borghei P. Rhinocerebral mucormycosis: pathways of spread. *Eur Arch Otorhinolaryngol.* 2005;262(11):932-8.
 4. Bala K, Chander J, Handa U, Punia RS, Attri AK. A prospective study of mucormycosis in north India: experience from a tertiary care hospital. *Med Mycol.* 2015;53(3):248-57.
 5. Ho KL. Acute subdural hematoma and intracerebral hemorrhage. Rare complications of rhinocerebral mucormycosis. *Arch Otolaryngol.* 1979;105(5):279-81.
 6. Sasannejad P, Ghabeli-Juibary A, Aminzadeh S, Olfati N. Cerebellar infarction and aneurysmal subarachnoid hemorrhage: An unusual presentation and rare complications of rhinocerebral mucormycosis. *Iran J Neurol.* 2015;14(4):222-4.
 7. Mutsukura K, Tsuboi Y, Imamura A, Fujiki F, Yamada T. Garcin syndrome in a patient with rhinocerebral mucormycosis. *No To Shinkei.* 2004; 56(3):231-5.
 8. Nam SH, Chung YS, Choi YJ, Lee JH, Kim JH. Treatment outcomes in acute invasive fungal rhinosinusitis extending to the extrasinonasal area. *Sci Rep.* 2020;10(1):3688.
 9. Ramadorai A, Ravi P, Narayanan V. Rhinocerebral Mucormycosis: A Prospective Analysis of an Effective Treatment Protocol. *Ann Maxillofac Surg.* 2019;9(1):192-6.
 10. Arora K, Mehta A, Virk RS, Saini M. Cerebrospinal fluid leak from lateral orbit during exenteration for mucormycosis. *BMJ Case Rep.* 2020;13(9):e237575.
 11. Mehta S, Pandey A. Rhino-orbital mucormycosis associated with COVID-19. *Cureus.* 2020;12(9): e10726.
 12. El-Herte RI, Baban TA, Kanj SS. Mucormycosis: A review on environmental fungal spores and seasonal variation of human disease. *Adv Infect Dis.* 2012; 2(3):76-81.

Cite this article as: Shah IA, Modi NR. Central nervous system manifestations of mucormycosis. *Int J Otorhinolaryngol Head Neck Surg* 2022;8:42-6.