

## Case Report

# A rare case of co-existing branchial cyst and thyroglossal cyst

Natashya H. Sima\*, Jomy George, Ophelia D'Souza, Poonam K. Saidha

Department of Otorhinolaryngology, St John's Medical College, Koramangala, Bangalore, Karnataka, India

**Received:** 29 September 2021

**Revised:** 02 November 2021

**Accepted:** 03 November 2021

**\*Correspondence:**

Dr. Natashya H Sima,

E-mail: [tashrent@yahoo.co.uk](mailto:tashrent@yahoo.co.uk)

**Copyright:** © the author(s), publisher and licensee Medip Academy. This is an open-access article distributed under the terms of the Creative Commons Attribution Non-Commercial License, which permits unrestricted non-commercial use, distribution, and reproduction in any medium, provided the original work is properly cited.

### ABSTRACT

Thyroglossal duct remnants and branchial arch anomalies are the most common congenital neck masses. These anomalies typically present in childhood or early adulthood as cysts, sinuses or cartilaginous remnants, but may rarely present in late adulthood. Although both thyroglossal duct remnants and branchial cysts may be encountered individually, these anomalies are rarely encountered together in the same individual. We report the third such case of co-existing branchial cyst and thyroglossal cyst occurring in the same individual with review of embryological development of thyroglossal duct cysts and second branchial arch anomalies.

**Keywords:** Branchial cyst, Thyroglossal cyst, Thyroglossal duct anomaly

### INTRODUCTION

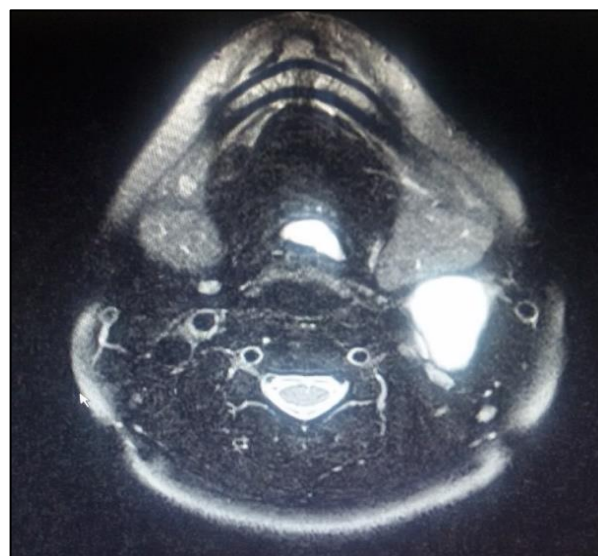
Thyroglossal duct remnants are the most common congenital neck lesions in children followed by branchial cleft anomalies, which may present as cysts, sinuses or cartilaginous remnants, and they represent about 20% of cervical masses.<sup>1</sup> Although these anomalies are not uncommon occurrences individually, a combination of both thyroglossal duct remnants and branchial arch anomalies are rarely encountered. We report the third such case of co-existing thyroglossal and branchial cyst.

### CASE REPORT

A 39 years old female presented to our out-patient department with a swelling in the left side of the neck of 2 months duration. The swelling was insidious in onset, gradually progressing in size and was not associated with pain.

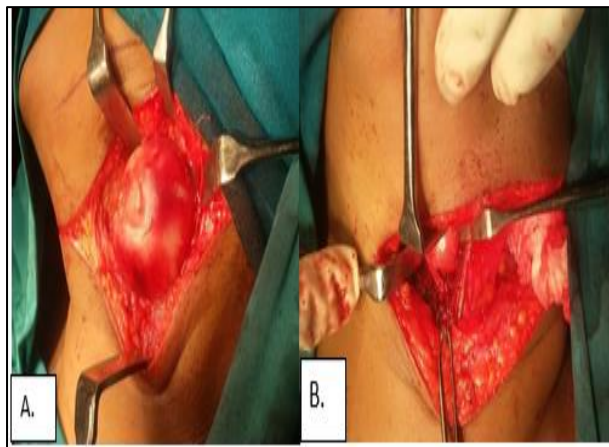
The patient incidentally reported a past medical history of Neurocysticercosis with seizures 8 years earlier at age 31, which was managed conservatively, along with a past

surgical history of right shoulder bone cyst removal at 21 years of age. She is also a known case of Bronchial asthma.

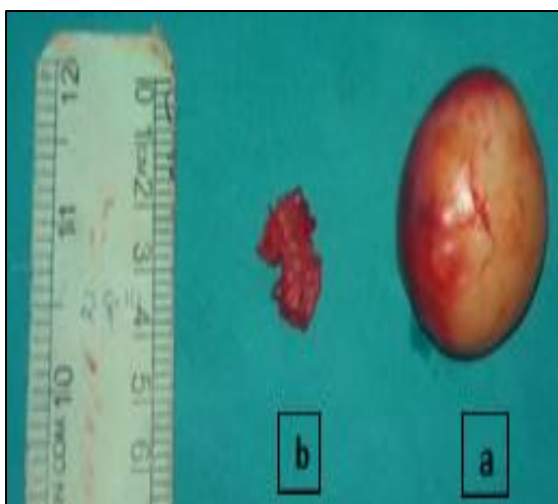

**Figure 1: MRI scan.**

Physical examination revealed two swellings in the neck, the first measuring 5x3 cm, located on the left, at the anterior margin of the left sternocleidomastoid muscle at the junction of the upper 1/3rd and lower 2/3rd. It was ovoid in shape, soft to firm in consistency, non-tender and showed no features of inflammation.



**Figure 2: (A) Bronchial cyst. (B) Thyroglossal cyst.**



**Figure 3: (A) and (B) Specimen.**

The second swelling was located in the midline of the neck just inferior to the hyoid bone. It measured about 1x1 cm, was non-tender, firm in consistency, and moved with deglutition and on protrusion of the tongue. Ultrasound of the neck was done and the findings were confirmed by an MRI scan. Both showed a well-defined cystic lesion measuring 3.7x3.3x4.3 cm on the left side behind the left submandibular gland and inferior to the left parotid gland (Figure 1). It was partially extending into the gap between the internal and external carotid arteries soon after their bifurcation, suggestive of type 3 second branchial cleft cyst. Laterally it was limited by the sternomastoid muscle. The internal jugular vein was compressed postero-medially by the lesion.

Another well-defined separate cystic lesion measuring 12x8 mm was also noted in the midline towards the left side just below the hyoid bone (Figure 1). It was limited anteriorly by the left infra-hyoid muscle in which it was partly embedded and posteriorly by the left thyroid cartilage, suggestive of infra-hyoid thyroglossal cyst with no extension to the tongue base or foramen caecum. There was no connection between the two swellings.

Fine-needle aspiration cytology (FNAC) of the lateral neck swelling showed scattered mature squamous cells and a few anucleate squamous cells with an amorphous background of inflammatory cells, features consistent with branchial cyst with secondary inflammation. The second swelling was not subjected to FNAC.

Based on the above observations, the patient was diagnosed to have a left type 3 second branchial cleft cyst along with a sub-hyoid thyroglossal duct cyst.

The patient was taken up for excision of both lesions under general anaesthesia. A transverse incision was made over the lateral swelling and skin flaps were elevated in the subplatysmal plane. Dissection was followed along the anterior border of sternocleidomastoid (Figure 2a). Blunt dissection was done close to the cyst, and it was removed in toto (Figure 3a). Following this, the same incision was extended medially over the midline cyst. The cyst was delineated along with the tract extending into the middle portion of the hyoid bone (Figure 2b). Sistrunk's surgery was done and the cyst, along with the tract and the middle portion of the hyoid bone was removed (Figure 3b). Both specimens were sent for histopathological examination. Surgical wound was closed in layers and a suction drain was placed. The post operative period was uneventful and the patient was discharged on the third post-operative day following drain removal.

Histopathological examination revealed the following –

Cyst 1 - Showed a cyst lined by stratified squamous epithelium. The lining was ulcerated at places and replaced by foamy histiocytic reaction. There were areas of dense lymphocytic infiltrate with foamy macrophages. All these features were consistent with branchial cyst showing chronic inflammation with focal histiocytic reaction.

Cyst 2 - Cyst wall composed of fibro-collagenous tissue and lined by pseudostratified ciliated columnar epithelium showing an entrapped thyroid follicle containing colloid, consistent with thyroglossal cyst.

## DISCUSSION

Thyroglossal duct cysts are the most common congenital neck masses comprising about 70% of congenital neck masses encountered, followed by branchial cleft anomalies, of which second cleft cysts are the most common.<sup>1-3</sup> Although both anomalies may be encountered

individually, a combination of both anomalies in the same patient is rarely seen.<sup>4</sup>

Thyroglossal duct cysts arise from a tubal remnant of thyroid descent, which begins to develop in the third week of gestation. It arises at the foramen caecum and as it descends in the neck, it penetrates the mesoderm of the tongue and passes anterior to the developing hyoid bone. This duct normally involutes by the eighth to tenth gestational week. Persistence of any portion of the duct may give rise to a thyroglossal duct cyst.<sup>5</sup>

Thyroglossal duct cysts are usually located in the midline (75%). When seen in the paramedian position it occurs more commonly on the left side for reasons unknown.<sup>6</sup> It usually presents as an enlarging painless mass which moves with protrusion of the tongue due to its attachment at the foramen caecum. The cyst may sometimes go unnoticed and can present as a consequence of infection.<sup>7</sup> Excision of the cyst with Sistrunk's operation is the treatment of choice which involves resection of the central portion of the hyoid bone along with the cyst all the way up to its attachment to the foramen caecum.<sup>2</sup>

Second branchial arch anomalies account for about 95% of branchial arch anomalies and may present as cysts, fistulas, sinuses or cartilage remnants. While branchial fistulas are more common in infants and children, branchial cysts are more commonly seen in young adults and older children. Branchial arch anomalies may present bilaterally in about 2.3% of the cases and when present bilaterally are usually familial.<sup>8</sup> Although various theories have been proposed to explain the formation of branchial arch anomalies, the most commonly accepted theory is incomplete obliteration of branchial apparatus, primarily the cleft.<sup>9</sup>

Second branchial arch anomalies may present anywhere along the course of the second branchial tract from the submandibular space to the supraclavicular fossa, and pass between the internal and external carotid arteries to enter the pharynx at the level of the tonsillar fossa.<sup>10</sup> They have been classified into 4 sub-types:

Type I – Most superficial lying along the anterior surface of sternocleidomastoid deep to the platysma, but not in contact with the carotid sheath.

Type II – Most common type where the branchial cleft cyst lies anterior to the sternocleidomastoid muscle, posterior to the submandibular gland, adjacent and lateral to the carotid sheath.

Type III – Extends medially between the bifurcation of the internal and external carotid arteries, lateral to the pharyngeal wall.

Type IV – Lies deep to the carotid sheath within the pharyngeal mucosal space and opens into the pharynx.<sup>5</sup>

Branchial cysts usually present as painless swellings in the lateral aspect of the neck. These swellings may sometimes go unnoticed but when infected may increase in size and present as tender swellings.<sup>11</sup> Although ultrasound is a good modality for diagnosis, MRI is better suited in the assessment of deeper tissue involvement.<sup>1</sup> Occasionally a “beak sign” may be seen on axial CT scan or MRI, which represents a curved rim of tissue pointing medially between the internal and external carotid arteries, and is pathognomonic of Bailey's type 3 cyst.<sup>5</sup> Treatment involves complete surgical excision of the cyst along with its tract.<sup>4</sup>

## CONCLUSION

Although thyroglossal duct cysts and branchial cysts are not an uncommon occurrence in practice, a combination of both anomalies concurrently in the same patient is rarely seen, and only 2 such cases have been reported in literature. We report the third such case of co-existing thyroglossal and branchial cysts, both of developmental origin and both presenting in the fourth decade in this patient. It brings into question whether any event in the embryological or antenatal period can account for the formation of these developmental cysts later in life.

*Funding: No funding sources*

*Conflict of interest: None declared*

*Ethical approval: Not required*

## REFERENCES

1. Adams A, Mankad K, Offiah C, Childs L. Branchial cleft anomalies: a pictorial review of embryological development and spectrum of imaging findings. *Insights Imaging.* 2016;7(1):69-76.
2. Allard RHB. The thyroglossal cyst. *Head Neck Surg.* 1982;5(2):134-46.
3. LaRiviere CA, Waldhausen JHT. Congenital Cervical Cysts, Sinuses, and Fistulae in Pediatric Surgery. *Surg Clin North Am.* 2012;92(3):58-97.
4. R M, I B, N T, S R, R A, M R, et al. A Rare Case Report of a Child Coexistence Thyroglossal Cyst and Second Branchial Cleft Fistulae. *J Case Reports Stud.* 2016;4(1).
5. Koeller KK, Alamo L, Adair CF, Smirniotopoulos JG. From the Archives of the AFIP. *RadioGraphics.* 1999;19(1):121-46.
6. Macdonald DM. Thyroglossal cysts and fistulae. *Int J Oral Surg.* 1974;3(5):342-6.
7. Deane SA, Telander RL. Surgery for thyroglossal duct and branchial cleft anomalies. *Am J Surg.* 1978;136(3):348-53.
8. Clevens RA, Weimert TA. Familial bilateral branchial cleft cysts. *Ear Nose Throat J.* 1995;74(6):419-21.
9. Harnsberger HR, Mancuso AA, Muraki AS, Byrd SE, Dillon WP, Johnson LP, et al. Branchial cleft anomalies and their mimics: computed tomographic evaluation. *Radiology.* 1984;152(3):739-48.

10. Waldhausen JHT. Branchial cleft and arch anomalies in children. *Semin Pediatr Surg.* 2006;15(2):64-9.
11. Bajaj Y, Ifeacho S, Tweedie D, Jephson CG, Albert DM, Cochrane LA, et al. Branchial anomalies in children. *Int J Pediatr Otorhinolaryngol.* 2011;75(8):1020-3.

**Cite this article as:** Sima NH, George J, D'Souza O, Saidha PK. A rare case of co-existing branchial cyst and thyroglossal cyst. *Int J Otorhinolaryngol Head Neck Surg* 2021;7:1953-6.